

# Abdominal Terminology

## Background

In the July 2019 release SNOMED International took the stance that the meaning of the concept identified by the concept id 113345001 should be made more explicit as *Abdominopelvic structure (body structure)* but retain the ‘synonyms’ of *Abdomen* and *Abdominal structure* based on the most common usage. However, feedback has highlighted that users of DICOM used “abdomen” to mean abdomen including the back and excluding the entire false and true pelvic region for cross-sectional imaging such as CT (Computed tomography) and MRI (Magnetic resonance imaging).

The purpose of this document is to explicitly describe and define concepts relating to regional anatomy of the abdomen and pelvis. This work has been stimulated by a SNOMED International initiative to improve the quality of SNOMED CT anatomy using the key resources of FMA (Foundation Model of Anatomy), Gray’s anatomy<sup>1</sup>, Terminologia Anatomica, other medical terminologies, classifications, and literature publications.

The ‘abdomen’ in natural language can be used to refer to, but not limited to, the following concepts:

- *Abdominopelvic cavity*
- *Abdominopelvic cavity excluding the true pelvic cavity (Abdomen proper cavity)*
- *Abdominopelvic cavity and/or content (Intra-abdominopelvic structure)*
- *Intra-abdominopelvic structure excluding intra-pelvic structure of true pelvis*
- *Intra-abdominopelvic structure and/or anterior abdominal wall*
- *Intra-abdominopelvic structure and/or anterior abdominal wall, excluding intra-pelvic structure of true pelvis (Abdomen proper)*
- *Abdominal segment of trunk*
- *Abdominal cross-sectional segment of trunk*

and possibly additional concepts if they are needed for clinical practice:

- *Intra-abdominopelvic structure and/or wall of abdominopelvic cavity*

---

<sup>1</sup> Standing, S. ed., 2015. *Gray's anatomy e-book: The anatomical basis of clinical practice*. Elsevier Health Sciences.

## Trunk Structure

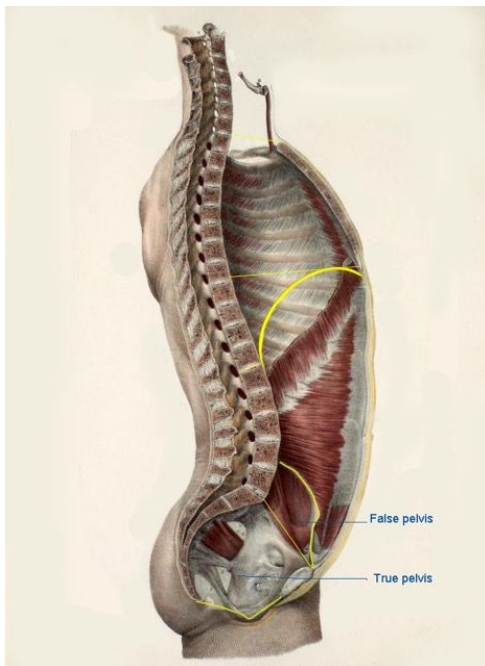
The purpose of this section is to achieve a consensus of the description of the subdivisions of 'trunk structure' and perspectives of the anatomical structures comprising the trunk. It attempts to define clinically relevant walls, cavities, segments and regions of the trunk so that users of SNOMED CT have confidence in the semantics of the concept chosen.

In addition, it relates these concepts to morphological anatomical boundaries and structures in a multiple-hierarchical structure. These concepts can then be employed as values to model disorders and procedures to infer relationships between these clinical concepts.

## Anatomical boundaries and planes of the trunk

The following diagram illustrates a number of recognised anatomical morphological planes and boundaries.

**Figure 1.** Main boundaries and planes of the trunk region



Some key planes can be identified:

- **Thoracic inlet** - this is an artificial boundary, also known as the *superior thoracic aperture*) bounded by T1; the first pair of ribs laterally; and anteriorly the costal cartilage of the first ribs continuous with the superior border of the manubrium and the chest wall;
- **Diaphragm** (thoracic);
- **False pelvis upper border** - is an artificial plane from the symphysis pubis to the superior iliac crests; in front it is incomplete, presenting a wide interval between the anterior borders of the ilia;

- **Superior pelvic aperture** - is an artificial oblique plane passing through the sacral promontory posteriorly and the lineae terminales elsewhere. Each linea terminalis includes the iliac arcuate line, pectineal line (pecten pubis) and pubic crest. It is also known as *pelvic inlet* or *pelvic brim*. This is the plane that separates the *abdomen proper cavity* from the true or minor pelvis; and
- **Inferior aperture of true pelvis** - The boundaries of this trapezoidal shaped inferior aperture of true (minor) pelvis are formed by the symphysis pubis in front, the coccyx behind, on each side the inferior pubic ramus and the ramus of the ischium, the ischial tuberosity and the sacrotuberous ligament. An imaginary line drawn transversely in front of the ischial tuberosities divides the region into two triangular parts. The posterior part contains the anus and is known as 'the anal triangle', while the anterior part is the 'urogenital triangle' containing the external urogenital organs. The pelvic floor spans the inferior opening.<sup>2</sup>

## Cavity of trunk

The planes above form significant boundaries of the following anatomical volumes of the trunk whose cavity can be divided into the:

- **Thoracic cavity**: bounded by the diaphragm inferiorly; superiorly the thoracic inlet, (or superior thoracic aperture); and bounded but excluding the chest wall [shown in orange in Figure 2]; and
- **Abdominopelvic cavity**: bounded superiorly by, but excluding, the diaphragm; the pelvic diaphragm, inferiorly; and wall of abdominopelvic cavity.
  - **False (major or greater) pelvic cavity** - is the expanded portion of the bony pelvis above and in front of the superior pelvic aperture (or pelvic brim)<sup>3</sup>. It lies between the *false pelvis upper border* and the *superior pelvic aperture* and is bounded on either side by the ilium; in front it is incomplete, presenting a wide interval between the anterior borders of the ilia; behind is a deep notch on either side between the ilium and the base of the sacrum. It supports the intestines, and transmits part of their weight to the anterior wall of the abdomen.<sup>4</sup>; and
  - **True (minor or lesser) pelvic cavity** - is a bowl-shaped volume bounded superiorly by the *superior pelvic aperture* and inferiorly by the *inferior aperture of true pelvis* and *pelvic diaphragm*.
  - **Peritoneal space**: lies between the parietal peritoneum (the peritoneum lines the abdominal wall) and visceral peritoneum (the peritoneum that surrounds the internal organs)
  - **Extraperitoneal space**: lies outside the peritoneum and can be divided into:
    - Retroperitoneal space: situated posteriorly to the peritoneum
    - Preperitoneal space: situated anteriorly to the peritoneum

---

<sup>2</sup> Key, J., 2010. *Back Pain-A Movement Problem E-Book: A clinical approach incorporating relevant research and practice*. Elsevier Health Sciences.

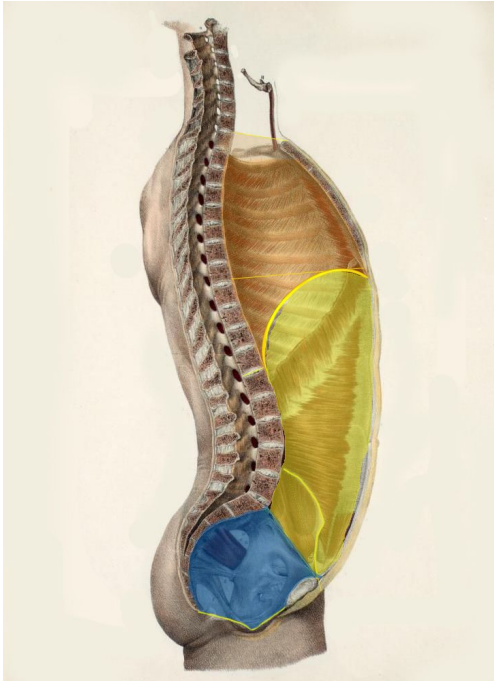
<sup>3</sup> Chung, K.W. and Chung, H.M., 2008. *Gross anatomy*. Lippincott Williams & Wilkins.

<sup>4</sup> [https://theodora.com/anatomy/the\\_pelvis.html](https://theodora.com/anatomy/the_pelvis.html)

Thus a key morphological plane with respect to the abdominopelvic cavity is the **superior pelvic aperture** which divides this volume into:

- *True pelvic cavity* [shown in blue in Figure 2 below]; and
- *Abdomen proper cavity* - more explicitly the *Abdominopelvic cavity excluding the true pelvic cavity* [shown in yellow in Figure 2 below].

**Figure 2.** Cavities of the trunk



## Wall of trunk

From the description above it is apparent that the boundaries of an anatomical volume can be virtual e.g. thoracic inlet, or structural e.g. thoracic diaphragm: and when an anatomical structure forms the boundary this is often described as a 'wall'.

The FMA defines the *body wall*, as a 'Subdivision of trunk that consists of those organs that separate the body cavity from the body's exterior; together with the body cavity and its contents, the body wall constitutes the trunk (one of the principal body parts).'

The FMA also considers the **wall** as a constitutional part of the 'compartment' (along with the space and content): The approach in SNOMED CT has been subtly different by using the 'compartment' to describe the space and content only (but not the wall). In order to avoid confusion it is proposed to use the term 'intra' to describe the combination of space and contents, as illustrated in the following amended hierarchy in the SNOMED CT anatomy:

Structure of X  
  Wall of X  
  Intra-X structure  
    Space of X  
    Content of X

The constituent layers of the trunk wall vary between and within different cavities: The inner wall boundary is consistent but the extent to which more superficial layers are included as 'part of the wall' is dependent on the area considered. A general rule derived from the FMA approach is where the trunk wall is entirely comprised of a skeletal framework e.g. rib cage, this wall structure excludes the overlying integument. To consider this aspect further the walls of the three main volumes are considered below.

## Wall of thorax (Thoracic wall)

The *Wall of thorax* is defined in FMA as a 'Heterogeneous cluster which surrounds the thoracic cavity and its content; and which includes the ribcage, muscle group of thoracic wall and costal pleura': thus the *thoracic wall* is entirely comprised of a skeletal frame, and excludes the overlying integument.

However, the **chest wall** 'includes all the structures from the skin to [and including] the costal pleura (FMA) i.e. the wall of thorax, the superficial chest wall, lateral chest wall and anterior chest wall, which includes the integument.

## Wall of abdomen

The wall of the *abdominopelvic cavity* is complicated by having two regional parts: the *wall of abdomen proper cavity*, and the *wall of pelvis*. In addition the *posterior abdominal wall* is particularly contentious and Gray's anatomy (2015: 1083) states that "the posterior abdominal wall does not have an agreed uniform definition": Most descriptions of the *posterior abdominal wall* consider the following structures are included:

- Posterior abdominal wall musculature (quadratus lumborum, psoas major and minor)
- Crus of lumbar part of diaphragm
- Lumbar vertebral column
- Posterior part of abdominal peritoneum

But the extent to which structures located more posteriorly (superficial) than the vertebral arches (L1-L5) are encompassed, including the integument, is variable, but in harmony with FMA, Gray's anatomy (2015:1033) includes only the 'five lumbar vertebrae and their intervening intervertebral discs...the muscles of the posterior abdominal wall' i.e. it excludes the back.

The *Anterior abdominal wall* is less contentious and there is widespread agreement that it has the following parts:

- Musculature of anterior abdominal wall
- Anterior part of abdominal peritoneum
- Skin and superficial fascia of anterior part of abdomen

## Wall of pelvis

The *wall of pelvis* is skeletal and comprised of the bones, joints, ligaments of the pelvis and associated muscles (piriformis and obturator internus). It forms part of the wall of *abdominopelvic cavity* and the *pelvic region of trunk*. It is worth noting that the *wall of pelvis* excludes the integument and mons pubis; but these are constituents of the *pelvic segment of trunk*.

## The regions of trunk

These structures are considered below in more detail by suggesting a Fully Specified Name and a text based definition. The concept **term** is shown in **bold** followed by *definitions* in *italics*.

### 1. Cross-sectional and segmental regions of trunk

In diagnostic radiology, the term "abdomen" is usually used in the context of imaging procedures, which are cross-sectional or projectional (transmissive) or emissive. For cross-sectional procedures especially, such as CT (or MRI), a CT of the abdomen is distinguished from a CT of the pelvis (below) or chest (above), and the entire transverse thickness of the body over that longitudinal extent is examined i.e., the radiological "abdomen" is full thickness (segment of trunk, not confined to the front nor the cavity, and including the skin of the front and back). Similarly concepts are also required for *Thoracic cross-sectional segment of trunk* and *Pelvic cross-sectional segment of trunk*.

The 'boundaries' of these regions may not adhere to traditional anatomical borders, partly because the segments are transverse sections, compared to virtual anatomical planes e.g. superior pelvic inlet, which is inclined and curved.

The following section illustrates regional concepts used including those established within radiology. It is critical to reiterate that the 'cross-sectional segments' include all structures between the planes identified i.e. the regions include the skin and subcutaneous tissue and surrounding musculature as well as the cavity wall and contents highlighted in figures 3 and 5.

#### **Abdominal cross-sectional segment of trunk**

*This includes part of the thoracic cavity up to the level of T8/T9; but excludes the true pelvis and false pelvis and a small volume of the lower 'Abdomen proper cavity'; but includes all the skin, subcutaneous tissue and surrounding musculoskeletal structures of the anterior and posterior trunk wall structures within the volume, see figure 3.*

#### **Pelvic cross-sectional segment of trunk**

*This commences inferiorly (below the plane traversing the superior boundary of the iliac crest), and extends to the perineum and includes part but not necessarily the entire external genitalia, see figure 3.*

The true and false pelvic cavity are subsumed by the *Pelvic cross-sectional segment of trunk*, as well as an additional small volume of the lower abdominal cavity; a

volume below the pelvic diaphragm which constitutes part of the perineum and part but not necessarily all of the external genitalia; and all the skin, subcutaneous tissue and surrounding musculoskeletal structures.

### **Abdominopelvic cross-sectional segment**

*This is a combination of the Abdominal and pelvic cross-sectional segments of trunk, see figure 3.*

### **Abdominopelvic segment excluding true pelvic segment of trunk (Abdomen proper segment of trunk)**

*This includes the intra-abdomen proper structure (see later definition) and anterior abdominal wall and the posterior lumbar region, shown in yellow in figure 4.*

It is worth noting that the posterior lumbar region is similar but smaller in volume compared to the *Abdominal cross-sectional segment of trunk*; also the *false pelvic structure* overlaps and is also part of *Pelvic segment of trunk*.

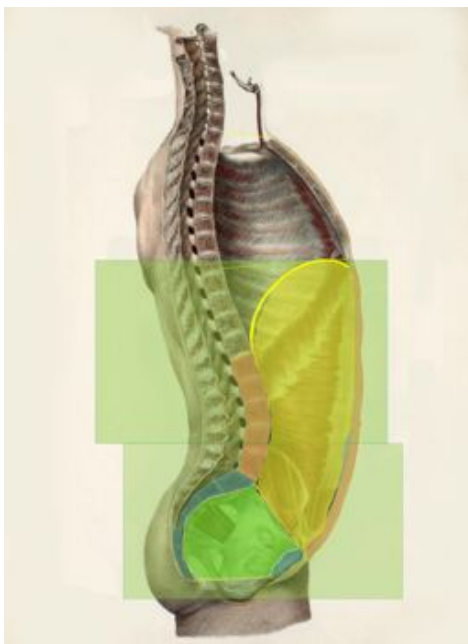
### **Pelvic segment of trunk**

*This includes the pelvic structure, buttock region, perineum and the entire external genitalia, shown in blue in figure 4.*

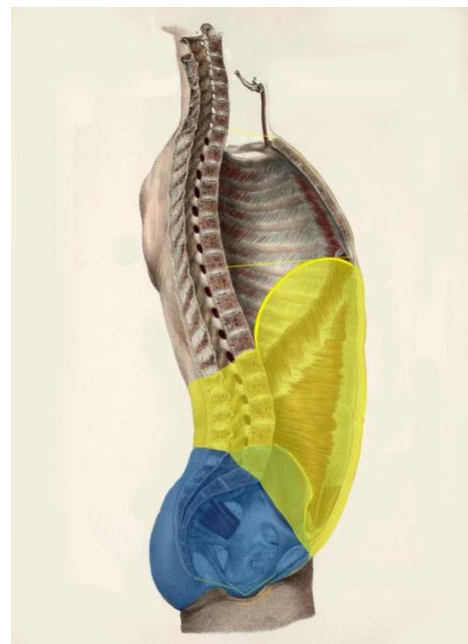
### **Abdominopelvic segment of trunk**

*This is the combination of Abdomen proper segment of trunk and Pelvic segment of trunk, see figure 4.*

**Figure 3.** Pelvic cross-sectional segment of trunk & Abdominal cross-sectional segment of trunk with transverse boundary above iliac crest



**Figure 4.** True pelvic segment of trunk & Abdomen proper segment of trunk with inclined and curved boundary along superior pelvic aperture

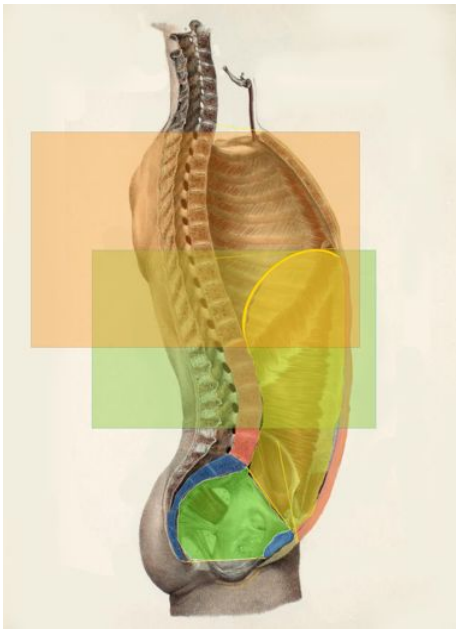


The following diagram illustrates the overlap of the *Thoracic cross-sectional segment of trunk*.

**Thoracic cross-sectional segment of trunk**

*This segment is bounded superiorly thoracic inlet, (upper boundary of T1 vertebra) and extends inferiorly to the lower boundary of T12, see figure 5.*

**Figure 5.** Thoracic cross-sectional segment of trunk & Abdominal cross-sectional segment of trunk with boundary of iliac crest



The figure above illustrates the overlap between the thoracic and abdominal cross-sectional segment of trunk at level of T8/T9 to T12/L1. The *thoracic cross-sectional segment of trunk* subsumes the thoracic cavity and an upper volume of the ‘abdomen proper cavity’ above the plane of T12/L1; and all the skin, subcutaneous tissue and surrounding musculoskeletal structures.

NB the FMA defines the thoracic segment of trunk as being a ‘*Subdivision of trunk which has as its parts the thorax and the back of thorax. The back of thorax has as its constitutional part some complete set of vertebral arches (T1-T12) and anatomical entities located posterior to them; and thorax is defined as a subdivision of front of trunk, each instance of which has as its constitutional part some complete set of thoracic vertebral bodies (T1-T12) and some ribcage*’

**Hierarchy:**

*Thoracic cross-sectional segment of trunk*

*Thoracic segment of trunk (upper trunk)*

*Abdominopelvic cross-sectional segment of trunk*

*Abdominal cross-sectional segment of trunk (Cross-sectional abdomen)*

*Pelvic cross-sectional segment of trunk*

*Abdominopelvic segment of trunk (Lower trunk)*

*Abdominopelvic segment excluding true pelvic segment of trunk (Abdomen proper segment of trunk)*

*Pelvic segment of trunk (Pelvic region of trunk)*



## 2. Abdominopelvic structures

The abdominopelvic structure is difficult to define because “the posterior abdominal wall does not have an agreed uniform definition. It represents the posterior boundary of the abdominal cavity”<sup>5</sup> as outlined above.

### **Abdominopelvic cavity** (see blue and yellow volume, figure 2)

*The cavity is a space bounded, but excluding the:*

- *diaphragm, superiorly;*
- *pelvic diaphragm, inferiorly; and*
- *wall of abdominopelvic cavity anteriorly and posteriorly.*

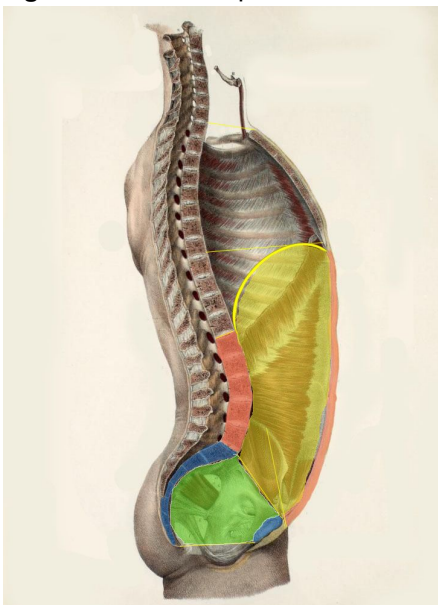
### **Wall of abdominopelvic cavity** (see figure 6 below)

*The wall consists of the:*

- *five lumbar vertebrae and their intervening intervertebral discs;*
- *sacrum and coccyx;*
- *muscles of the posterior abdominal wall (psoas, quadratus lumborum and the crus of the lumbar part of diaphragm);*
- *muscles of the anterior abdominal wall: rectus abdominis (anteriorly) and transversus abdominis, internal oblique and external oblique (anterolaterally) and overlying skin and subcutaneous tissue of anterior and lateral abdominal wall; and*
- *bony walls, joints and ligaments of the entire pelvis and piriformis and obturator internus.*

NB this is a working definition that takes the shallower view of the posterior abdominopelvic wall i.e. it excludes structures more posterior (superficial) than the vertebral arches, as described in Gray’s anatomy (2015:1033).

**Figure 6.** Abdominopelvic wall



<sup>5</sup> Gray’s anatomy, 41 Edition, p.1083

The anterior and posterior walls of the '*abdomen proper cavity*' are illustrated in red; and the wall of '*true pelvic cavity*' in blue, in figure 6, which in combination contribute to the *abdominopelvic wall*.

### **Content of abdominopelvic cavity**

*Anatomical structures entirely located within the abdominopelvic cavity.*

### **Abdominopelvic cavity and/or content structure (Intra-abdominopelvic structure)**

*This consists of the abdominopelvic cavity and the anatomical structures entirely located within i.e contents of abdominopelvic cavity (but excludes the wall).*

### **Intra-abdominopelvic structure and/or anterior abdominal wall (Abdomen)**

*This consists of the abdominopelvic cavity and/or content plus the anterior abdominal wall (figure 7).*

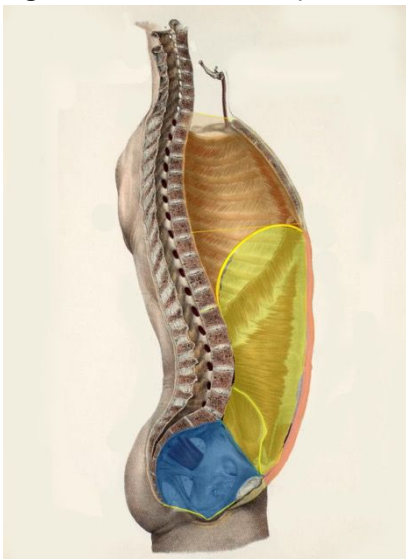
This is a clinical variant of the notion of 'abdomen' and relates to the '*abdominopelvic cavity and contents plus the anterior abdominal wall. but excluding the structures of the back*'; this is because disorders of the lumbar vertebral bodies, intervertebral discs, bony pelvis, and skin/subcutaneous tissue of back would not be considered to be 'abdominal disorders'.

Possibly additional concepts if they are needed for clinical practice:

### **Intra-abdominopelvic structure and/or wall of abdominopelvic cavity**

*This structure consists of the wall and intra-abdominopelvic structure, but it excludes the skin and subcutaneous tissue structure of the back.*

**Figure 7.** Intra-abdominopelvic structure and/or anterior abdominal wall (Abdomen)



**Hierarchy**

*Abdominopelvic segment of trunk*

Wall of abdominopelvic cavity

*Intra-abdominopelvic structure and/or anterior abdominal wall (Abdomen)*

*Abdominopelvic cavity and/or content (Intra-abdominopelvic structure)*

Abdominopelvic cavity

Content of abdominopelvic cavity

**3. Intra-abdominopelvic structure and/or anterior abdominal wall, excluding intra-pelvic structure of true pelvis (Abdomen proper structure)**

**Abdominopelvic cavity excluding the true pelvic cavity (Abdomen proper cavity)**

*This is a space bounded, but excluding the:*

- *diaphragm, superiorly;*
- *superior pelvic aperture, inferiorly; and*
- *wall of abdominopelvic cavity anteriorly and posteriorly and EXCLUDING the wall of the true pelvis*

*NB it is the abdominopelvic cavity excluding the true pelvic cavity (but including the false pelvic cavity) and is shown in yellow in figure 7.*

**Wall of abdominopelvic cavity excluding the wall of true pelvic cavity (Wall of abdomen proper cavity) - (shown in red in Figure 6, above).**

*The boundary consists of:*

- *five lumbar vertebrae and their intervening intervertebral discs;*
- *the muscles of the posterior abdominal wall (psoas, quadratus lumborum and the crus of the lumbar part of diaphragm); Note, this is a working definition for the extent of the posterior wall of the abdomen proper cavity.*
- *the muscles of the anterior abdominal wall: rectus abdominis (anteriorly) and transversus abdominis, internal oblique and external oblique (anterolaterally); and overlying skin and subcutaneous tissue of anterior and lateral abdominal wall*
- *the bony walls of the false pelvis*

In addition, the upper abdominal cavity gains protection from the lower six ribs and their cartilages, even though these structures are technically part of the thoracic wall.

**Content of abdominopelvic cavity excluding content of true pelvic cavity**

*(Content of abdomen proper cavity)*

*Anatomical structures entirely located within the Abdomen proper cavity (but excludes the wall) i.e. contents above the superior pelvic aperture.*

**Intra-abdominopelvic structure excluding intra-pelvic structure of true pelvis**

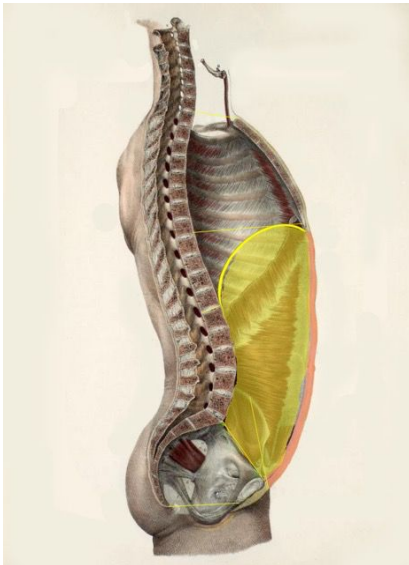
*(Intra-abdomen proper structure)*

*This consists of the abdomen proper cavity and anatomical structures entirely located within (but excludes the wall).*

**Intra-abdominopelvic structure and/or anterior abdominal wall, excluding intra-pelvic structure of true pelvis (Abdomen proper)**

*This is an additional clinical variant of the notion of 'abdomen' and relates to the 'abdomen proper' cavity and content plus the anterior and lateral abdominal wall, but excluding the structures of the back. This is because disorders of the lumbar vertebral bodies and intervertebral discs would not be considered to be 'abdominal disorders' (see figure 8).*

**Figure 8.** Intra-abdominopelvic structure and/or anterior abdominal wall, excluding intra-pelvic structure of true pelvis



**Hierarchy**

*Abdominopelvic segment of trunk*  
     Wall of abdominopelvic cavity  
         Wall of abdomen proper cavity  
     Abdominal structure  
         Abdomen proper structure  
             Intra-abdomen proper structure  
                 Abdomen proper cavity  
                 Content of abdomen proper cavity  
     Intra-abdominopelvic structure  
         Intra-abdomen proper structure  
             Abdomen proper cavity  
             Content of abdomen proper cavity  
     Abdominopelvic cavity  
         Abdomen proper cavity  
         Content of abdominopelvic cavity  
             Content of abdomen proper cavity

NB for clarity the above hierarchy has been constructed using the preferred term rather than the FSNs.

**Intestines and regions**

The *ascending colon*, *transverse colon* and the *descending colon* reside in the 'abdomen proper'. The descending colon descends from the splenic flexure in the left

hypochondrium to the level of the iliac crest, where it curves medially anterior to iliacus to become the sigmoid colon. Historically the distal segment of the descending colon below the iliac crest within the false pelvis was known as the 'iliac colon'.

The junction of the descending colon and the sigmoid colon is at the *superior pelvic aperture* of the lesser pelvis; consequently the *sigmoid colon* technically is within the true (lesser) pelvis but 'on account of its freedom of movement it is liable to be displaced into the abdominal cavity'. The sigmoid colon passes transversely across the front of the sacrum to the right side of the pelvis; it then curves on itself and turns toward the left to reach the middle line at the level of the third piece of the sacrum, where it bends downward and ends in the *rectum*.

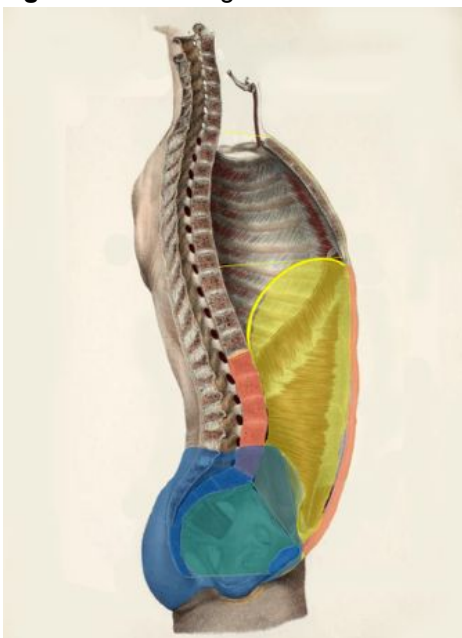
The rectum originates as a continuation of the sigmoid colon at the level of the third sacral vertebra from where it passes downward and extends for about 2.5 cm. in front of, and a little below, the tip of the coccyx, it then bends sharply backward into the anal canal.

Thus the abdominopelvic cavity contains the entire colon, but the 'abdomen proper' includes the descending colon, but excludes the sigmoid colon, which starts at the superior aperture of the true pelvis; the false pelvis (which is a part of the abdomen proper) contains the 'iliac colon' segment of the descending colon; and the true pelvis contains the sigmoid colon, rectum and anal canal.

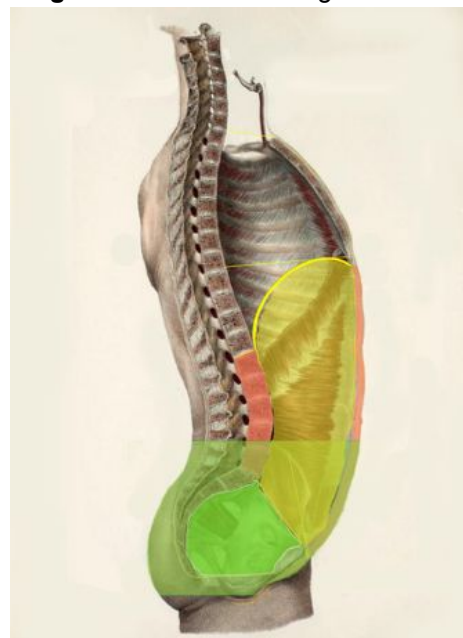
#### 4. Pelvic structures

It is important to appreciate that there are subtle differences between cross-sectional volumes and morphological volumes. For example the figures below compare the anatomical volume represented by the [blue] *Structure of pelvic region of trunk* (concept id: 609617007) in figure 9 and the proposed concept *Pelvic cross-section segment of trunk*, shown in green in figure 10.

**Figure 9.** Pelvic region of trunk



**Figure 10.** Pelvic C/S segment of trunk



For example the pelvic region of trunk excludes the lower abdomen superior to the boundary of the false pelvis; but does include all external genitalia structures.

It is hoped that visualisation of these different volumes of the abdominopelvic cavity and related regions can assist in clarifying their meaning; and if agreed, the relationship between these alternative perspectives and their constituent parts can then be hierarchically expressed. A good illustration of this is the consideration of the colon and the different regional parts (see, Intestines and regions, above).

### **Cavity of false and/or true pelvis**

The pelvic cavity as previously described can be regarded as having two volumes, the minor pelvis (lesser or **true pelvis**) and the major pelvis (greater or **false pelvis**).

The following anatomical morphological concepts can be identified and defined:

#### **True pelvic cavity**

*Body cavity bounded superiorly by the superior pelvic aperture and inferiorly by, but excluding, the pelvic diaphragm and the wall of true pelvis.*

#### **Wall of true pelvis**

*The boundaries consist of:*

- *Antero-inferiorly, it is bounded by pubic bones, their rami and symphysis;*
- *Posteriorly, Sacrum and coccyx;*
- *Laterally on each side, its margins are the smooth quadrangular pelvic aspect of the fused ilium and ischium and the ligaments that interconnect these bones, and the muscles that line their inner surfaces below the superior pelvic aperture*

#### **Cavity and content of true pelvis** (Intra-pelvic structure of true pelvis)

*This consists of the cavity of true pelvis and anatomical structures entirely located within i.e Contents of true pelvic cavity (but excludes the wall).*

#### **Content of true pelvic cavity**

*Anatomical structures entirely located within the cavity of true pelvis – and are gender dependent (see figure 11).*

The list below identifies content of the true pelvic cavity listing those that are common first followed by those that are gender specific. It is worth noting that the table is useful as it identifies structures that are components within the *abdominopelvic cavity* but NOT part of the *abdomen proper cavity*.

#### MALE

Urinary bladder  
Retropubic space  
Presacral space  
Sigmoid colon  
Rectum  
Anal canal  
Pelvic section of ureter

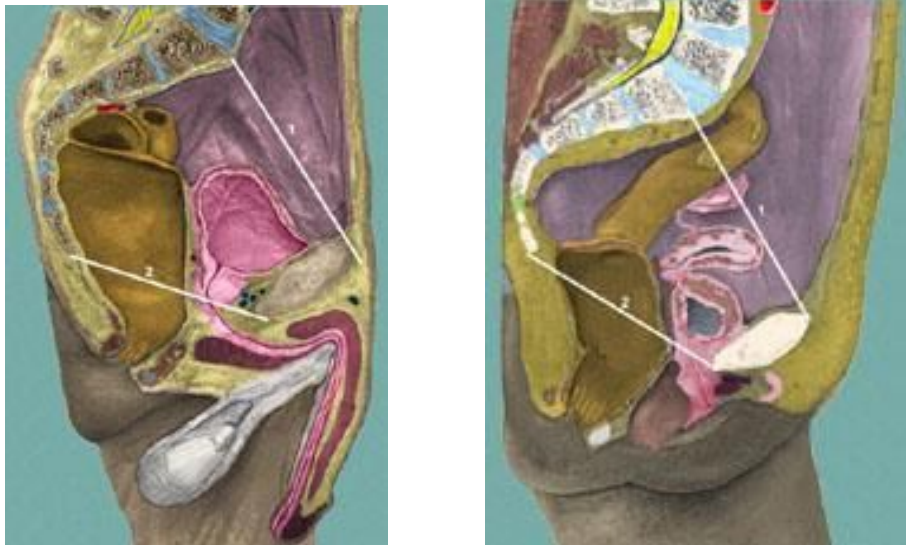
#### FEMALE

Urinary bladder  
Retropubic space  
Presacral space  
Sigmoid colon  
Rectum  
Anal canal  
Pelvic section of ureter

Pubovesical ligament  
 Puboprostatic ligament  
 Seminal vesicles  
 Prostate  
 Male urethra  
 Rectovesical space

Uterus  
 Ovary  
 Fallopian tubes  
 Vagina  
 Female urethra  
 Retrouterine pouch of Douglas

**Figure 11.** Sagittal section of the male and female pelvis (adapted from <http://www.wesnorman.com/pelvis.htm>)

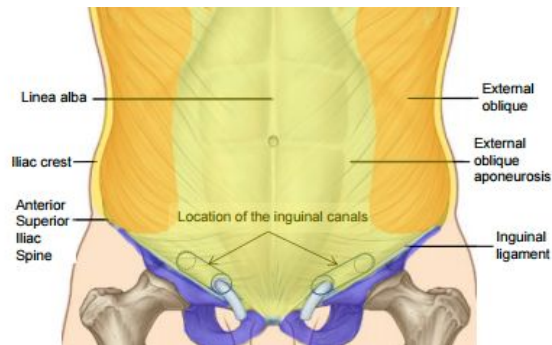


It is worth reiterating here that the pelvic cavity needs specification as to whether one is referring to the true pelvic cavity alone, the false pelvic cavity (rarely used) or the combination of both - the *pelvic structure* would include both, as the wall of the pelvis includes the complete ilia.

In addition the *pelvic structure* includes only the *wall of pelvis* (see figure 6) and the *intra-pelvic structure* (both true and false spaces) which has as its boundary the pelvic diaphragm; compared to the *Pelvic segment of trunk* which also includes the perineum, external genitalia and the skin and subcutaneous tissue of the complete region (figure 9).

Finally it is worth clarifying the margins of the junctions of the abdominopelvic structure on the anterior surface of the trunk: superiorly it is demarcated by the xiphisternal joint and the costal margins; inferiorly by the symphysis pubis, the inguinal folds and the iliac crests; and posteriorly by the lumbar paravertebral musculature of the back. The inguinal ligament is the inferior boundary of anterior abdominal wall. Thus, the *inguinal region* is a part of the lower and lateral abdominal region and lower limb structure (see figure 12).

**Figure 12.** Boundary of the abdominopelvic cavity (yellow) and the inguinal ligament



## 5. Pelvic floor and Perineum

### Pelvic floor

The pelvic floor consists of the ligamentous supports of the cervix, and the pelvic and urogenital diaphragms (Gray's anatomy 2015:2116); Gray's anatomy also states that the pelvic diaphragm consists of the levator ani (pubococcygeus, iliococcygeus and puborectalis); and ischiococcygeus in combination with the two fascial layers (Gray's anatomy 2015:1223) and delineates the lower limit of the true pelvis (Gray's anatomy 2015:1221).

But FMA utilises pelvic floor as a 'synonym' of pelvic diaphragm – so is pelvic diaphragm a narrower concept than pelvic floor or synonymous? This will need more discussion.

### Perineum

The perineum is bounded anteriorly by the pubic symphysis and its arcuate ligament, posteriorly by the coccyx, anterolaterally by the ischiopubic rami and the ischial tuberosities, and posterolaterally by the sacrotuberous ligaments. The deep limit of the perineum is the inferior surface of the pelvic diaphragm, and its superficial limit is the skin that is continuous with that over the medial aspect of the thighs and the lower abdominal wall. An arbitrary line joining the ischial tuberosities (the inter-ischial line) divides the perineum into an anterior urogenital triangle and a posterior anal triangle. (Gray's anatomy 2015:1231).



## **Hierarchy**

*Pelvic segment of trunk (Pelvic region of trunk)*

*Pelvic structure*

*Pelvic cavity*

*False pelvic cavity*

*True pelvic cavity*

*False pelvic structure*

*False pelvic cavity*

*True pelvic structure*

*Intra-pelvic structure of true pelvis*

*True pelvic cavity*

*Content of true pelvic cavity*

*Perineum*

*External genitalia*

## High-level view of the hierarchy

*Thoracic cross-sectional segment of trunk*  
*Thoracic segment of trunk (upper trunk)*

*Abdominopelvic cross-sectional segment of trunk*  
*Abdominal cross-sectional segment of trunk (**Cross-sectional abdomen**)*  
*Pelvic cross-sectional segment of trunk*  
*Pelvic structure*  
*False pelvic structure*  
*True pelvic structure*  
*Perineum (including female external genitalia)*

*Abdominopelvic segment of trunk (Lower trunk)*  
*Intra-abdominopelvic structure and/or anterior abdominal wall Syn:*  
**(abdomen)**  
*Intra-abdominopelvic structure and/or anterior abdominal wall,*  
*excluding intra-pelvic structure of true pelvis<2> (**abdomen proper**)*

*Abdominopelvic segment excluding true pelvic segment of trunk (Abdomen proper segment of trunk)*  
*Intra-abdominopelvic structure and/or anterior abdominal wall,*  
*excluding intra-pelvic structure of true pelvis<2> (**abdomen proper**)*

*Pelvic segment of trunk (Pelvic region of trunk)*  
*Pelvic structure*  
*False pelvic structure*  
*True pelvic structure*  
*Perineum*  
*External genitalia*  
*Skin and/or subcutaneous tissue of pelvis*

## Proposed solution in production

The solution to improve the representation of the 'abdomen' within SNOMED Clinical Terms involves:

1. The creation of a revised hierarchy, including additional content where required;
2. The use of parsimonious polysemy of the term *Abdomen*; and
3. The documentation of proposed mapping of inactivated concepts, which have been identified to be potentially ambiguous, to one or more persisting or new concepts.

## 1. Proposed hierarchy improvement

Thoracic cross-sectional segment of trunk (new concept) Syn: Cross-sectional thorax  
67734004|Structure of thoracic segment of trunk (body structure)| Syn: |Upper trunk structure|

Abdominopelvic cross-sectional segment of trunk (new concept) Syn: Cross-sectional abdominopelvis  
Abdominal cross-sectional segment of trunk (new concept) Syn: **Cross-sectional abdomen**

Pelvic cross-sectional segment of trunk (new concept) Syn: Cross-sectional pelvis  
12921003|Pelvic structure (body structure)|

Cavity of false and/or true pelvis (new concept) Syn: Pelvic cavity structure  
True pelvic cavity (new concept)  
False pelvic cavity (new concept)

3665003 |Pelvic wall structure (body structure)|  
118645006|Bone structure of pelvis (body structure)|  
87770006 |Pelvic floor structure|

False pelvic structure (new concept)  
False pelvic cavity (new concept)  
80266002|Minor pelvis structure (body structure)|  
True pelvic cavity (new concept)

46452000|Sacral region back structure (body structure)|  
72143005|Sacrococcygeal region structure (body structure)|  
38864007|Perineal structure (body structure)|

63337009 |Abdominopelvic segment of trunk (body structure)| Syn: Lower trunk structure  
**Intra-abdominopelvic structure and/or anterior abdominal wall** Syn: **Abdomen**  
Intra-abdominopelvic structure and/or anterior abdominal wall, excluding  
intra-pelvic structure of true pelvis (New concept) Syn: **Abdomen proper**

609616003 |Abdominopelvic segment excluding true pelvic segment of trunk (body structure)|  
Syn: Abdomen proper segment of trunk  
Intra-abdominopelvic structure and/or anterior abdominal wall, excluding  
intra-pelvic structure of true pelvis (New concept) Syn: **Abdomen proper**

37822005|Lower back structure (body structure)|  
52612000|Lumbar region back structure (body structure)|  
46452000|Sacral region back structure (body structure)|  
72143005|Sacrococcygeal region structure (body structure)|

609617007 |Pelvic segment of trunk structure (body structure)|  
Syn: Structure of pelvic region of trunk  
12921003|Pelvic structure (body structure)|  
21844003|Pelvic cavity structure (body structure)|  
False pelvic cavity (new concept)  
True pelvic cavity (new concept)  
118645006|Bone structure of pelvis (body structure)|  
False pelvic structure (new concept)  
80266002|Minor pelvis structure (body structure)|

46452000|Sacral region back structure (body structure)|  
72143005|Sacrococcygeal region structure (body structure)|  
38864007|Perineal structure (body structure)|  
77142006|External genitalia structure (body structure)|

## 2. The parsimonious use of polysemy

The ambiguity and variability of the use of the term 'abdomen' requires careful thought. It would be inappropriate to outlaw the use of such a common term, yet it is important to avoid its assignment to a single concept which would bias its meaning and choice of concept by users. The assignment of a 'common' synonym to more than one concept (polysemy) is avoided in SNOMED CT but the circumstance of 'abdomen' is exceptional. There are two possible solutions:

A. Limit 'Abdomen' to a single concept and use slight variants to describe important variants:

- *Intra-abdominopelvic structure and/or anterior abdominal wall* Syn: **Abdomen**
- *Intra-abdominopelvic structure and/or anterior abdominal wall, excluding intra-pelvic structure of true pelvis* (New concept) Syn: **Abdomen proper**
- *Abdominal cross-sectional segment of trunk* Syn: **Cross-sectional abdomen**

This approach is to provide 'abdomen' for indexing and searching in description variants. The term 'abdomen' is assigned to a single concept that supports most common clinical uses. The slight description variants can help users to choose the appropriate concept in anatomy since anatomy is context neutral. For example, it is clear that the *skin structure of abdomen* is different to the *skin structure of cross-sectional abdomen*. The former only includes skin of the anterior abdominal wall but the later also includes skin of the back.

However, it is unnecessary to use these variant descriptions of abdomen when the context is clear. For example, 'CT of abdomen (procedure)' is a valid and semantically clear description, because 'abdomen' means cross-sectional in the context of computed tomography imaging. It is unnecessary to have a description of 'CT of cross-sectional abdomen'.

B. Make an exception and allow ALL following NEW concepts described by their FSN to have a common synonym of **Abdomen**:

- *Intra-abdominopelvic structure and/or anterior abdominal wall* Syn: **Abdomen**
- *Intra-abdominopelvic structure and/or anterior abdominal wall, excluding intra-pelvic structure of true pelvis* (New concept) Syn: **Abdomen**
- *Abdominal cross-sectional segment of trunk* Syn: **Abdomen**

This approach will contradict the established Editorial Guide and is dependent on implementers and users understanding the notion of polysemy and explicitly choosing the correct variant. It could cause more confusion than help. For example, it is not clear about the meaning for a concept such as *skin structure of abdomen*. The searching of 'abdomen' in anatomy would return the exact same term 'abdomen' three times. It would require an additional technical solution to help users distinguish between those options. For example, an algorithm to inform the choice, by displaying FSN or definition, to avoid incorrect selection of concept. This may increase the complexity for implementation with negligible benefit to users.

### 3. Proposed inactivations and replacements

Once the approach is agreed, the actions (new concepts, inactivations and replacements) can be implemented in the production of terminology. For example, 113345001|Abdominopelvic structure (body structure)| with preferred term 'Abdomen' will be inactivated as ambiguous and the following concepts offered as potential replacements:

- Abdominal cross-sectional segment of trunk (Cross-sectional abdomen),
- Intra-abdominopelvic structure and/or anterior abdominal wall (Abdomen)
- Intra-abdominopelvic structure and/or anterior abdominal wall, excluding intra-pelvic structure of true pelvis (Abdomen proper structure)

## Structure concepts in anatomy and modeling

The SNOMED CT anatomy hierarchy differentiates classes of entire anatomical entities from classes of parts of entire anatomical entities.

Entire concept denotes a class that is instantiated by entire anatomical entities of some kind e.g. entire heart is instantiated by all individual hearts. The FMA concept should be mapped to entire concepts in SNOMED CT.

Part concept denotes a class that is instantiated by all anatomical entities that are a proper part of some entity of a given kind, for example heart part is instantiated by all entities that are a proper part of some heart, e.g. my mitral valve, your right ventricle, Joe's sinus node. Heart part is not instantiated by any heart.

Structure concept denotes a class that is the aggregation of an entire entity and/or its parts, which is commonly used in clinical practice and it provides convenience to assist with the logic-based definitions and queries, e.g. liver structure represents entire liver and/or any part of the liver.

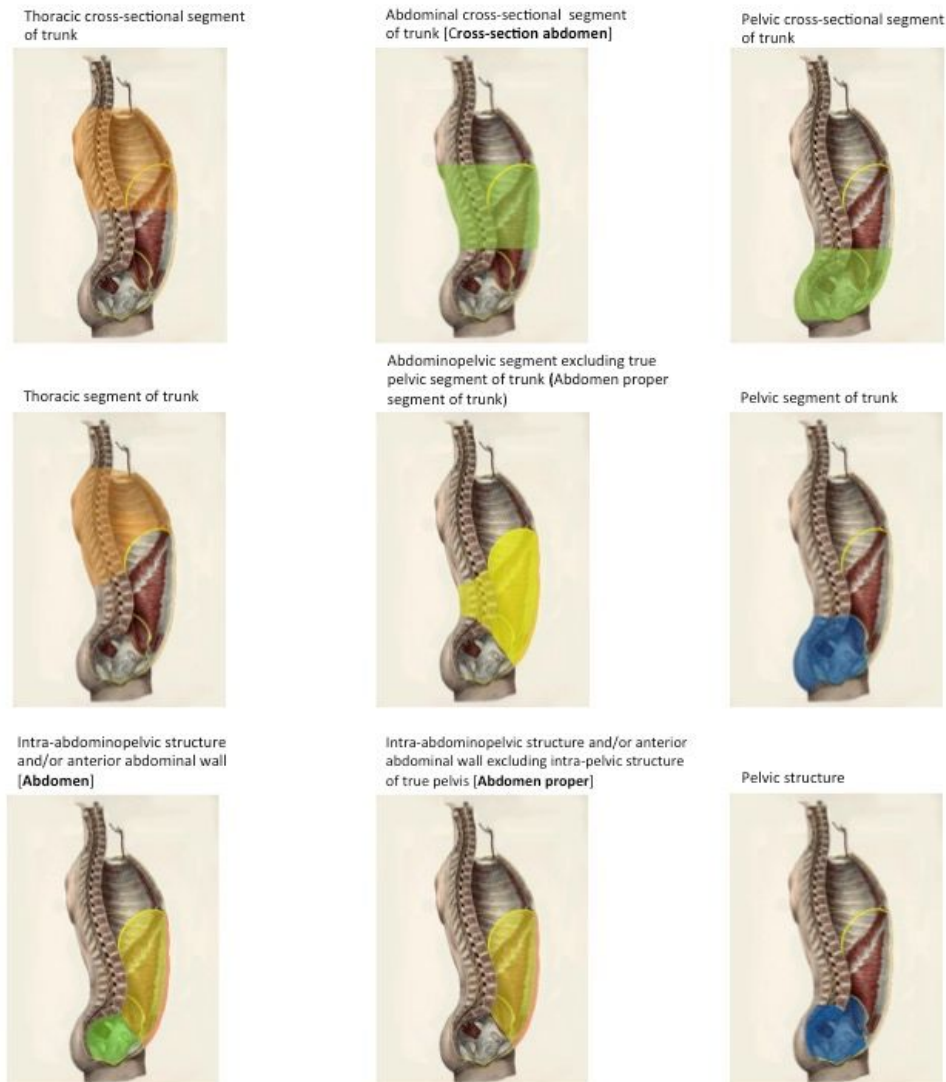Following the SEP (Structure, Entire, Part) model and the semantics of structure concepts in SNOMED CT, "CT of abdominopelvic structure" is logically different to "CT of abdomen and pelvis structures". For example, "CT of liver" is a subconcept of "CT of abdominopelvic structure" because Liver structure is a subconcept of abdominopelvic structure. However, "CT of liver" is not a subconcept of "CT of abdomen and pelvis" because it does not scan any structure in pelvis. In contrast, "CT of abdomen" is a scan of the segment of trunk between the thorax and the false pelvis.

## Summary

This document has proposed the solution to support the requirements from the diagnostic imaging community by introducing the new concepts for cross-sectional segment of the trunk. The existing content related to abdomen can be improved with refined fully specified names and new text definitions. They are illustrated by the regions of the trunk in the figure 13.

- Cross-sectional segments of the thorax, abdomen and pelvis;
- Anatomical segments of the thorax, abdomen and pelvis; and
- Clinically used structures of the abdomen, abdomen proper and pelvis.

Figure 13. Regions of the trunk



## Appendix: Abdomen in medical ontologies, terminologies, classifications, and publications

### Foundational Model of Anatomy v.5

- Subdivision of trunk
  - Thoracic segment of trunk
  - Subdivision of abdominal segment of trunk
    - Lumbar region of abdominal segment of trunk
  - Subdivision of front of trunk
    - Abdominal segment of trunk
    - Abdomen (Abdominopelvic region)
    - Pelvis
    - Subdivision of abdomen
      - Abdomen proper (Anterior abdomen)
      - Abdominal quadrant
      - Epigastrium
      - Hypochondrium
      - Umbilicus
      - Lumbar part of abdomen
      - Hypogastrium
      - Inguinal part of abdomen
      - Anterior abdominal wall
      - ...
    - Subdivision of pelvis
      - Pelvis proper
      - Mons pubis
      - Perineum
  - Subdivision of back
    - Back of thorax
    - Back of abdomen
    - Back of pelvis
  - Wall of abdominal segment of trunk

## Terminologia Anatomica

- Second Edition, Federative International Programme for Anatomical Terminology, 2019

- Trunk
  - Thorax
    - Thoracic cavity
  - Abdomen
    - Abdominal cavity
  - Pelvis
    - Pelvic cavity
    - Perineum
  - Anterior trunk
    - Anterolateral thoracic wall
    - Anterolateral abdominal wall
  - Back
    - Back of thorax
    - Back of abdomen
  - Regions of abdomen
    - Hypochondriac region
    - Epigastric region
    - Lateral region of abdomen
    - Umbilical region
    - Inguinal region
    - Hypogastric region



## ICD-11

<https://icd.who.int/dev11/f/en#/http%3a%2f%2fid.who.int%2fcd%2fentity%2f1983193090>

Abdomen is the anterior part of the lower trunk. The posterior part is the lumbosacral region that is also part of the Back.

- Surface topography
  - Trunk
    - Upper trunk
    - Lower trunk
      - Abdomen
        - Upper abdomen
          - *Epigastrium*
          - *Hypochondrium*
        - *Periumbilical region*
          - *Umbilicus*
        - *Lateral lumbar region*
        - Lower abdomen
          - *Hypogastrium*
          - *Iliac region*
        - *Abdominal wall*
        - Umbilical cord
      - Lumbosacral region
        - Mid back
          - Lumbar paraspinal region
          - Posterior lumbar region
        - Lower back
          - Coccygeal area
          - Sacral region
            - Sacrococcygeal region
    - Back
      - Upper back
      - Mid back
      - Lower back
    - Anogenital region
  - Partonomic view
    - Walls in the body
      - *Abdominal wall*
        - *Epigastrium*
        - *Hypochondrium*
        - *Periumbilical region*
          - *Umbilicus*
        - *Lateral lumbar region*
        - *Hypogastrium*
        - *Iliac region*

## Medical Subject Headings

<http://bioportal.bioontology.org/ontologies/MESH?p=classes&conceptid=http%3A%2F%2Fpurl.bioontology.org%2Fontology%2FMESH%2FD000005>

- Torso
  - Abdomen - That portion of the body that lies between the *thorax* and the *pelvis*.
    - Abdominal Cavity
      - Peritoneum
      - Retroperitoneal Space
    - Abdominal Wall
    - Groin
    - Inguinal Canal
    - Umbilicus
  - Back
    - Lumbosacral Region
    - Sacrococcygeal Region
  - Pelvis - The space or compartment surrounded by the pelvic girdle (bony pelvis). It is subdivided into the greater pelvis and *lesser pelvis*. The pelvic girdle is formed by the *pelvic bones* and *sacrum*.
    - Lesser Pelvis - the part of the pelvis, inferior to the pelvic brim, that comprises both the pelvic cavity and the part of the *perineum* lying inferior to the *pelvic diaphragm*
    - Pelvic Floor
  - Thorax

## Radiology Lexicon

<http://bioportal.bioontology.org/ontologies/RADLEX/?p=classes&conceptid=http%3A%2F%2Fradlex.org%2FRID%2FRID56>

Based on (an older version of) the FMA

## UBERON

See discussion of segments of trunk issues (ventral or not) at:

<https://github.com/obophenotype/uberon/issues/537>