

Drug Allergy



Daniel Vervloet
Michel Pradal
Joëlle Birnbaum
Marie-Christine Koepfel

Phadia

*Daniel VERVLOET - Michel PRADAL - Joëlle BIRNBAUM
- Marie-Christine KOEPEL*

Department of Pneumology and Allergy
Department of Dermatology
Hôpital Sainte Marguerite
Hôpital Nord
Université de la Méditerranée
Marseille - France

DRUG ALLERGY

Copyright Phadia AB

Editorial coordination and bibliography : Dr David A. Lévy

Editorial assistant : Sandrine Fidalgo

Layout : Françoise Calley

Printed in France by Corlet imprimeur.

Editions de Condé

103 rue de Sèvres

75006 Paris

www.editions-de-conde.fr

TABLE OF CONTENTS

PREFACE	5
INTRODUCTION	6
I• DRUGS AND SUBSTANCES USED DURING ANESTHESIA AND INTENSIVE CARE	7
II• ANALGESICS AND ANTI-INFLAMMATORY DRUGS.....	43
III• ANTIBIOTICS AND ANTIPARASITE DRUGS, ANTIVIRAL AND ANTIFUNGAL DRUGS	57
IV• CHEMOTHERAPY DRUGS AND IMMUNO-SUPPRESSORS.....	139
V• DRUGS USED IN CARDIOLOGY AND VASCULAR DISORDERS	211
VI• DYES, PRESERVATIVES, ANTISEPTICS.....	261
VII• PRODUCTS USED IN DIALYSIS	289
VIII• DIAGNOSTIC AGENTS.....	295
IX• HORMONES AND ENZYMES.....	311
X• SERA AND VACCINES.....	333
XI• VITAMINS.....	359
XII• GASTROENTEROLOGY.....	371
XIII• BIOLOGICAL AGENTS.....	379
XIV• DRUGS USED IN NEUROLOGY AND RHEUMATOLOGY.....	407
XV• MISCELLANEOUS.....	435
INDEX.....	444

PREFACE

The first edition of this work was based on Dr. Michel Pradal's thesis, one of the requirements for his medical degree, which he obtained in 1987. Now, twenty years later, we have produced the fourth edition of this work. Our aim, as in the previous editions, is to help doctors, especially allergists, diagnosis drug allergy - a constantly expanding field - in a practical way. For each drug known or suspected of being responsible for allergic reactions, the incidence, clinical manifestations, diagnostic methods and management are described, with a few relevant references at the end of each section.

Many new drugs have appeared on the market during the last decade, biological agents for example, and they are included in this present edition.

This work was achieved thanks to the participation of Doctors Michel Pradal, Joëlle Birnbaum, and Marie-Christine Koepfel. I also want to thank Dr. David A. Levy for his help with the bibliography research and for editing the manuscript.

I hope that doctors will find the information in this book useful in their practice.

Daniel Vervloet

INTRODUCTION

Adverse drug reactions involve two different mechanisms: allergic and non-allergic reactions. Misclassification is frequent, and the word “allergy” is often misused. Twenty years ago, very few sessions at international allergy meetings focused on drug allergy. However, during the past decade a tremendous amount of work has been done on this subject, including epidemiological studies, immunological research on IgE and non-IgE mechanisms, as well as the development of drug allergy and drug vigilance networks.

However, it is still difficult for the clinician to manage a patient suffering from drug allergy. The incidence of these reactions, risk factors, mechanisms, clinical manifestations, diagnostic methods and management may differ from drug to drug and from patient to patient. As I mentioned 10 years ago in the Third Edition of this book “as drug allergy is concerned, there is one general rule, i.e., there are no general rules”. That is why in this book we have tried to develop for each drug specific rules to follow to arrive at a correct diagnosis and then the best way to manage the patient.

I

DRUGS USED FOR ANESTHESIA AND INTENSIVE CARE

Alfentanil, Fentanyl, Remifentanil, Sufentanil

Major morphinomimetic analgesics, used in anesthesia.

I Incidence

Extremely rare.

I Risk factors

Previous sensitization to another phenylpiperidine drug.

I Clinical manifestations

• General

The clinical manifestations of anaphylaxis are classified into five grades of severity:

- Grade I: mild, self-limiting reactions, e.g., isolated skin symptoms;
- Grade II: moderate reactions quickly responding to therapy, e.g., hypotension, bronchospasm or multivisceral symptoms;
- Grade III: severe reactions requiring prolonged treatment, e.g., anaphylactic shock;
- Grade IV: cardiac and respiratory arrest;
- Grade V: death

• **Cutaneous:** application site reactions including itching, erythema, papules and oedema; diffuse rash.

I Diagnostic methods

Skin tests: Concentration normally non-reactive in practice.

- **Alfentanil** (0.5mg/ml): Prick test: undiluted (0.5mg/ml)
Intradermal tests 1/10 (50µg/ml)
- **Fentanyl** (0.05 mg/ml): Prick test: undiluted (0.05 mg/ml)
Intradermal tests: 1/10 (5µg/ml)
- **Remifentanyl** (0.05 mg/ml): Prick test: undiluted (0.05 mg/ml)
Intradermal tests: 1/10 (5µg/ml)
- **Sufentanil** (0.005 mg/ml): Prick test: undiluted (0.005 mg/ml)
Intradermal tests: 0.5µg/ml

Dilution series is used starting with a 1/10,000 dilution and increasing the concentration up to the highest level that usually does not produce a reaction in non-allergic individuals.

I Mechanisms

These drugs apparently do not induce non-specific mediator release from mast cells.

IgE-mediated hypersensitivity, as indicated by positive skin-tests is restricted to fentanyl.

I Management

Avoidance.

No cross-reactivity between the different opioid subclasses phenanthrenes, phenylpiperidines, and diphenylheptanes.

References

Muijsers RB, Wagstaff AJ. *Transdermal fentanyl: an updated review of its pharmacological and therapeutic efficacy in chronic cancer pain control. Drugs* 2001;61:2289 – 2307.

Bennett MJ, Anderson LK, Mc Millan JC, et al. *Anaphylactic reaction during anaesthesia associated with positive intradermal skin test to fentanyl. Can Anaesth Soc. J* 1986;33:75-8.

Local anesthetics

With their ability to block pain signals to the brain, local anesthetics (LAs) have made possible many surgical procedures once thought impossible. LAs are generally safe and well tolerated.

Local anesthetics are classified as either ester or amide compounds:

▶ Ester LAs, all derivatives of para-aminobenzoic acid, include cocaine, procaine, tetracaine, benzocaine, and chlorprocaine. Ester LAs are associated with a higher incidence of allergic reactions.

▶ Amide LAs, by far the most widely used today, include lidocaine, mepivacaine, etidocaine, prilocaine, bupivacaine, and dibucaine.

Incidence

2 to 3% of local anesthetics (fainting).

The true incidence of allergic reactions to LAs is unknown, but exceedingly rare, less than 1% of all anesthetic-induced reactions.

The incidence of systemic toxicity has significantly decreased in the past 30 years, from 0.3 to 0.01%.

Risk factors

Long term topical application of local anesthetics can cause contact dermatitis.

Clinical manifestations

Reactions unrelated to these drugs:

- psychomotor: hyperventilation, vaso-vagal and adrenergic reactions
- sympathetic stimulation
- operative trauma
- traumatic subcutaneous emphysema

Toxic responses in normal subjects:

Dysrhythmias, cardiovascular collapse, central nervous system effects, transient neuropathic symptoms.

Overdose is not common in dental practice but can occur; in rare cases an overdose can be fatal. The central nervous system is most susceptible to the toxic effects. Cardiovascular depression may occur following administration.

Adjuvants that may induce reactions (but not to the local anesthetic itself):

epinephrine, sulfites, parabens, antibiotics, analgesics

Immediate allergic reactions

Urticaria, angioedema and anaphylactic shock are exceptional.

Contact urticaria, an immediate-type reaction is rare.

Delayed-type hypersensitivity reactions

These reactions occur particularly with para-amino benzoic acid esters but also with amide derivatives, especially with the combination of topical lidocaine and prilocaine, which is now used more and more frequently.

Delayed reactions are most often localized eczema; at the site of application, but they may also be

more disseminated; localized ectopic eczema; hand dermatitis in exposed professionals (e.g., dentists), and more rarely delayed edema may occur. Fixed pigmented erythema is quite exceptional. Petechial purpuric type reactions of non-allergic origin are due to excessively prolonged application of an LA (e.g., with an anesthetic cream).

I Diagnostic methods

Skin test can be performed with commercial LA without adrenaline:

Prick-tests: undiluted (1:1) LA

Intradermal tests: 1:10 LA dilution. There are a few case reports with immediate reactions; positive ID tests with concentrations from 1:10,000 to 1:100 have been reported.

Patch tests: These are useful in the diagnosis of delayed-type reactions (e.g., contact dermatitis) to esters and amides. Standardized commercial solutions (e.g., 5% benzocaine in the ICDRG battery and various other LAs) are available; test with the topical or injectable product incriminated by the patient; test with various dental products if the reaction occurred during dental intervention. The resulting reactions are read immediately, 20 minutes later (before occlusion), at 48 hours and again at 72 hours.

LA-specific IgE: No commercial tests are available and such assays have never been reported.

Challenge test may be performed with LA containing adrenaline. The test is done with a subcutaneous injection of 1ml of undiluted LA.

I Mechanisms

Adverse reactions are usually due to an inadvertent rapid intravascular injection or extravascular administration of an excessive amount of LA.

IgE-mediated reactions have been demonstrated only rarely. Cross reactions among amide LAs are not always encountered.

The role of preservatives (parabens, sulfites) in LAs remains controversial.

Contact dermatitis induced by esters and amides is a Type IV immunological reaction.

I Management

Be aware of cross-reactivity, which is frequent with ester LAs but unusual with amide LAs.

Alternative therapies

Use a different LA in the amide group after a negative skin test and negative local challenge test.

References

Boren E, Teuber SS, Naguwa SM, et al. A critical review of local anesthetic sensitivity. *Clin Rev Allergy Immunol* 2007;32:119-127.

Gunera-Saad N, Guillot I, Cousin F, et al. Immediate hypersensitivity reactions to local anesthetics: diagnostic and therapeutic approach (Article in French). *Ann Dermatol Venerol* 2007;134:333-6.

Jacobsen RB, Borch JE, Bindlev-Jensen C. Hypersensitivity to local anaesthetics. *Allergy* 2005;60:262-64.

Mc Lure HA, Rubin AP: Review of local anesthetic agents. *Minerva Anestesiologica* 2005;71:59-74.

Morais-Almeida M, Gaspar A, Marhindo S, et al. Allergy to local anaesthetic to the amide group with tolerance to procaine. *Allergy* 2003;58(8):827-28.

Vigan M. Exploration of patients with suspected allergy to local anesthetics (Article in French). *Ann Dermatol Venereol* 2001;128:792-9.

Codeine

Codeine (methylnorphine, morphine monomethyl ether) belongs to the opioid subclass phenanthrenes.

■ Incidence

Very low.

■ Clinical manifestations

• General

The clinical manifestations of anaphylaxis are classified into five grades of severity:

- Grade I: mild, self-limiting reactions, e.g., isolated skin symptoms;
- Grade II: moderate reactions quickly responding to therapy, e.g., hypotension, bronchospasm or multivisceral symptoms;
- Grade III: severe reactions requiring prolonged treatment, e.g., anaphylactic shock;
- Grade IV: cardiac and respiratory arrest;
- Grade V: death.

• **Cutaneous:** pruritus, urticaria, angioedema, maculopapular rash, erythroderma, DRESS, scarlatiniform rash, diffuse eczema, fixed drug eruption, erythema multiforme, Henoch-Schönlein purpura

• **Respiratory:** bronchospasm.

• **Others:** occupational rhinitis, asthma, eczema

Pancreatitis

Arterial hypotension in case of injection by the intravenous route.

■ Diagnostic methods

Skin tests

The value of skin prick testing in opiate-sensitive individuals is uncertain as opiates cause non-specific weals by direct degranulation of mast cells.

Patch tests

Open test on previous fixed drug eruption lesions, with lecture from 30 minutes to 24 hours (codeine phosphate 0.1% aqueous solution)

1% and 5% in pet

■ Mechanisms

IgE-mediated reaction: rare. One case of anaphylaxis to pholcodine has been reported.

Non-immunological histamine release (pruritus, urticaria).

Delayed-type hypersensitivity (rash).

Vasomotor depression: ganglion blockade and histamine release could explain hypotension.

I Management

Avoidance.

References

- Santoro D, Stella M, Castellino S. Henoch-Schönlein purpura associated with acetaminophen and codeine. Clin Nephrol 2006;66:131-4.*
- HogenEsch AJ, van der Heide S, van den Brink W, et al. Contact allergy and respiratory/mucosal complaints from heroin (diacetylmorphine). Contact Dermatitis 2006;54:42-9.*
- Codreanu F, Morisset M, Kanny G, et al. Allergy to pholcodine: first case documented by oral challenge. Allergy 2005;60:544-55.*
- Gastaminza G, Audicana M, Echenagusia MA, et al. Erythrodermia caused by allergy to codeine. Contact Dermatitis 2005;52:227-8.*
- Enomoto M, Ohi M, Teramae K, et al. Codeine phosphate - induced hypersensitivity syndrome. Ann Pharmacother 2004;38:799- 802.*

Dextrans

Dextrans, which are glucose polymers, are used as plasma expanders, in thromboembolic prevention and as distention and irrigating fluids for various endoscopic procedures. They are produced by *Leuconostoc mesenteroides*.

■ Incidence

FDA received 366 clinical dextran adverse event reports from 1969 to 2004 of which 25% were anaphylaxis/anaphylactoid events.

1/2,000 grade III /IV without hapten inhibition; 1/70,000 grade III/IV with hapten inhibition.

Side effects due to dextran 1, mostly mild, are reported to occur in approximately 1/100,000 doses.

■ Risk factors

Atopy (grade I and II reactions).

High levels of dextran-reactive antibodies (grade III and IV reactions).

■ Clinical manifestations

- **General:** anaphylactic shock, fever, death
- **Cutaneous:** flushing, pruritus, urticaria with or without angioedema, macular rash.
- **Respiratory:** dyspnea, tightness of chest, wheezing, coughing, pulmonary edema.
- **Other adverse effects:** nausea, vomiting, joint pains, convulsions, altered coagulation profiles, renal failure.

■ Diagnostic methods

Skin tests (usually negative).

Dextran-specific IgG and IgM (ELISA): the presence of a pre-existing high level of specific IgG antibodies is a major risk factor.

■ Mechanisms

Anaphylactoid reaction caused by dextran-reactive IgG antibodies.

Fatal reactions have occurred in patients with extremely high titers of dextran-reactive antibodies. When dextran is infused into patients with a high titer of dextran-reactive antibodies, immune complexes are generated, which leads to the release of mediators and the subsequent reaction.

■ Management

Hapten inhibition with dextran 1 (molecular weight: 1,000D, Promit), which has been available since 1982 for the prevention of severe dextran-induced anaphylactic reactions. When infused immediately before clinical dextrans, dextran 1 (20ml) significantly reduces the incidence of severe anaphylactoid reactions.

Concerning administration to pregnant women prior to epidural analgesia, dextrans should be avoided and replaced by gelatins or crystalloid solutions due to the risk to the fetus of anaphylactic

shock in the mother (anti-dextran IgG crosses the placental membrane). Eighteen neonatal deaths and 7 cases of neurological impairment in neonates have been reported in France.

References

Zinderman CE, Landow L, Wise RP. Anaphylactoid reactions to Dextran 40 and 70: reports to the United States Food and Drug Administration, 1969 to 2004. *J Vasc Surg* 2006;43:1004-9.

Hedin H, Ljungstrom KG. Prevention of dextran anaphylaxis. Ten years experience with hapten dextran. *Int Arch Allergy Immunol* 1997;113:358-9.

Bircher AJ, Hedin H, Berglund A. Probable grade IV dextran-induced anaphylactic reaction despite hapten inhibition. *J Allergy Clin Immunol* 1995;95:633-4.

Ljungstrom KG. Safety of dextran in relation to other colloids-ten years' experience with hapten inhibition. *Infusionsther Transfusionsmed* 1993;20:206-10.

Barbier P, Jonville AP, Autret E, et al. Fetal risks with dextrans during delivery. *Drug Saf* 1992;7:71-3.

Diazepam

Leading benzodiazepine, widely used against seizures and as a muscle relaxant.

■ Incidence

Very rare since cremophor EL was no longer used as solvent.
One case report in the last 25 years.

■ Clinical manifestations

- **General:** anaphylactic shock, collapse.
- **Cutaneous:** erythema, urticaria with or without angioedema, fixed drug eruption, acute immune thrombocytopenic purpura, pigmented purpuric dermatosis, delayed maculopapular rash, eczema, bullous eruption (intoxication), conjunctivitis.
- **Respiratory:** dyspnea, bronchospasm.
- **Renal:** allergic interstitial nephropathy.

■ Diagnostic methods

Skin tests

Usually negative, but one case with a positive prick test and positive intradermal tests at 5mg/ml has been reported.

No specific IgE assay.

Challenge test if necessary.

■ Mechanisms

Unknown.

Hypothesis:

- Immediate IgE-mediated hypersensitivity: Prausnitz-Kustner test positive in one case. The active metabolite common to all benzodiazepines is desmethyldiazepam, which appears to be an antigenic molecule and accounts for cross-reactivity among different benzodiazepines.
- Non-specific histamine release.
- Complement activation.

■ Management

Avoidance.

References

Asero R. Hypersensitivity to diazepam. *Allergy* 2002;57:1209.

Dumal M., Gillon JC, Guilbert JM, et al. Acute respiratory distress syndrome after an anaphylactic shock (role of diazepam and succinylcholine)- (Article in French). *Cahiers d'Anesthésiologie* 1984;32:313-5.

Huttel MS, Schou Olesen A, Stoffersen E. Complement-mediated reactions to diazepam with cremophor as solvent (Stesolid M.R.). *Br J Anaesth* 1980;52:77-9.

Droperidol

Droperidol is a neuroleptic drug (butyrophenone class) frequently used postoperatively as an antiemetic and sedative.

■ Incidence

Exceptional.

■ Risk factors

Phenothiazine hypersensitivity.

■ Clinical manifestations

- **General:** anaphylactic shock.
- **Cutaneous:** angioedema, tongue-swelling, rash.
- **Respiratory:** bronchospasm.

■ Diagnostic methods

Skin tests

Intradermal skin tests (1/1000) reported positive in 2 patients.

No specific Ige assay.

■ Mechanisms

IgE-mediated hypersensitivity (positive cutaneous tests, one case with a positive Prausnitz-Kustner test).
Increase in serum histamine due to inhibition of histamine-N-methyltransferase.

■ Management

Avoidance.

References

Palombaro JF, Klingelberger CE. Angioedema associated with droperidol administration. *Ann Emerg Med* 1996;27:379-81.

Clark RJ. Tongue-swelling with droperidol. *Anaesth Intensive Care* 1993;21:375.

Corke PJ, Murray G. Angio-oedema with droperidol. *Anaesth Intensive Care* 1993;21:375.

Moss J, Verburg KM, Henry DP. Droperidol inhibits histamine N-methyl transferase. *Anesthesiology* 1985;63:A303.

Occelli G, Saban Y, Pruneta RM, et al. Two cases of anaphylaxis from droperidol (Article in French). *Ann Fr Anesth Reanim* 1984;3:440-2.

Etomidate

An imidazole derivative, structurally unrelated to any of the other intravenous hypnotic agents. Short-acting general anesthetic.

■ Incidence

Extremely rare.

■ Clinical manifestations

Mainly cutaneous and gastrointestinal signs.
Few cardiovascular and respiratory adverse effects.

■ Diagnostic methods

Skin tests

Prick test: undiluted (2mg/ml)

Intradermal skin tests: 1/10 dilution (0.2mg/ml)

No *in vitro* diagnostic methods are currently available.

■ Mechanisms

Etomidate is a poor histamine releaser. Possible hypersensitivity reaction to excipients such as egg lecithin and soybean oil.

■ Management

Avoidance.

References

Moorthy SS, Laurent B, Pandya P, et al. Anaphylactoid reaction to etomidate: report of a case. *J Clin Anesth* 2001;13:582-4.

Fazackerley E.J, Martin A.J, Tolhurst-Cleaver C.L, et al. Anaphylactoid reaction following the use of etomidate. *Anaesthesia* 1988;43:953-4.

Gelatins

Gelatins are used as plasma expanders in emergency situations. Fluid gelatins are produced by hydrolysis of collagen and chemical modification:

- ▶ succinylation (modified fluid gelatin);
- ▶ cross-linking with glyoxal and subsequent degradation by oxidation and heating (oxypolygelatin);
- ▶ cross-linking with hexamethylene diisocyanate (urea-linked gelatin).

■ Incidence

- Urea-linked gelatins: in 0.15 to 0.85% administrations (0.05% of serious manifestations).
- Oxypolygelatins: in 0.62% of administrations.
- Modified fluid gelatins: in 0.07% to 0.34 % of administrations (0.016% of serious manifestations).

■ Risk factors

Gelatin food allergy
Drug allergy.
Male gender.

■ Clinical manifestations

- **General:** anaphylactic shock.
- **Cutaneous:** urticaria.
- **Respiratory:** bronchospasm, sneezing.

■ Diagnostic methods

Skin tests

Prick test with the pure gelatine solution

Intradermal skin tests: positive from 1/1000 to 1/10 in a few patients after an anaphylactic shock

Serum specific IgE assay (ImmunoCAP/Phadia).

In vitro basophil activation assays

■ Mechanisms

IgE-mediated hypersensitivity.

Direct histamine release (urea-linked gelatins due to excess diisocyanate)

■ Management

Avoidance.

References

Apostolou E, Deckert K, Puy R, et al. Anaphylaxis to Gelofusine confirmed by in vitro basophil activation test: a case series. *Anaesthesia* 2006;61:716-7.

Worm M, Sterry W, Zuberbier T. Gelatin-induced urticaria and anaphylaxis after tick-borne encephalitis vaccine. *Acta Derm Venereol* 2000;80:232.

Kelso JM. The gelatin story. *J Allergy Clin Immunol* 1999;103:200-2.

Laxenaire MC, Charpentier C, Feldman L. Anaphylactoid reactions to colloidal plasma substitutes: incidence, risk factors, mechanisms. A French multicentric prospective study (Article in French). *Ann. Fr. Anesth. Reanim* 1994;13:301-10.

Duffy BL, Harding JN, Fuller WR, et al. Cardiac arrest following Haemaccel. *Anaesth Intensive Care* 1994; 22:90-2.

Ring J. Anaphylactoid reactions to intravenous solutions used for volume substitution. *Clin Rev Allergy* 1991;9:397-414.

Hydroxyethylstarch (HES)

Hydroxyethylstarch or hetastarch compounds are synthetic polymers derived from amylopectin. The different HES preparations are defined by concentration, molar substitution, mean molecular weight and the C2/C6 ratio of substitution.

They are classified according to their *in vitro* molecular weight in high, medium, and low molecular weight preparations. However, HES is metabolized after administration and its both pharmacodynamic properties and adverse events depend on the resulting *in vivo* molecular weight. Hetastarch and pentastarch have a molecular weight of 480kDA and 250kDA respectively. They are used as plasma substitute for improving microcirculation.

Third-generation: 6%HES 130/0.4

■ Incidence

0.06% to 0.09% (grade I to IV)

0.006% (grade III/IV)

Pruritus: in 10 to 40% of patients

■ Clinical manifestations

• **General:** anaphylactic shock.

• **Cutaneous:** severe pruritus is the major side effect. Pruritus, beginning several weeks after the hydroxyethyl starch administration, frequently severe, with a negative impact on the patient's quality of life, refractory to treatment, can persist for up to 12-24 months, dose-dependant but may be provoked by low doses. Erythema and urticaria.

• **Others:** Renal impairment, hemorrhage.

■ Diagnostic methods

Skin tests

Prick test with the undiluted solution

Intradermal skin tests: 1/10 and undiluted: seldom positive.

Absence of serum **IgE assays**.

Anti-HES IgM, IgG, IgA assays: the clinical relevance of these assays remains unknown.

Evidence for an IgE-mediated reaction caused by pentastarch was obtained by passive donor basophil sensitization in one study and flow cytometric analysis of activated basophils.

■ Mechanisms

HES-reactive antibodies are extremely rare and without clinical relevance.

Poor histamine releaser.

Complement activation.

Non-IgE anti-HES specific antibodies.

Pruritus: direct stimulation of cutaneous nerves by HES deposits in macrophages and small peripheral nerves

■ Management

Avoidance.

References

Bork K. Pruritus precipitated by hydroxyethyl starch: a review. *Br J Dermatol* 2005;152:3-12.

Ebo DG, Schuerwegh A, Stevens WJ. Anaphylaxis to starch. *Allergy* 2000;55:1098-9.

Treib J, Baron JF, Grauer MT, et al. Assessment of the safety and tolerance of 6% hydroxyethyl starch (200/0.5) solution: a randomized controlled epidemiology study. *Intensive Care Med* 1999;25:258-68.

Deterich HJ, Kraft D, Sirtl C, et al. Hydroxyethylstarch antibodies in humans: incidence and clinical relevance. *Anesth.Analg.*1998;86:1123-6.

Kreimeier U, Christ F, Kraft B, et al. Anaphylaxis due to hydroxyethylstarch reactive antibodies. *Lancet* 1995;346:49-50.

Ketamine

A phenylcyclidine derivative

I Incidence

Extremely rare.

I Clinical manifestations

- **General:** rash, urticaria, respiratory (laryngospasm), anaphylactic shock.
- **Cutaneous:** morbilliform rash, urticaria, erythema at the point of injection.

I Diagnostic methods

Skin tests

Concentration that is normally non-reactive in practice: 1mg/ml

Prick test: undiluted (10mg/ml)

Intradermal skin tests: 1mg/ml (1/10). A dilution series is used, starting with a 1:100 dilution and increasing the concentration up to the highest level that does not produce a reaction in non-allergic individuals.

I Mechanisms

Probably an IgE-mediated reaction.

I Management

Avoidance.

References

Boynes SG, Lemark AL, Skradski DM, et al. An allergic reaction following intramuscular administration of ketamine and midazolam. *J Clin Pediatr Dent* 2006;31:77-9.

Karila C, Brunet-Langot D, Labbez F, et al. Anaphylaxis during anesthesia: results of a 12-year survey at a French pediatric center. *Allergy* 2005;60:828-34.

Benoit Y, Topenot I. Diagnostic approach to peri-operative allergic drug reactions using skin tests (Article in French). *John Libbey Eurotext* 2005, pp183-190

Mertes PM, Laxenaire MC, Alla F. Anaphylactic and anaphylactoid reactions occurring during anesthesia in France in 1999-2000. *Anesthesiology* 2003;99:536-45.

Latex

Natural rubber latex (NRL) is extracted from the *Hevea brasiliensis* tree and, after addition of low molecular weight chemical additives, is used in the production of rubber goods. The main products are household and surgical gloves, balloons, cofferdams used in dentistry, caps, face masks, condoms, etc. The first report of allergy to latex, published in 1927, was the case of a patient with chronic urticaria due to a dental prosthesis made with latex. Many cases of anaphylactic shock due to contact with latex gloves have been reported since 1987.

■ Incidence

The prevalence of latex sensitization in the general population, based on latex-positive skin tests responses, was estimated to be approximately 2.1 to 3.7%. These values were significantly increased in risk groups, notably in patients with spina bifida (from 24 to 64%) and in healthcare workers, including dentists (up to 15%). A high prevalence of latex allergy also exists in others professions in contact with latex goods: hairdressers, housekeeping and restaurant personnel, latex goods manufacturers, and construction workers, to name a few.

20% of latex-related episodes of anaphylactic shock occur during general anesthesia.

■ Risk factors

Atopy

Health care workers (HCWs)

Fruit allergy

Multiple surgical procedures, especially children with spina bifida (SB) or other congenital malformations

■ Clinical manifestations

• **General:** anaphylaxis

Perioperative anaphylactic shock due to latex usually begins more than 15 minutes after induction of anesthesia. The first symptom is rash or urticaria followed 2 or 3 minutes later by severe vascular collapse with or without bronchospasm, requiring blood volume expansion and adrenaline. Anaphylactic shock may occur while putting latex gloves on. It has been reported during gynecological examinations and in patients undergoing dental procedures.

• **Cutaneous:** pruritus, rash, angioedema, contact urticaria, generalized urticaria, contact dermatitis, airborne contact dermatitis.

• **Respiratory:** rhinoconjunctivitis and asthma. This is usually related to inhalation of latex-bearing cornstarch coming from powdered NRL gloves.

■ Diagnostic methods

A detailed *clinical and occupational history* is essential

Skin tests

Prick tests performed with commercial standardized NRL extract

Prick tests can be done with glove eluates (prepared by brief extraction in isotonic sodium chloride solution).

A use test with latex gloves can be performed - with care - when all others tests are negative and when there is a highly suspicious clinical history.

Patch test with latex solution (tests may be irritant), rubber additives

Specific latex IgE antibodies: ImmunoCAP Phadia and other methods are available.

I Mechanisms

- *IgE-mediated hypersensitivity:*

Thirteen latex allergens have been identified and characterized:

Hev b 1: rubber elongation factor. Major allergen for SB patients.

Hev b 2: [beta]-1.3-glucanase. Major allergen. Involved in latex-fruit syndrome.

Hev b 3: small rubber particle protein. Major allergen for SB patients.

Hev b 4: cyanogenic Glucosidase. Important allergen for HCWs and SB patients.

Hev b 5: acidic protein. Major allergen.

Hev b 6: prohevein/hevein. The most important allergen in the latex-fruit syndrome.

Hev b 7: patatin-like protein. Sequence identity with potato allergen patatin.

Hev b 8: profilin. Involved in latex-fruit syndrome.

Hev b 9: enolase.

Hev b 10: manganese superoxide dismutase.

Hev b 11: class 1 chitinase. Latex-fruit syndrome.

Hev b 12: lipid transfer protein.

Hev b 13: lipolytic esterase.

Based on the results of published studies, Hev b 2, Hev b 5, Hev b 6 and Hev b 13 are the major latex allergens in sensitized adults.

An association between latex allergy and hypersensitivity to a number of plant foods, particularly fruits, is well established. Class 1 chitinases and latex hevein seem to be the allergens responsible for most of the cross-reactivity in the latex-fruit syndrome. Other latex allergens, such as profilins, Hev b 5, Hev b 7, and the [beta]-1.3-glucanases, are potentially implicated.

- Delayed-type allergy is responsible for contact dermatitis, usually due to a chemical additive.

I Management

- Substitution of low protein powder-free NRL gloves or latex-free gloves for powdered latex gloves greatly reduces NRL aeroallergens, NRL sensitisation, and NRL asthma in healthcare workers.

- Use of non latex gloves and “latex-free” operating rooms for allergic patients undergoing surgery or endoscopy.

- **Immunotherapy:** clinical efficacy observed mainly as alleviation of cutaneous symptoms, although improvements in rhinitis and asthma have also been observed. Systemic reactions were encountered, indicating that this treatment must be administered in a hospital setting. Novel approaches to avoid the risk of serious adverse reactions is required: recombinant hypoallergenic preparations and T cell epitope-based peptides are readily standardized and have been identified as potentially safe, but the optimal route of delivery, the vehicle and the adjuvant for clinical use have not been determined.

- **Anti-IgE treatment:** Good tolerability.

References

- Rolland JM, O'Hehir RE. Latex allergy: a model for therapy. *Clin Exp Allergy* 2008;38:898-912.
- Bousquet J, Flahault A, Vandenplas O, et al. Natural rubber latex allergy among health care workers: a systematic review of the evidence. *J Allergy Clin Immunol* 2006;118:447-54.
- Wagner S, Breiteneder H. Hevea brasiliensis latex allergens: Current panel and clinical relevance. *Int Arch Allergy Immunol* 2005;136:90-7.
- Yeang H-Y. Natural rubber latex allergens: new developments. *Curr Opin in Allergy Clin Immunol* 2004;4:99-104.
- Leynadier F, Doudou O, Gaouar H. Effect of omalizumab in health care workers with occupational latex allergy. *J Allergy Clin Immunol* 2004;113:360-1.
- Sastre J, Fernandez-Nieto M, Rico P. Specific immunotherapy with standardized latex extract in allergic workers: a double-blind, placebo-controlled study. *J Allergy Clin Immunol* 2003;111:985-94.
- Allmers H, Schmengler J, Skudlik C. Primary prevention of natural rubber latex allergy in the German health care system through education and intervention. *J Allergy Clin Immunol* 2002;110:318-28.
- Gottlöber P, Gall H, Peter RU. Allergic contact dermatitis from natural latex. *Am J Contact Dermat* 2001;12:135-8.

Mannitol

Mannitol is a hexahydric alcohol closely related to the hexose sugars. It has been used in a variety of clinical situations (chemotherapy, cerebral edema) for its osmotic diuretic qualities.

■ Incidence

Very low. Fewer than 10 cases reported.

■ Risk factors

Atopy.

■ Clinical manifestations

- **General:** anaphylactic shock.
- **Cutaneous:** pruritus, urticaria with or without angioedema, periorbital edema.
- **Respiratory:** sneezing, bronchospasm, chest tightness.

Complications: extravasation, which causes swelling and multiple cutaneous bullous eruptions in the hand and forearm.

■ Diagnostic methods

Skin tests

Intradermal skin test reported positive at 1/100 dilution.

No serum *specific IgE assay* available.

In vitro histamine release assay positive in one patient with anaphylactic shock.

■ Mechanisms

Hyperosmolar solutes are capable of inducing non-cytotoxic basophil histamine release. Also, IgE-mediated mannitol hypersensitivity has been identified by *in vitro* histamine release assay.

■ Management

Avoidance.

References

Erickson BA, Yap RL, Pazona JF, et al. Mannitol extravation during partial nephrectomy leading to forearm compartment syndrome. *Int Braz J Urol* 2007;33:68-71.

Hegde VL, Venkatesh YP. Anaphylaxis to excipient mannitol: evidence for an immunoglobulin E-mediated mechanism. *Clin Exp Allergy* 2004; 34:1602-9.

Chang KA, Jawan B, Luk HN, et al. Bullous eruptions caused by extravasation of mannitol- a case report. *Acta Anaesthesiol Sin* 2001;39:195-8.

Schmid P, Wuthrich B. Peranaesthetic anaphylactoid shock due to mannitol. *Allergy* 1992; 47:61-2.

Findlay SR, Kagey-Sobotka A, Lichtenstein LM. *In vitro* basophil histamine release induced by mannitol in a patient with mannitol-induced anaphylactoid reaction. *J Allergy Clin Immunol* 1984;73:578-83.

Meperidine - pethidine

Narcotic analgesic frequently used for analgesia and general anesthesia (induction).

■ Incidence

Very low.

■ Clinical manifestations

- **General:** anaphylactic shock.
- **Respiratory:** cough, wheezing.
- **Cutaneous:** rash, localized flare reaction.

■ Diagnostic methods

Skin tests: immediate skin tests may be positive (do not exceed a concentration of 1/100,000).

Specific IgE assay: reports of positive assays in a few cases of anaphylaxis.

■ Mechanisms

IgE-mediated hypersensitivity.

Non-specific histamine release, meperidine being one of the strongest histamine releasers of all anaesthetic agents.

■ Management

Avoidance.

References

Flacke JW, Flacke W, Bloom BC, et al. Histamine release by 4 narcotics: a double blind study in humans. *Anesth Analg* 1987;66:23-30.

Levy JH, Rockoff MA. Anaphylaxis to meperidine. *Anesth. Analg* 1982;61: 301-3.

Waisbren BA. Hypersensitivity to meperidine. *JAMA* 1978;239:1395.

Methohexital

Methohexital is a barbiturate derivative used for brief surgical procedures and electroconvulsive therapy.

I Incidence

Reported incidence ranges from 1/7,000 to 1/23,000; 0.2% in dentistry. No deaths have been reported.

I Clinical manifestations

- **General:** rarely anaphylaxis.
- **Cutaneous:** pruritus, urticaria, rash, mucosal edema.
- **Others:** respiratory (bronchospasm), cardiovascular and digestive symptoms are unusual. Onset of symptoms is usually delayed for a few minutes after injection.

I Diagnostic methods

None.

I Mechanisms

Non-IgE-mediated.
Non-specific histamine release.

I Management

Avoidance.

References

- Hooten WM, Rasmussen KG Jr. Effects of general anesthetic agents in adults receiving electroconvulsive therapy: a systematic review. *J ECT* 2008;24:208-23.
- Ebo DG, Fisher MM, Hagendorens MM, et al. Anaphylaxis during anaesthesia: diagnostic approach. *Allergy* 2007;62:471-87.
- Fisher MM. The preoperative detection of risk of anaphylaxis during anaesthesia. *Anaesth Intensive Care* 2007;35:899-902.
- Liu LM, Liu PL, Moss J. Severe histamine-mediated reaction to rectally administered methohexital. *Anesthesiology* 1984;61:95-7.
- McDonald D. Methohexitone in dentistry. Scientific results of 4379 administrations. 5: complications. *Dent Anaesth Sedat* 1982;11:51-7.
- Harrison GR, Thompson ID. Adverse reaction to methohexitone and gallamine. *Anaesthesia* 1981;36:40-4.
- Driggs RL, O'Day RA. Acute allergic reaction associated with methohexital anesthesia: report of six cases. *J Oral Surg* 1972;30:906-9.

Midazolam

Midazolam hydrochloride is a short-acting imidazobenzodiazepine used in anesthesiology.

■ Incidence

Extremely rare.

Used intranasally in dental treatment.

Safe and effective for sedation of patients with mild and moderate asthma.

■ Clinical manifestations

- **General:** anaphylactic shock.
- **Cutaneous:** rash, pruritus, urticaria, angioedema.
- **Respiratory:** bronchospasm.

■ Diagnostic methods

Skin tests

Prick test with 1/10 dilution

Intradermal tests with dilutions 1/10,000 to 1/10

No midazolam-specific IgE assay

■ Mechanisms

Unknown.

■ Management

Avoidance.

References

- Uzun S, Dal D. Unexpected complications of intranasal midazolam premedication. *Paediatr Anaesth* 2007;17:817-8.
- McIlwain M, Primosch R, Bimstein E. Allergic reaction to intranasal HCL: a case report. *Pediatr Dent*. 2004;26:359-361.
- Kil N, Zhu JF, Van Wagnen C, et al. The effects of midazolam on pediatric patients with asthma. *Pediatr Dent* 2003;25:137-42.
- Yakel DL Jr, Whittaker SE, Elstad MR. Midazolam-induced angioedema and bronchoconstriction. *Crit Care Res* 1992;20:307-8.

Morphine

Morphine, historically the most important opioid, is widely used as an analgesic in various clinical situations.

■ Incidence

Extremely rare.

■ Clinical manifestations

• *General*

The clinical manifestations of anaphylaxis are classified into five grades of severity:

Grade I: mild, self-limiting reactions, e.g., isolated skin symptoms;

Grade II: moderate reactions quickly responding to therapy, e.g., hypotension, bronchospasm or multivisceral symptoms;

Grade III: severe reactions requiring prolonged treatment, e.g., anaphylactic shock;

Grade IV: cardiac and respiratory arrest;

Grade V: death.

• *Cutaneous*: erythema, pruritus, urticaria, facial flushing, hyperhidrosis, pseudoallergic anaphylactoid reactions, blisters, acute generalized exanthematous pustulosis.

• *Others*: occupational rhinitis, asthma and eczema.

■ Diagnostic methods

The value of skin prick testing in opiate-sensitive individuals is uncertain as opiates cause non-specific wheals by direct degranulation of mast cells.

Skin tests: With the concentration normally non-reactive in practice (10mg/ml)

Prick test: 1/10 (1mg/ml).

Intradermal skin test: 1/1000 (0.01mg/ml).

Dilution series is used starting with a 1/10,000 dilution and increasing the concentration up to the highest level that does not produce a reaction in non-allergic individuals.

Patch tests may be used to confirm the diagnosis in acute generalized exanthematous reactions.

Specific IgE: RIA with morphine-sepharose is positive in some cases.

High prevalence of sensitization to morphine (69%) in some countries, e.g., Norway compared to Sweden. One possible explanation is the unrestricted use of cough mixtures containing morphine derivatives in such countries.

Placebo-controlled challenge should be considered in particular situations.

■ Mechanisms

Non-specific histamine release by direct degranulation of mast cells; most reactions are not life-threatening and are frequently misinterpreted as IgE-mediated allergy.

IgE-mediated anaphylaxis: allergenic determinants identified encompass the N-methyl group and the cyclohexenyl ring with an hydroxyl at C6.

Type IV hypersensitivity is responsible for acute generalized exanthematous pustulosis.

■ Management

Avoidance.

Cross-reactivity of morphine with codeine and other narcotics might occur.

References

Kardaun SH, de Monchy JG. Acute generalized exanthematous pustulosis caused by morphine, confirmed by positive patch test and lymphocyte transformation test. J Am Acad Dermatol 2006;55:S21-3.

Hogen EAJ, van der Heide S, van den Brink W, et al. Contact allergy and respiratory/mucosal complaints from heroin (diacetylmorphine). Contact Dermatitis 2006;54:42-9.

Florvaag E, Johansson SG, Oman H, et al. Prevalence of IgE antibodies to morphine. Relation to the high and low incidences of NMBA anaphylaxis in Norway and Sweden, respectively. Acta Anaesthesiol Scand 2005;49:437-44.

Nasser SM, Ewan PW. Opiate-sensitivity: clinical characteristics and the role of skin prick testing. Clin Exp Allergy 2001;31:1014-20.

Muscle relaxants

Family of agents widely used in general anesthesia to achieve muscle relaxation.

Neuromuscular blocking agents (NMBAs): Suxamethonium, Vecuronium, Pancuronium, Rocuronium, Atracurium, Mivacurium, and Cisatracurium.

■ Incidence

Incidence of anaphylaxis is 1/6,500 anaesthetic episodes.

Incidence of anaphylactic shock is 1/10,000 general anesthetics.

Mortality rate is between 3 to 5%.

Muscle relaxants account for 55 to 60% of all allergic reactions occurring during general anesthesia.

■ Risk factors

Use of muscle relaxants with a “flexible chain”, e.g., suxamethonium.

Female gender (80% of cases).

Previous allergic reactions to muscle relaxants.

No involvement of previous anaesthetics, atopy, food allergy and allergies to drugs not related to anaesthesia.

Relation between pholcodine consumption, prevalence of IgE sensitization to suxamethonium and anaphylaxis to NMBAs

■ Clinical manifestations

• General

The clinical manifestations of anaphylaxis are classified into five grades of severity:

Grade I: mild, self-limiting reactions, e.g., isolated skin symptoms.

Grade II: moderate reaction quickly responding to therapy, e.g., hypotension, bronchospasm or multi-visceral symptoms.

Grade III: severe reactions requiring prolonged treatment, e.g., anaphylactic shock.

Grade IV: cardiac and respiratory arrest.

Grade V: death.

In 80 to 90% of cases, the reaction begins with the induction of general anaesthesia, 5 to 10 minutes after the drug has been injected.

• **Cutaneous:** flush in the neck and upper chest, erythema, urticaria with or without angioedema.

■ Diagnostic methods

Skin tests

Prick tests with commercially available concentrations of NMBAs, except for mivacurium and atracurium, which must be used at a 1:10 dilution.

For intradermal tests, a dilution series is used, starting with a 1:10,000 dilution and increasing the concentration up to the highest level that does not produce a reaction in non-allergic individuals

(100 µg/ml for suxamethonium, 200 µg/ml for pancuronium, 400 µg/ml for vecuronium, 100 µg/ml for rocuronium, 10 µg/ml for atracurium, 2 µg/ml for mivacurium, and 20 µg/ml for cisatracurium). When the skin test with one NMBA is positive, it is necessary to perform intradermal tests with other available NMBAs to determine whether cross-sensitization is present. Eighty-four percent of patients will show cross-sensitization to some NMBAs, but only 16% of them will react to all NMBAs.

Individuals can remain skin test-positive for up to 30 years.

Specific IgE:

Determination of serum IgE antibodies against NMBAs by ImmunoCAP or by other more sensitive methods, such as QAS-RIA (quaternary ammonium sepharose-radioimmunoassay) and PAPPC-RIA (p-aminophenylphosphoryl-choline-radioimmunoassay), can be done.

In vitro cellular assays are not sufficiently validated to be recommended for routine use

I Mechanisms

IgE-mediated anaphylaxis:

The epitope of NMBAs recognized by IgE antibodies is the quaternary or tertiary ammonium ion. Cross-sensitization between NMBAs is seen in most patients allergic to one NMBA. In addition, this cross-reactivity occurs most often between NMBAs of the same chemical group, for example, between aminosteroids (pancuronium, vecuronium, and rocuronium), between benzylisoquinones (atracurium, mivacurium, and cisatracurium), or between suxamethonium and other NMBAs. Several explanations could account for these non-systematic cross-reactions: 1) the epitope recognized by the IgE may not be strictly identical, and in some cases not only the quaternary ammonium but also the phenyl groups surrounding it may be involved; 2) the affinity between the IgE and the quaternary ammonium may differ from one NMBA to another; 3) the flexibility and the length of the chain linking the 2 quaternary ammonium ions may also play a triggering role in an allergic reaction. An NMBA with a rigid backbone between the two ammonium ions (e.g., pancuronium and vecuronium) appears to be less likely to initiate anaphylaxis than a flexible NMBA molecule such as suxamethonium.

Non-allergic anaphylaxis:

Chemically-mediated histamine release is far more likely to occur. It may be impossible to distinguish an IgE-mediated allergic event from a strictly chemically-mediated reaction. The symptoms in response to non-specific histamine release are generally less severe than when an IgE-mediated allergic reaction is involved.

I Management

There is actually no way to prevent primary sensitization to NMBAs. Anaphylactic reactions can occur in the absence of prior administration of an NMBA. Systematic screening tests in the general population are not advisable due to the poor positive predictive value of the tests.

Secondary prevention for patients with a history of an anaphylactic reaction to an NMBA is based on preoperative skin-tests with all NMBAs:

- If skin-tests are positive, do not use the offending muscle relaxant(s).
- If skin-tests are negative, the NMBA may be administered (in case of absolute necessity).

No preventive treatment can avoid anaphylactic reactions.

References

- Florvaag E, Johansson SGO, Öman H, et al. Pholcodine stimulates a dramatic increase of IgE in IgE-sensitized individuals. A pilot study. *Allergy* 2006;61:49-55.
- Mertes PM, Laxenaire MC, Lienhart A, et al. Reducing the risk of anaphylaxis during anaesthesia: guidelines for clinical practice (Article in French). *J Investig Allergol Clin Immunol*. 2005;15:91-101.
- Mertes PM, Laxenaire MC. Anaphylactic and anaphylactoid reactions occurring during anaesthesia in France. Seventh epidemiologic survey (January 2001-December 2002) (Article in French). *Ann Fr Anesth Reanim* 2004;23:1133-43.
- Olday J, Currie E, Drummond GB. The incidence of flushing on induction of anesthesia in patients who blush easily. *Anaesthesia* 2003;58:275-7.
- Guilloux L, Ricard-Blum S, Ville G, et al. A new radioimmunoassay using a commercially available solid support for the detection of IgE against muscle relaxants. *J Allergy Clin Immunol* 1992;90:153-9.
- Gueant JL, Mata E, Monin B, et al. Evaluation of a new reactive radioimmunoassay of serum specific IgE against muscle relaxant drugs. *Allergy* 1991;46:452-8.

Propanidid

Short-acting general anesthetic used especially for tooth extractions.

■ Incidence

Very high: 1 out of 500 to 1 out of 700 anesthetics.

Severe reactions: 0.007% to 0.13%.

■ Clinical manifestations

- **General:** anaphylactic shock.
- **Cutaneous:** various delayed reactions.
- **Respiratory:** bronchospasm.
- **Others:** nausea, vomiting, diarrhea.

■ Diagnostic methods

Complement assay at the time of the accident (difficult).

Blood histamine measurement at the time of the accident.

■ Mechanisms

Responsibility of solvent: cremophor E.L., which activates the classical or alternative complement pathway, releasing C3a anaphylatoxin and leukocyte migration.
Non-specific histamine release.

■ Management

Prohibited in many countries since 1983.

Avoidance.

References

Guerreo J, Trevilla J.M, de las Mulas, et al. Anaphylactic reaction to propanidid (Article in Spanish). *Rev. Esp. Anesthesiol Reanim.*, 1985;32(5):252-3.

Christmas J.P, Immune reaction to propanidid, *Anaesthesia*, 1984; 39: 470-3.

Propofol

Propofol (2-6 diisopropylphenol) is an alkyl phenol in a lipid vehicle (soybean oil, egg phosphatide, glycerol). It is a potent intravenous hypnotic agent which is widely used for the induction and maintenance of anesthesia and for sedation in intensive care units.

■ Incidence

<1% of peroperative anaphylactic reactions.

■ Risk factors

Previous drug allergy.

Association with atracurium.

■ Clinical manifestations

Remarkably safe profile

- **General:** anaphylactic shock.
- **Cutaneous:** urticaria, angioedema, erythematous rash.
- **Respiratory:** bronchospasm.
- **Others:** conjunctival chemosis.

Side effects:

Hypotension; dose dependence is the most frequent complication.

Severe metabolic acidosis and circulatory collapse ("propofol syndrome") can be caused by high doses of propofol (rare).

■ Diagnostic methods

Skin tests

Prick test: undiluted (10mg/ml)

Intradermal skin test: from 1/1000 to 1/10(maximal concentration 1000µg/ml)

Specific IgE assay

Hydrophobic IgE antibodies have been detected by RIA using either phenyl-Sepharose or octyl-Sepharose as the reactive phase positive.

In vitro histamine release test

■ Mechanisms

An IgE-mediated reaction in most cases. Propofol contains 2 isopropyl groups which may act as the epitopes. One report suggested that this drug should be omitted in patients with allergy to egg or soy, due to lecithins which are present in the propofol vehicle. However, up to now, there is no convincing evidence to support allergy to egg or soy as a risk factor to propofol reactions.

Lecithins contained in the propofol emulsion share quaternary ammonium ions which can react with anti-muscle relaxant IgE antibodies. Patients with propofol allergy can have clinically irrelevant

IgE antibodies against muscle relaxants.

Non-specific histamine release: propofol can induce concentration-dependant histamine release from human lung mast cells and at high doses can elicit bronchospasm.

I Management

Avoidance.

By prudence, avoid using propofol in patients with a history of egg or soy allergy. Do not use atracurium with propofol (high frequency of anaphylactoid reactions).

References

Marik PE. Propofol: therapeutic indications and side-effects. *Curr Pharm Des* 2004;10:3639-49.

Hofer KN, Mc Carthy MW, Buch ML, et al. Possible anaphylaxis after propofol in a child with food allergy. *Ann Pharmacother* 2003;37:398-401.

Gueant JL, Aimone-Gastin I, Namour F, et al. Diagnosis and pathogenesis of the anaphylactic and anaphylactoid reactions to anaesthetics. *Clinical and Experimental Allergy* 1998;28:65-70.

Marone G, Stellato C, Mastronardi P, et al. Mechanisms of activation of human mast cell and basophils by general anesthetic drugs. *Ann Fr Anesth Reanim* 1993;12:116-25.

Laxenaire M.C, Mata-Bermejo E, Moneret-Vautrin D.A, et al. Life-threatening anaphylactoid reactions to propofol (Diprivan*). *Anesthesiology* 1992;77:275-80.

Thiopental

Barbiturate anesthetic, less frequently used than before. Used mainly in neurosurgery and reanimation.

■ Incidence

1/23,000 to 1/29,000 administrations.
Death occurs rarely.

■ Risk factors

Patients allergic to barbiturates.
Previous exposure (60 to 94%).
Female gender (gender ratio 3/1).

■ Clinical manifestations

• General

The clinical manifestations of anaphylaxis are classified into five grades of severity:

Grade I: mild, self-limiting reactions, e.g., isolated skin symptoms;

Grade II: moderate reactions quickly responding to therapy, e.g., hypotension, bronchospasm or multivisceral symptoms;

Grade III: severe reactions requiring prolonged treatment, e.g., anaphylactic shock;

Grade IV: cardiac and respiratory arrest;

Grade V: death.

• **Cutaneous:** flush (neck and upper chest), erythema, urticaria with or without angioedema, fixed drug eruption.

■ Diagnostic methods

Skin tests: With the concentration normally non-reactive in practice (25mg/ml).

Prick test: undiluted (25mg/ml)

Intradermal skin test: 1/10 (2.5mg/ml)

Serial dilutions starting with a 1/10,000 dilution and increasing the dilution up to the highest level that does not produce a reaction in non-allergic individuals.

Open test on previous fixed drug eruption lesions with lecture from 30 minutes to 24 hours.

Specific IgE:

Detection of thiopentone-reactive IgE antibodies by the ImmunoAssay method, which specificity is confirmed by hapten inhibition studies. However, technical difficulties including non-specific binding, the poor solubility of thiopental at physiologic pH and the low sensitivity of the test, make the use of ImmunoAssay in clinical practice inefficient.

At high pH, binding of thiopental to the immunoabsorbent material can generate substituted ammonium ions that are normally internalized within the thiopentone molecule. sIgE against quaternary ammonium in subject sensitive to neuromuscular blockers agents can bind these substituted ammonium ions and simulate sensitivity to thiopentone.

I Mechanisms

IgE-mediated reaction: Two different allergenic determinants have been identified: pentyl and ethyl groups attached to position 5 on the pyrimidine ring nucleus and the secondary region of the ring, encompassing and including the attached hetero atom. Determinants involving the ring nitrogens in the pyrimidine nucleus can demonstrate cross-reactivity in vitro with sera from patients allergic to muscle relaxants.

Non-specific histamine-releasing effects are observed with high concentrations of thiopental.

I Management

Avoidance.

References

- Olday J, Currie E, Drummond GB. *The incidence of flushing on induction of anesthesia in patients who blush easily.* *Anaesthesia* 2003;58:275-7.
- Gueant JL, Aimone-Gastin I, Namour F, et al. *Diagnosis and pathogenesis of the anaphylactic and anaphylactoid reactions to anaesthetics.* *Clin Exp Allergy* 1998;28(supp 4):65-70.
- Bremang JA, Halasi S. *Fixed drug eruption associated with anaesthesia.* *Can J Anaesth* 1995;42:628-30.
- Binkley K, Cheema A, Sussman G, et al. *Generalized allergic reactions during anesthesia.* *J Allergy Clin Immunol* 1992;89:768-74.
- Laxenaire MC, Moneret-Vautrin DA, Widmer S, et al. *Anesthetics responsible for anaphylactic shock. A French multicenter study (Article in French).* *Ann Fr Anesth Reanim* 1990;9:501-6.
- Alanto K, Stubb S, Reitamo S. *Topical provocation of fixed drug eruption.* *Br J Dermatol* 1987;116:561-7.

II

ANALGESICS AND ANTI-INFLAMMATORY DRUGS



Acetaminophen (paracetamol)

Widely used analgesic and antipyretic

■ Incidence

Uncommon in patients who are not sensitive to NSAIDs.

Pseudoallergic reactions to acetaminophen are reported to occur in 5.3% to 40% of NSAID-sensitive patients.

Allergy to acetaminophen alone but not to other NSAIDs is exceptional.

■ Clinical manifestations

- **General:** anaphylactic shock.

- **Cutaneous:** urticaria and angioedema are the most frequent cutaneous reactions.

Other cutaneous manifestations: erythema multiforme, toxic epidermal necrolysis, acute generalized exanthematous pustulosis, fixed drug eruption, non-pigmented fixed drug eruption, purpura (with immune thrombocytopenia, pigmented purpuric dermatosis, Henoch-Schönlein purpura), delayed hypersensitivity rash.

- **Respiratory:** bronchospasm.

- **ENT:** rhinoconjunctivitis.

■ Diagnostic methods

Skin tests

Immediate skin test responses have been reported in a small number of patients (prick tests; intradermal tests at 100 mg/ml) but are negative in most patients.

Prick tests and intradermal tests are used in urticaria and angioedema with progressive dilutions (1/10,000 up to undiluted solution). Reaction is immediate (20 minutes) and delayed (24 hours).

Patch tests (10% in pet). They are performed on affected and unaffected skin in patients with a fixed drug eruption.

Specific IgE assay: one positive result reported in a patient with generalized urticaria.

Oral challenge test: increasing doses (50 mg, 100 mg, 250 mg, 500 mg, 750 mg) at 30 minutes intervals in adults. Begin with 1 mg in children.

■ Mechanisms

Acetaminophen is a weak COX-1 and COX-2 inhibitor. Reactions in NSAID-sensitive patients are observed with high doses of acetaminophen but not with low doses.

Acetaminophen could also inhibit cyclooxygenases -2b and -3.

Type I hypersensitivity to acetaminophen can occur but it is rare.

I Management

Acetaminophen is usually well tolerated in NSAID-sensitive patients when low doses are used (< 600 mg).

High doses (> 1000 mg) should be avoided in NSAID-sensitive patients. Oral provocation challenge may be done to demonstrate tolerance to the drug.

References

- Sanchez-Borges M, Capriles-Hulett A, Caballero-Fonseca F. Hypersensitivity reactions to weak COX inhibitors. Allergy Clin Immunol Int 2005;17:58-63.*
- Boussetta K, Ponvert C, Karila C, et al. Hypersensitivity reactions to paracetamol in children: a study of 25 cases. Allergy 2005;60:1174-7.*
- Oh SW, Lew W. Erythema multiforme induced by acetaminophen: a recurrence at distant sites following patch tests. Contact. Dermatitis 2005;53:56-7.*
- Galindo PA, Borja J, Feo F, et al. Nonpigmented fixed drug eruption caused by paracetamol. J Investig Allergol Clin Immunol 1999;9:399-400.*
- de Coninck AL, van Strubarg AS, Pipeleers-Marichal MA et al. Acute generalized exanthematous pustulosis induced by paracetamol. A case with severe hemodynamic disturbances. Dermatology 1996;193:338-41.*
- Settipane RA, Schrank PJ, Simon RA et al. Prevalence of cross sensitivity with acetaminophen in aspirin-sensitive asthmatic subjects. J Allergy Clin Immunol 1995;96:480-5.*

Aspirin and non steroid anti-inflammatory drugs (NSAIDs)

Aspirin (ASA) and NSAIDs are drugs widely used in the field of pain and inflammatory disorders.

■ Incidence

Aspirin-induced asthma:

- in a general population: 0.5 to 2.5%
- in asthmatic adults: 4.3 to 11%
- in patients with chronic sinusitis and nasal polyps: 21%

Aspirin-induced urticaria:

- in chronic urticaria: 20 to 40%
- rhinitis and asthma: 1.5%
- normal individuals: 0.3%

■ Risk factors

There is a family history of aspirin hypersensitivity in 1 to 6% of cases.

Female sex: 2.5 times more frequent.

Atopy: localized periorbital edema.

■ Clinical manifestations

- **General:** anaphylactoid reaction (due to zomepirac, tolmetine, diclofenac, ketorolac).
- **Cutaneous:** pruritus, acute urticaria and angioedema, exacerbation of a chronic urticaria, isolated periorbital edema (younger subjects, atopy, intolerance to multiple NSAIDs not structurally related), maculopapular rash, purpura (phenylbutazone, salicylates), fixed drug eruption, erythema multiforme and toxic epidermal necrolysis (oxicams +++), acute generalized exanthematous pustulosis, DRESS syndrome, photosensitivity (oxicams +++), vasculitis, embolia cutis medicamentosa (Nicolau syndrome with intramuscular injections; often with diclofenac), erythema nodosum, Sweet's syndrome, bullous pemphigoid, linear IgA bullous dermatosis, lupus erythematosus, dermatomyositis.
- **Respiratory:** rhinoconjunctivitis/asthma: chronic eosinophilic rhinosinusitis with or without nasal polyps and secondary purulent infection of the paranasal sinuses; then asthma, usually severe and corticoid dependant. Classic triad: rhinitis with nasal polyps, asthma and ASA sensitivity. Hypersensitivity pneumonitis (fever, cough, pulmonary infiltrates with eosinophilia): most reactions occur in patients with inflammatory arthritis. Drugs involved: naproxen, sulindac, ibuprofen, azapropazone, indomethacin, piroxicam, phenylbutazone, oxyphenylbutazone, diclofenac, fenbrufen.
- **Haematological:** eosinophilia, cytopenia.
- **Other adverse effects:** a new triad - "atopy, NSAID sensitivity and oral anaphylaxis from aeroallergens (mites)".

I Diagnostic methods

Skin tests

Usually ineffective and negative; one case report of a positive skin test with aspirin polylysine (2 mg/ ml) in a patient with urticaria.

Patch tests with a standardized concentration: acetylsalicylic acid (10% in pet), diclofenac sodium salt (1% in pet), piroxicam (1% in pet), ibuprofen (10% in pet).

Specific IgE assay (controversial)

IgE antibodies against platelet antigens have been detected; specific antibodies to salicyloyl and O-methylsalicyloyl have also been detected.

Controlled oral challenges: gold standard in the diagnostic of NSAID hypersensitivity.

Urticaria (aspirin).

Schedule: Day 1: placebo; Day 2: 100 mg; 200 mg; Day 3: 325 mg; Day 4: 650 mg.

Urticarial responses are measured by skin scores recorded every 2 hours.

Rhinosinusitis/asthma.

Oral challenge (single blind or double blind)

	Day 1	Day 2	Day 3
08h00	placebo	ASA 3 or 30 mg	150 mg
11h00	placebo	ASA 60 mg	325 mg
14h00	placebo	ASA 100 mg	650 mg

Classical response (86%): FEV1 decreases > 20% + naso-ocular reaction.

Asthma only: FEV1 decreases \geq 20%

Rhinitis: naso-ocular reaction only.

Mild asthma: FEV1 decreases 15 to 20% combined with naso-ocular reaction.

No reaction.

Bronchial inhalation challenge with lysine-acetylsalicylate conjugate: available as a powder, soluble in water (increasing doses: 11.25 mg, 22.5 mg, 45 mg, 90 mg, 180 mg, 360 mg). No severe bronchoconstriction. Easier to perform.

Nasal aspirin challenge with lysine-ASA or ketorolac solutions are safer, cheaper, and less time consuming than bronchial challenge. Objective measurements: rhinomanometry, acoustic rhinomanometry, peak nasal inspiratory flow.

Single-blind, placebo-controlled nasal challenge with other drugs:

Acetaminophen (paracetamol): 100 mg, 250 mg, 500 mg, at 60 minute intervals.

Isonixin: 100 mg, 400 mg, at 60 minute intervals.
Salsalate: 500 mg, 1000 mg at 60 minute intervals.
Diflunisal: 100 mg, 500 mg, at 60 minute intervals.
Mefenamic acid: 50 mg, 125 mg, 250 mg at 60 minute intervals.
Clonixin: 50 mg, 125 mg at 60 minute intervals.
Diclofenac: 25 mg, 50 mg at 120 minute intervals.
Piroxicam: 10 mg, 20 mg at 120 minute intervals.
Ketoprofen: 10 mg, 25 mg, 50 mg at 120 minute intervals.
Celecoxib: 50 mg, 100 mg, 200 mg at 60 minute intervals.
Meloxicam: 7.5 mg, 15 mg at 60 minute intervals.
Ibuprofen: 50 mg, 150 mg, 250 mg, 600 mg at 60 minute intervals.
Dipyrrone: 10 mg, 50 mg, 125 mg, 250 mg, 575 mg at 60 minute intervals.

I Mechanisms

Leukotriene C₄, histamine and tryptase are released from cells in ASA-sensitive asthmatics following ASA challenge.

Over-production of leukotriene is due to marked eosinophilic infiltration of the mucosae. Administration of aspirin shifts the metabolism of arachidonic acid towards the 5-lipoxygenase pathway with synthesis of leukotriene sulfidopeptides (LTC₄, LTD₄, LTE₄) which are potent bronchoconstrictors.

Metabolites of arachidonic acid (LTC₄, LTD₄, LTE₄) may be detected in urine, bronchial and nasal fluids following aspirin challenge.

Platelets have been implicated in the pathogenesis of asthma intolerance, since they release free O₂ radicals and cytotoxic mediators in response to NSAIDs. Platelets from ASA-sensitive patients become cytotoxic in the presence of ASA.

Studies performed in patients suffering from asthma due to aspirin intolerance have demonstrated higher levels of IL-5, an elevated eosinophil count, and higher levels of ECP compared to aspirin-tolerant asthmatic patients.

Sensitivity to aspirin-like drugs in ASA-sensitive patients:

- prostaglandin synthetase inhibitors: indomethacin 100%, fenoprofen 100%, naproxen 100%, zomepirac 80 to 100%, ibuprofen 97%, mefenamic acid 60%, phenylbutazone 42%
- non-prostaglandin synthetase inhibitors: sodium salicylate < 1%, choline salicylate < 1%, salicylate < 1%, propoxyphene < 1%

I Management

Urticaria

Avoidance of ASA/NSAIDs.

Long-term desensitization does not appear feasible for patients with ASA/NSAID-induced urticaria.

Hypersensitivity pneumonitis

Avoidance.

Use of systemic corticosteroids.

Rhinosinusitis/asthma

Avoidance of all NSAIDs.

Asthmatics with normal sinus X-rays or CT scans of the sinuses and asthmatics with clear evidence of non-NSAID IgE-mediated allergies are at low risk of ASA sensitivity.

Desensitization:

ASA desensitization may be considered in patients with:

- uncontrolled respiratory inflammation despite appropriate treatment (local and systemic corticosteroids),
- patients requiring frequent sinus surgery,
- patients with arthritis or recurrent arterial thromboembolic diseases, and
- patients with cardiovascular disease and mandatory dual antiplatelet therapy.

Aspirin desensitization is accompanied by reduced aspirin-induced production of sulfidopeptide leukotrienes (LTE₄).

Do not administer topical ophthalmic ketorolac, flurbiprofen, suprofen or diclofenac to asthmatic patients with ASA sensitivity because of the risk of bronchospasm.

Less than 2% of asthmatics are sensitive to both aspirin and acetaminophen.

More than 91% of aspirin sensitive patients tolerate meloxicam.

More than 96% of aspirin sensitive patients tolerate nimesulide.

More than 83% of aspirin sensitive patients tolerate 2 g of nabumetone.

More than 94% of aspirin sensitive patients tolerate 1 g of nabumetone.

More than 88% of aspirin sensitive patients tolerate celecoxib.

References

Mockenhaupt M, Viboud C, Dunant A, et al. Stevens-Johnson syndrome and toxic epidermal necrolysis : assessment of medication risks with emphasis on recently marketed drugs The EuroSCAR-study. *J Invest Dermatol* 2008;128:35-4.

Szczeklik A, Nizankowska-Mogilnicka E, Sanak M. Hypersensitivity to aspirin and other NSAIDs: mechanisms, clinical presentation and management. In Pichler WJ (ed): *Drug Hypersensitivity Basel*, Karger, 2007, pp 340-349

Quirarte J, Blanco C, Delgado J, et al. Challenge-based clinical patterns of 223 Spanish patients with nonsteroidal anti-inflammatory drug-induced reaction. *J Investig Allergol Clin Immunol* 2007;17:182-8.

Page NA, Schroeder WS. Rapid desensitization protocols for patients with cardiovascular aspirin hypersensitivity in an era of dual antiplatelet therapy. *Ann Pharmacother* 2007;41:61-7.

Oliva A, De Giorgio F, Arena V. Death due to anaphylactic shock secondary to intravenous self-injection of Toradol: a case report and review of the literature. *Clin Toxicol (Phila)* 2007;45:709-13.

Cohn JR. Aspirin challenge and desensitization for aspirin-exacerbated respiratory disease: a practice paper. *Ann Allergy Asthma Immunol* 2007;99:196.

Jenneck C, Juergens U, Buecheler M, et al. Pathogenesis, diagnosis and treatment of aspirin intolerance. *Ann Allergy Asthma Immunol* 2007;99:13-21.

Kong JS, Teuber SS, Gershwin ME. Aspirin and non steroidal antiinflammatory drug hypersensitivity. *Clin Rev Allergy Immunol* 2007;32:97-110.

Pfaar O, Klimek L. Eicosanoids, aspirin-intolerance and the upper airways-- current standards and recent improvements of the desensitization therapy. *J Physiol Pharmacol* 2006;57:5-13.

Vinas Domingo M, Castillo Marchuet MJ, Dordal Culla MT, et al. Meloxicam tolerance in hypersensitivity to nonsteroidal anti-inflammatory drugs *J Investig Allergol Clin Immunol* 2006;16:364-6.

Coxibs

- ▶ Coxibs are selective cyclooxygenase (COX)-2 inhibitor NSAIDs. Some of them have been withdrawn from the market because of adverse cardiovascular events.
- ▶ Celecoxib, rofecoxib, etoricoxib.

■ Incidence

Anaphylactic shock (5 cases due to celecoxib have been published).

Urticaria: 1/100 to 1/1,000.

Most patients with cutaneous NSAID hypersensitivity tolerate coxibs. Urticaria and angioedema due to coxibs are mainly observed in subjects cross-reactive to classic NSAIDs. Reactions to coxibs may occur during the first exposure.

Stevens-Johnson's syndrome and toxic epidermal necrolysis, both reactions severe and sometimes fatal, occur during the first month of treatment:

- Valdecoxib - 49 per million person-year.
- Celecoxib - 6 per million person-year.
- Rofecoxib - 3 per million person-year.

Asthma: occurs in < 1/10,000 persons.

■ Clinical manifestations

- **General:** anaphylactic shock.
- **Cutaneous:** pruritus, acute urticaria and angioedema, aggravation of chronic urticaria, maculopapular rash (frequently association to facial edema and erythema), facial edema, fixed drug eruption, erythema multiforme, Stevens-Johnson syndrome, toxic epidermal necrolysis, acute generalized exanthematous pustulosis, DRESS syndrome, exfoliative dermatitis, photosensitivity, allergic vasculitis (one fatal case with celecoxib), Sweet's syndrome, lupus erythematosus.
- **Respiratory:** asthma.

■ Diagnostic methods

Skin tests

Patch-tests with celecoxib (1 to 10% in pet); frequent false positive reactions.

Controlled oral challenge.

■ Mechanisms

Unknown

Coxibs do not trigger cystenyl leukotriene biosynthesis in aspirin-sensitive asthmatics.

A cross-reaction between celecoxib and sulphamethoxazole has been observed but not confirmed in subsequent publications (there is no aromatic group in celecoxib).

I Management

Avoidance.

One case with selective allergy to celecoxib and no allergy to rofecoxib or sulphamethoxazole.

One case with diclofenac tolerance after hypersensitivity to celecoxib.

References

Sanchez-Borges M, Capriles-Huette A, Caballero-Fonseca F. Cutaneous hypersensitivity reactions to inhibitors of cyclooxygenase-2. Allergy Clin Immunol Int-J. World Allergy Org J 2007;19: 44-9.

Donning A, Jacobsen J, Sorensen HT, et al. Risk of hospitalization for angio-oedema among users of newer COX-2 selective inhibitors and other non steroidal anti-inflammatory drugs. Br J Clin Pharmacol 2006;62:496-501.

La Grenade L, Lee L, Weaver J, et al. Comparison of reporting of Stevens-Johnson's syndrome and toxic epidermal necrolysis in association with selective COX-2 inhibitors. Drug Saf 2005;28:917-24.

Mommens V, Just N, Ngo MT, et al. Intolerance to non steroidal antiinflammatory drugs including a cyclooxygenase 2 specific inhibitor (Article in French). Rev Fr Allergol Immunol Clin 2003;43:393-6.

Murr D, Bocquet H, Lelouet H, et al. Adverse cutaneous reaction to celecoxib: 6 cases (Article in French). Ann Dermatol Venereol 2003;130:519-21.

Marques S, Milpied B, Foulc P, et al. Severe cutaneous drug reactions to celecoxib (Celebrex) – (Article in French). Ann Dermatol Venereol 2003;130:1051-5.

Fye KH, Croxley E, Berger TG, et al. Celecoxib-induced Sweet's syndrome. J Am Acad Dermatol 2001;45:300-2.

Topical NSAIDs

▶ **Group 1:** NSAIDs in the propionic group, derivatives of arylpropionic acid (benzophenone structure containing two benzene rings connected by a cetone function), such as ketoprofene.

■ Incidence

Up until 1995, the phenothiazines were the principal photosensitizers, but they have since been replaced by ketophene. A study conducted by the French National Pharmacovigilence Group listed nearly 770 secondary cutaneous adverse effects due to this drug between 1996 and 2000.

■ Clinical manifestations

Contact eczema, sometimes with photoaggravation but more often with contact photoallergic reactions.

Most of the populations affected are young. The secondary effects are most frequent in summer months, due to the more intense solar exposure. The lesions are localized to the zone of application but they often extend beyond this area. They appear with different delays (from 1 to 2-3 months), sometimes after having stopped the topical application, due to continued solar exposure. The photoallergic reactions are sometimes severe. Concomitant use of other topical or systemic NSAIDs or fibrates is an aggravating factor. They disappear progressively after elimination of the photoallergen. They are little influenced by topical or systemic corticosteroids. The lesions can persist for several weeks, even months, with transient reactivation upon exposure to light.

■ Diagnostic methods

Skin tests

Patch tests (1% in pet) but especially photopatch testing, with UVA irradiation at 5 joules/cm². Persistent and recurrent photosensitization requires an allergy workup and a photobiological investigation.

■ Mechanisms

Unknown. It appears that the benzophenone structure contained in ketoprofene is the most important factor in the induction of photoallergy. Investigation carried out in guinea pigs and mice seems to point a photoallergic rather than a phototoxic mechanism. In these animals, the lesions are reproducible and the skin appears to be a reservoir zone of ketoprofene. The ketoprofene molecule combined with UVA activates Langerhans cells, favoring stimulation of keratinocytes and the production of cytokines.

■ Cross-reactions and avoidance

Cross-reactions are observed with molecules having a benzophenone structure (thiopene-phenylacetone structure), fenofibrate and oxybenzone.

In case of contact photoallergy to ketoprofene: topical and oral ketoprofene, tiaprofenic acid (however, the other NSAIDs in the arylpionic family can be used), fenofibrate and topical drugs containing benzophenones (particularly oxybenzone and mexenone which are present in sun screen and anti-aging creams) are contra-indicated.

Moreover, co-sensitization between ketoprofene and Fragrance mix occurs frequently. The presence

of the aldehyde function in the ketoprofen molecule explains the crossed sensitization with Fragrance mix, because it contains cinnamic aldehyde.

References

- Devleeschouwer V, Roelandts R, Garmyn M, et al. Allergic and photo allergic contact dermatitis from ketoprofen: results of (photo) patch testing and follow-up of 42 patients. *Contact Dermatitis*. 2008;58:159-166.
- Atarashi K, Kabashima K, Akiyama K, et al. Stimulation of Langerhans cells with ketoprofen plus UVA in murine photocontact dermatitis to ketoprofen. *J Dermatol Sci* 2007;47:151-9.
- Durieu C, Marguery MC, Giorano-Labadie F, et al. Photoaggravated contact allergy and contact photoallergy caused by ketoprofen: 19 cases (Article in French). *Ann Dermatol Venereol* 2001;125:1020-4.
- Nakazawa T, Shino T, Chikamatsu N, et al. Study on the mechanism of photosensitive dermatitis caused by ketoprofen in the guinea pig. *Arch Toxicol* 2006;80:442-8.

► **Group 2:** NSAIDs which are derivatives of phenylacetic acid in the arylcarboxylic group, as diclofenac

I Presentations

- gel containing 1% diclofenac, used as an anti-inflammatory topical treatment
- gel containing 3% diclofenac, used as a topical treatment of actinic keratosis
- ophthalmic solution containing 0.1% diclofenac

I Cutaneous manifestations

Applications site reactions: pruritus, paresthesia, erythema, vesiculobullous eruptions
Contact dermatitis
Photoallergic contact dermatitis
Maculopapular rash

I Diagnostic methods

Patch test with Diclofenac sodium salt (1 % in pet)

References

- Patel MJ, Ulrich C, Forschner T. Genetically determined susceptibility to cox-2 inhibitors: a report of exaggerated responders to diclofenac 3% gel in the treatment of actinic keratoses. *Br J Dermatol* 2007;156 suppl 3:57-61.
- Kowalzik L, Ziegler H. Photoallergic contact dermatitis from topical diclofenac in Solaraze gel. *Contact Dermatitis* 2006;54:348-9.

Pyrazoline drugs and pyrazolones

- ▶ Analgesic and antipyretic drugs with poor anti-inflammatory action.
- ▶ Aminopyrine, antipyrine, apazone, bumazidon, chlormezanone, dipyrone, feprazone, nifedipine, oxyphenbutazone, phenylbutazone, sulfinpyrazone and suxibuzone.

■ Incidence

Metamizol: cutaneous reactions in 0.13% to 2.4% of patients.

■ Risk factor

HLA-DQ7/DR11

■ Clinical manifestations

- **General:** anaphylactic shock.
- **Cutaneous:** pruritus, urticaria, angioedema, maculopapular exanthema, fixed drug eruption, erythema multiforme, toxic epidermal necrolysis, vasculitis, purpuric rash (with thrombocytopenia), allergic contact dermatitis, and photosensitivity (rare).
- **Respiratory:** bronchospasm (ASA triad)

■ Diagnostic methods

Skin tests

Prick and intradermal tests (1/1000 to 1/100) are positive in most patients with anaphylaxis or urticaria (mainly dipyrone, antipyrine, aminopyrine, oxyphenbutazone and propyphenazone).

Specific IgE assay

Low sensitivity of in vitro assays. Best results when ELISA is used with the drug coupled to HSA (positive results in 31/53 patients with immediate-type adverse reactions).

■ Mechanisms

IgE-mediated hypersensitivity (anaphylaxis, urticaria); cross-reactivity between pyrazolones may exist.

Intolerance: inhibition of the cyclooxygenase pathway with the other NSAIDs (asthma, chronic urticaria).

■ Management

In patients reporting a reaction exclusively to a pyrazolone, skin tests should be performed. If positive, this confirms an immunological mechanism and excludes cross-reactivity with other classes of NSAIDs. If negative, a tolerance test is advisable to provide a safe alternative (nimesulide, acetaminophen or a selective COX-2 inhibitor).

References

- Campi P, Manfredi M, Severino M. IgE-mediated allergy to pyrazolones, quinolones and other non beta-lactam antibiotics. In Pichler WJ (ed): *Drug Hypersensitivity*, Basel Karger 2007, pp 216-32
- Himly M, Jahn-Schmid B, Pittertschatscher K, et al. IgE-mediated immediate type hypersensitivity to the pyrazolone drug propyphenazone. *J Allergy Clin Immunol* 2003;111:882-8.
- Chen W, Hsieh FS. Dimorphic exanthema manifested as reticular maculopapular exanthema and erythema multiforme major associated with pyrazolone derivated. *Eur J Dermatol* 2002;12:488-490.
- Kowalski ML, Bienkiewicz B, Woszczek G, et al. Diagnosis of pyrazolone drug sensitivity : clinical history versus skin testing and in vitro testing. *Allergy Asthma Proc* 1999;20:347-52.
- Voigtlander V. Adverse dermatological reaction to pyrazolones. *Agents Actions Suppl* 1986;19:303-11.
- Szczeklik A. Analgesics, allergy and asthma. *Drugs* 1986;32:148-63.

III

ANTIBIOTICS AND ANTIPARASITE DRUGS, ANTIVIRAL AND ANTIFUNGAL DRUGS

1• ANTIBIOTICS AND ANTIPARASITE DRUGS

2• ANTIVIRAL DRUGS AND ANTIFUNGAL DRUGS

1• ANTIBIOTICS AND ANTIPARASITE DRUGS

Aminoglycosides

Aminoglycosides are broad-based heterosides with a broad-spectrum antibiotic action.

Streptidine group:

Streptomycin, dihydrostreptomycin, hydroxystreptomycin, manosidostreptomycin.

Streptomycin is a complex chemical substance, being composed of a central hexose (streptidine) linked to an amine-substituted disaccharide. Widely used in the past (tuberculosis), its use has declined drastically but is now routinely added to cell culture media (PHA-LAK) and to Ham's F-10 medium, which is used for *in vitro* fertilization.

Desoxystreptamine group:

1,3 substitution (trisaccharide): kanamycin, amikacin, gentamicin, tobramycin, sisomicin, netilmicin.

1,2 substitution (tetrasaccharide): paramomycin, neomycin.

I Incidence

High for neomycin and streptomycin: >2% of treatments.

Occasional for gentamicin and amikacin: 0.1 to 2% of treatments.

Uncommon for kanamycin: 0.1 to 0.5% of treatments.

I Clinical manifestations

• **General:** anaphylactic shock, fever (11% with long-term streptomycin), serum sickness.

• **Cutaneous:**

Topical use in particular with neomycin: contact eczema, especially in patients with leg ulcers, atopic eczema, chronic otitis or chronic conjunctivitis.

The combination of antibiotics and corticosteroids can modify the appearance of the lesions and is a source of delayed diagnosis.

Occupational eczema occurs in health care personnel and veterinarians.

The principal danger involving contact sensitization is the onset of eczema during systemic administration of these antibiotics, where they act as internal or endogenous allergen. This reaction can consist of reactivation of eczema which appears at a site previously affected or at the site of a previously positive patch test.

Other cutaneous reactions:

The onset of generalized eczema, or dyshidrotic eczema.

Urticaria-like reactions (systemic or contact), (maculopapular) rash, or erythroderma can occur.

Because of the risk of systemic administration, the tendency is to limit these topical antibiotics.

Cutaneous reactions with streptomycin:

Rash, urticaria, contact dermatitis (systemic use) and, less frequently, Stevens-Johnson syndrome, toxic epidermal necrolysis.

• **Others:**

Haematological: eosinophilia, haemolytic anemia

Pyrogenic reaction

I Diagnostic methods

Skin tests: none validated

Positive skin tests have been observed with tobramycin, gentamicin, framycetin, and streptomycin.

Patch-tests:

Neomycin sulfate at 20% in pet

Kanamycin sulfate at 10% in pet

Gentamycin sulfate at 20% in pet

Framycetin sulfate at 20% in pet

Streptomycin at 20% in pet

The tests are read at 72 and 96 hours since delayed positive reactions may occur.

Positive patch test with neomycin:

In a large series in which the frequency of positive patch tests was analyzed, the percentage of positive tests with neomycin varied from 2.5 to 3.6%.

In populations at risk (e.g., patients with leg ulcers), the percentage of positive tests varies from 9 to 15%.

Specific serum IgE:

No evidence of serum IgE to aminoglycosides

Antistreptomycin IgG antibodies in association with hemolytic anemia (direct and indirect Coombs)

Anti-erythrocyte antibodies (neomycin, gentamycin, kanamycin).

I Mechanisms

IgE-mediated hypersensitivity is unusual.

Cell-mediated delayed hypersensitivity for contact dermatitis (neomycin); neomycin is the antibiotic with the highest contact sensitizing power. Sensitization tends to occur on damaged skin (leg ulcers) and with long-term application.

For the pyrogenic reaction, the following hypothesis was proposed: that gentamycin administration in a single daily dose results in higher peak tissue concentrations, marked bacteriolysis with endotoxin release and consequent endotoxin-mediated host febrile responses.

I Management

Avoidance. Cross-reactivity between neomycin and framycetin, kanamycin, gentamycin and tobramycin approaches 50% or more; between neomycin and sisomycin and amikacin it is 20%; and between neomycin and netilmycin and streptomycin it is 1 to 5%.

It appears, however, preferable to avoid all aminoglycoside antibiotics in individuals sensitized to neomycin.

Desensitization:

Tobramycin: escalating doses of inhaled tobramycin on once-a-day regimen.

Streptomycin: desensitization (3 hours) beginning with 1 mg intravenously.

References

- Menezes de Padua CA, Schnuch A, Lessmann H, et al. Contact allergy to neomycin sulphate: results of a multi-factorial analysis. *Pharmacoepidemiol Drug Saf* 2005;14:725-33.
- Hmouda H, Laouani-Kehrid C, Nejib Karaoui M, et al. A rare cause of streptomycin-induced toxic epidermal necrolysis in a patient with tuberculosis: a therapeutic dilemma. *Ann Pharmacother* 2005;39:165-8.
- Schulze S, Wollina U. Gentamycin-induced anaphylaxis. *Allergy* 2003;58:88-9.
- Romano A, Viola M, Di Fonso M, et al. Anaphylaxis to streptomycin. *Allergy* 2002;57:1087-8.
- Spigarelli MG, Hurwitz ME, Nars S. Hypersensitivity to inhaled Tobi following reaction to gentamycin. *Pediat Pulmonol* 2002;33:311-4.
- Ikura M, Yamaguchi M, Hirai K, et al. Case report: streptomycin-induced anaphylactic shock during oocyte retrieval procedures for in vitro fertilization. *J Allergy Clin Immunol* 2002;109:571-2.
- Perez R, Garces M, Marcos M, et al. Anaphylaxis induced by streptomycin in cell media. *Allergy* 1996;51:135-6.

Bacitracin

Antibiotic polypeptide complex produced by *Bacillus subtilis*; widely used as a topical antibacterial medication.

■ Incidence

The incidence of allergic reactions increased from 1.5% in 1989-1990 to 9.2% in 1998-2000.

Contact dermatitis is common (22% in one series).

There have been 18 reports of immediate hypersensitivity reactions, including anaphylaxis, induced by topical bacitracin.

■ Risk factors

Alteration of the cutaneous barrier (burn, leg ulcer, extensive abrasion).

■ Clinical manifestations

- **General:** usually severe: anaphylactic shock with hypotension (80%).
- **Cutaneous:** urticaria, pruritus, swelling of the tongue and face, contact dermatitis.

■ Diagnostic methods

Skin tests: evidence of specific IgE by means of prick test or intradermal test.

Prick tests positive in a few cases after anaphylaxis (intradermal skin tests may be dangerous in such patients).

Prick tests positive to full-strength bacitracin ointment (500 U/g) and bacitracin solution (150 U/mL).

Patch tests with bacitracin (5 % in pet).

Specific serum IgE: no evidence. No assay commercially available.

■ Mechanisms

Strong evidence for IgE-mediated hypersensitivity, including positive immediate skin tests.

■ Management

Avoidance.

Patients with confirmed contact dermatitis should avoid products containing bacitracin.

Patients with bacitracin sensitivity should be taught to read labels, specifically to look for the presence of bacitracin in both prescription and over-the-counter wound care products.

Cross reaction with polymyxin b sulfate and neomycine sulfate.

References

- Greenberg K, Esposinosa J, Scali V. Anaphylaxis to topical bacitracin ointment. *Am J Emerg Med* 2007;25:95-6.
- Freiler JF, Steel KE, Hagan LL, et al. Intraoperative anaphylaxis to bacitracin during pacemaker change and laser lead extraction. *Ann Allergy Asthma Immunol* 2005;95:389-93.
- Schalock PC, Zug KA. Bacitracin. *Contact Dermatitis* 2005;76:105-7.
- Saryan JA, Dammin TC, Bouras AE. Anaphylaxis to topical bacitracin zinc ointment. *Am J Emerg Med* 1998;16:512-3.

Chloramphenicol

An antibiotic produced by *Streptomyces venezuelae*. It contains a nitrobenzene ring linked to propanol, with an amide group binding to a derivative of dichloroacetamide acid.

■ Incidence

Uncommon.

■ Risk factors

Allergy to penicillin.

Severe infection.

Previous exposure to phenicols.

■ Clinical manifestations

• **General:** anaphylactic shock, fever.

• **Cutaneous:** urticaria, maculopapular rash, angioedema, acute generalized exanthematous pustulosis, contact dermatitis.

• **Respiratory:** bronchospasm.

• **Others:** aplastic anemia.

Topical use of chloramphenicol may lead to contact dermatitis, anaphylactic shock, aplastic anemia.

■ Diagnostic methods

Skin tests

Positive scratch and patch test reported in some cases with cutaneous manifestations (patch tests with chloramphenicol 1% in pet).

Specific serum IgE against chloramphenicol has been found, with no obvious clinical manifestation.

■ Mechanisms

Unknown.

The dichloroacetamide ring is probably the major antigenic determinant.

■ Management

Avoidance.

Cross-reactivity between chloramphenicol and synthetic derivatives is likely.

References

Lee AY, Yoo SH. Chloramphenicol induced acute generalized exanthematous pustulosis proved by patch test and systemic provocation. *Acta Derm Venereol* 1999;79:412-3.

Le Coz CJ, Santinelli F. Facial contact dermatitis from chloramphenicol with cross-sensitivity to thiamphenicol. *Contact Dermatitis* 1998;38:108-9.

Moyano JC, Alvarez M, Fonseca JL, et al. Allergic contact dermatitis to chloramphenicol. *Allergy* 1996;51:67-9.

Mc Ghee CNJ, Anastas CM. Widespread ocular use of topical chloramphenicol: is there justifiable concern regarding idiosyncratic aplastic anaemia? *Br J Ophthalmol* 1996;80:182-4.

Liphshitz I, Loewenstein A. Anaphylactic reaction following application of chloramphenicol eye ointment. *Br J Ophthalmol* 1991;75:64.

Schewach-Millet M, Shapiro D. Urticaria and angioedema due to topically applied chloramphenicol ointment. *Arch Dermatol* 1985;121:587.

Chloroquine and Hydroxychloroquine

Chloroquine phosphate, a 4-aminoquinoline compound, is an antimalarial and amebicidal drug. Hydroxychloroquine sulphate is a synthetic antimalarial drug that is widely used in rheumatology due to its immunosuppressive properties. Widely used in rheumatologic diseases, particularly important in the treatment of systemic lupus erythematosus.

■ Risk factors

Exanthems are more common in dermatomyositis.

■ Clinical manifestations

- **General:** fever.

- **Cutaneous:** pruritus, urticaria, angioedema, maculopapular rash, exanthems, photosensitivity, pigmentation, erythema multiforme, Stevens-Johnson syndrome, toxic epidermal necrolysis, acute generalized exanthematous pustulosis, erythema annulare centrifugum, psoriasis (exacerbation), lichenoid eruption, purpura, vasculitis, oral pigmentation and ulceration, DRESS syndrome, bullous pemphigoid.

- **Others:** pneumonitis.

■ Diagnostic methods

Skin tests: no references.

Patch tests: No true positive reactions. False positive reactions. The threshold of specificity has to be determined.

Photo patch tests and evaluation of the minimal erythema dose at the onset of the eruption and after stopping the molecule (total spectra and UVA).

Specific serum IgE: no assay available.

■ Mechanisms

No evidence of specific IgE antibodies.

■ Management

Oral Challenge: few published data exist concerning oral challenge with chloroquine in patients who have demonstrated a hydroxychloroquine sulphate-associated drug-induced exanthema (1/2 positive oral challenge).

According to the North American Rheumatic Skin Disease Study Group Organizing Committee, chloroquine phosphate can be administered to patients who have experienced prior hydroxychloroquine sulphate-associated exanthems with a low risk of re-expression of the exanthema or appearance of others clinical forms.

Desensitization:

- Day 1: 0.1mg
- Day 2: 0.2 mg
- Day 3: 0.4 mg
- Day 4: 0.8 mg
- Day 5-11: 1 mg
- Day 12: 2 mg
- Day 13: 4 mg

- Day 14: 8 mg
- Day 15-21: 10 mg
- Day 22: 20 mg
- Day 23: 40 mg
- Day 24: 80 mg
- Day 25-31: 100 mg
- Day 32-35: 200 mg
- Day 36: 400 mg

References

Volpe A, Marchetta A, Caramaschi P, et al. Hydroxychloroquin- induced DRESS syndrome. *Clin Rheumatol* 2008;27:537-9.

Sontheimer RD. Desensitization to hydroxychloroquine: Alternative interpretations. *The J Rheumatol* 2007;34:253-5.

Mates M, Zevin S, Breur GS, et al.. Desensitization to hydroxychloroquine – experience of 4 patients. *J Rheumatol* 2006;33:814-6.

Evans CC, Bergsresser PR. Acute generalized exanthematous pustulosis precipitated by hydroxychloroquine. *J Am Acad Dermatol* 2004;50:650-1.

Kanny G, Renaudin JM, Lecompte T, et al. Chloroquine hypersensitivity syndrome. *Eur J Intern Med* 2002;13: 75-6.

Sundelin SP, Terman A. Different effects of chloroquine and hydroxychloroquine on lysosomal function in cultured retinal pigment epithelial cells. *APMIS* 2002;110:481-9

Métayer I, Balguerie X, Courville P. Photodermatosis induced by hydroxychloroquine: 4 cases (Article in French). *Ann Dermatol Venereol* 2001;128:729-731.

Murphy M, Carmichael AJ. Fatal toxic epidermal necrolysis associated with hydroxychloroquine. *Clin Exp Dermatol* 2001;26:457-8.

Clindamycin

Clindamycin is a semi-synthetic derivative of lincomycin that is active against most gram-positive and anaerobic bacteria.

Clindamycin together with pyrimethamine has been used as alternative treatment for toxoplasmic encephalitis in AIDS patients.

■ Incidence

10% incidence of cutaneous eruption reported 25 years ago.

It now appears to be much lower, <1%.

58% of patients treated with pyrimethamine/clindamycin will have cutaneous reactions after an average of 13 days.

■ Clinical manifestations

• **General:** anaphylactic shock.

• **Cutaneous:** pruritus, urticaria, angioedema, exanthematous rash, erythema multiforme, Stevens-Johnson syndrome, toxic epidermal necrolysis, acute generalized exanthematous pustulosis.

Topical use: irritant and contact dermatitis, erythema, pruritus.

• **Respiratory:** bronchospasm.

• **Others:** Sweet's syndrome, taste disorders.

■ Diagnostic methods

Skin tests

Not able to identify patients with a previous allergic reaction.

Prick tests (150 mg/ ml): negative.

Intradermal skin tests: negative.

Patch tests: clindamycin phosphate 10 % in pet; propylene glycol 5 % in pet (excipient of the topical preparation)

Specific serum IgE: no evidence for these antibodies. No assay commercially available

Drug re-challenge:

Provocation with clindamycin 150 mg per os.

In a study of 31 patients, 10 had a positive oral provocation but negative prick and intradermal tests.

■ Mechanisms

Residual impurities from the manufacturing process.

■ Management

Desensitization (orally, in AIDS patients with toxoplasmic encephalitis).

• Day 1: 20 mg, 20 mg, 20 mg

- Day 2: 40 mg, 40 mg, 40 mg
- Day 3: 80 mg, 80 mg; 80 mg
- Day 4: 150 mg, 150 mg, 150 mg
- Day 5: 300 mg, 300 mg, 300 mg
- Day 6: 600 mg, 600 mg, 600 mg
- Day 7: 600 mg, 600 mg, 600 mg, 600 mg

References

Kapoor R, Flynn C, Head PW, et al. Acute generalized exanthematous pustulosis induced by clindamycin. Arch Dermatol 2006;142:1080-1.

Notman MJ, Phillips EJ, Knowles SR, et al. Clindamycin skin testing has limited diagnostic potential. Contact Dermatitis 2005; 53:335-8.

Lammintausta K, Tokola R, Kalimo K. Cutaneous adverse reactions to clindamycin: results of skin tests and oral exposure Br J Dermatol 2002;146:643-8.

Mazur N, Greenberger PA, Regalado J. Clindamycin hypersensitivity appears to be rare. Ann Allergy Asthma Immunol 1999;82:443-5.

Garcia R, Galindo PA, Feo F, et al. Delayed allergic reactions to amoxicillin and clindamycin. Contact Dermatitis 1996;35:116-7.

Marcos C, Sopena B, Luna I, et al. Clindamycin desensitization in an AIDS patient. AIDS 1995;9: 1201-2.

Dapsone

Diaminodiphenyl sulfone is traditionally used in the treatment of leprosy and dermatitis herpetiformis; it is also part of the treatment for *Pneumocystis carinii* pneumonitis in HIV patients.

■ Incidence

Unknown, probably low (0.3%).

Side effects are common and include lethargy, headaches, methemoglobinemia, haemolysis. Severe adverse reactions are rare but can be fatal (mortality: 11%).

■ Risk factors

HIV patients.

High doses: usual dose 50 to 300 mg/day: 85% rash, 40% haemolytic anemia.

■ Clinical manifestations

- **Cutaneous:** cutaneous manifestation include exfoliative dermatitis, erythematous maculopapular eruption, Stevens-Johnson syndrome – like lesions. The clinical presentation of the rash may mimic a viral exanthema.

- **Hypersensitivity syndrome (DHS):** fever, skin eruption, and internal involvement, occurring several weeks to as late as 6 months after initial administration of the drug. Not identified, the disorder could be fatal.

- **Others:** methemoglobinemia, aplasia, haemolytic anemia, peripheral neuropathy, renal hypersensitivity vasculitis.

■ Diagnostic methods

None.

■ Mechanisms

Hypersensitivity to dapsone may be caused by metabolites of dapsone-forming haptens, with formation of anti-dapsone antibodies.

Dapsone is metabolized primarily via two pathways: N-acetylation and N-hydroxylation (oxidation). N-acetylation is mediated by N-acetyltransferase type 2 showing a bimodal pattern of activity; slow and fast acetylation. Dapsone N-hydroxylation is mediated by human liver microsomal enzymes P4503A4, 2C6 and 2C11. This pathway is thought to be the initial step in the formation of toxic intermediate metabolites (nitrosamines) that can induce haemolytic anemia.

■ Management

In case of DHS, the best approach is immediate discontinuation of the drug and administration of oral or IV glucocorticoids.

Use 50 mg/day in adults, 25 mg/day in children.

On withdrawing dapsone, patients usually recover within 2-8 weeks.

For the treatment of leprosy, replace with clofazimine (50 mg/day).

For the treatment of dermatitis herpetiformis, replace with another sulfonamide (sulfapyridine).

Desensitization possible.

References

Kosseifi SG, Guha B, Nasour DN, et al. *Dapsone hypersensitivity syndrome revisited: a potentially fatal multisystem disorder with prominent hepatopulmonary manifestations.* *J Occup Med Toxicol* 2006;1:9.

Agrawal S, Agarwalla A. *Dapsone hypersensitivity syndrome: a clinico-epidemiological review.* *J Dermatol* 2005;32:883-9.

Cook DE, Kossey JL. *Successful desensitization to dapsone for Pneumocystis carinii prophylaxis in an HIV-positive patient.* *Ann Pharmacother* 1998;32:1302-5.

de Soldenhoff R. *Are dapsone hypersensitivity reactions dose-related?* *Lepr Rev* 1990;61:391-2.

Ethambutol

Ethambutol was widely used in the treatment of tuberculosis. Side effects other than ocular (retrobulbar neuritis) toxicity are rare.

■ Incidence

Cutaneous reactions: 0.5%.

Drug fever: 0.3%.

Major adverse effects: 0.07 per 100 persons-months of exposure.

■ Risk factors

Female sex

Age over 60 years

Birthplace in Asia

HIV-positive status

■ Clinical manifestations

• **General:** fever.

• **Cutaneous:** pruritus, maculoerythematous rash, erythema multiforme, Stevens-Johnson syndrome, toxic epidermal necrolysis, lichenoid eruption

• **Respiratory:** dyspnea, pulmonary infiltrates.

• **Others:** eosinophilia, neutropenia, thrombocytopenia (purpura).

■ Diagnostic methods

Skin tests

Prick test or intradermal skin test: no evidence of specific IgE.

Patch tests:

No standard for concentration and vehicle.

In one study, when the drug was crushed and moistened in water, it was positive in patients with delayed-type hypersensitivity reaction and negative in 10 healthy controls.

Specific serum IgE: no evidence of specific serum IgE.

Challenge test is usually positive in cases with fever or maculopapular rash.

■ Mechanisms

Unknown.

■ Management

Desensitization if absolutely necessary: 0.1 mg; 0.5 mg; 1 mg; 2 mg; 4 mg; 8 mg; 16 mg; 32 mg; 50 mg; 100 mg; 200 mg at 45 minutes intervals; then 400 mg 3h30min later; then 400 mg x 3 the next day.

References

- Kurokawa I, Nakahigashi Y, Teramachi M. Erythema multiforme-type drug eruption due to ethambutol with eosinophilia and liver dysfunction. *Int J Antimicrob Agents* 2003;21:596-7.
- Yee D, Valiquette C, Pelletier M, et al. Incidence of serious side effects from first-line antituberculosis drugs among patients treated for active tuberculosis. *Am J Respir Crit Care Med* 2003;167:1472-7.
- Bakkum RS, Waard-Van Der Spek FB, Thio HB. Delayed-type hypersensitivity reaction to ethambutol and isoniazid. *Contact Dermatitis* 2002;46:359.
- Wong PC, Yew WW, Wong CF, et al. Ethambutol-induced pulmonary infiltrates with eosinophilia and skin involvement. *Eur Respir J* 1995;8:866-8.
- Grossman ME, Warren K, May A, et al. Lichenoid eruption associated with ethambutol. *J Am Acad Dermatol* 1995;33:675-6.
- Matz J, Borish LC, Routes JM, et al. Oral desensitization to rifampin and ethambutol in mycobacterial disease. *Am J Respir Crit Care Med* 1994;149:815-7.

Isoniazid

Isoniazid is a major antituberculosis drug.

■ Incidence

5% of patients.

Skin rash: 2%

Major adverse effects: 0.49 per 100 persons-months of exposure.

Two types of liver injury: mild isoniazid hepatotoxicity with increase in aminotransferase levels and asymptomatic patients (10-20%) and isoniazid hepatitis (0.1 to 4%).

■ Risk factors

Alcohol, female sex particularly in non-Whites, malnutrition, liver disease such as viral chronic hepatitis, concurrent use of drugs that induce CYP450 (e.g. phenytoin, rifampicin), slow acetylators of isoniazid

Symptoms begin within the first 3 months of treatment in the majority of patients.

■ Clinical manifestations

• **General:** anaphylaxis, fever, flu-like syndrome.

• **Cutaneous:** morbilliform, maculopapular rash, urticaria, hypersensitivity syndrome, bullous cutaneous lesions (clinical manifestation of fixed drug eruption), Stevens-Johnson syndrome and toxic epidermal necrolysis (HIV-infected patients), photosensitive lichenoid eruption, acute generalized exanthematous pustulosis, exfoliative dermatitis, contact dermatitis.

• **Respiratory:** lung infiltrates, interstitial pneumonia.

• **Others:**

Hepatitis: Two types of liver injury: mild isoniazid hepatotoxicity with an increase in aminotransferase levels and asymptomatic patients (10-20%), and isoniazid hepatitis (0.1 to 4%).

Toxic neuropathy.

■ Diagnostic methods

Skin tests

Evidence of specific IgE by means of prick test or intradermal test.

Intradermal skin test: 0.05 to 5 mg/ ml.

Patch tests: 50% in pet and photopatch tests (with UVA irradiation): no standard for concentration and vehicle.

Specific serum IgE: evidence of specific serum IgE found in one study (solid phase: Pos BSA-polystyrene).

■ Mechanisms

IgE-mediated hypersensitivity in a few cases.

Delayed hypersensitivity (contact dermatitis).

Direct idiosyncratic toxicity of the drug or a metabolite is supposed to be responsible for the injury.

I Management

Desensitization is possible and effective. Start with 0.1 mg and go to 150 mg in 17 hours. Gradual re-introduction can be achieved in many cases after resolution of hepatitis.

References

- Trabelsi S, El Aidli S, Amrani R, et al. *Serious bullous cutaneous lesions induced by isoniazid (Article in French). Thérapie* 2005; 60:599-600.
- Fountain FF, Tolley E, Chrisman CR, Self TH. *Isoniazid hepatotoxicity associated with treatment of latent tuberculosis: a 7-year evaluation from a public health tuberculosis clinic. Chest* 2005;28:116-23.
- Crook MJ. *Isoniazid-induced anaphylaxis. J Clin Pharmacol* 2003;43:545-6.
- Yee D, Valiquette C, Pelletier M, et al. *Incidence of serious side effects from first-line antituberculosis drugs among patients treated for active tuberculosis. Am J Respir Crit Care Med* 2003;167:1472-7.
- Rebollo S, Sanchez P, Vega JM, et al. *Hypersensitivity syndrome from isoniazid with positive patch test. Contact Dermatitis* 2001;45:306.
- Lee AY, Jung SY. *Two patients with isoniazid-induced photosensitive lichenoid eruptions confirmed by photopatch test. Photodermatol Photoimmunol Photomed* 1998;14:77-8.
- Holland CL, Malasky C, Ogunkoya A, et al. *Rapid oral desensitization to isoniazid and rifampin. Chest* 1990;98:1518-9.

Macrolides

Macrolides are characterized by a basic structure made up of a lactonic cycle with 2 osidic chains. They are classified according to the number of carbon atoms in the cycle: 14-membered macrolides (erythromycin, troleandomycin, roxithromycin, dirithromycin, clarithromycin), 15-membered macrolides (azythromycin), 16-membered macrolides (spiramycin, josamycin, midecamycin).

They are considered to be one of the safest anti-infective group of drugs in clinical use.

■ Incidence

Generally well tolerated.

Rare adverse reaction (0.4 to 3% of treatments).

Exceptional for anaphylaxis and acute respiratory failure.

Rare but severe acute liver failure.

■ Clinical manifestations

- **General:** anaphylaxis (erythromycin, telithromycin).

- **Cutaneous:** more frequent: urticaria (erythromycin, roxythromycin, spiramycin), angioedema, maculopapular rash.

Others cutaneous reactions: Stevens-Johnson syndrome (azithromycin) and toxic epidermal necrolysis (clarithromycin, telithromycin), fixed drug eruption (erythromycin, clarithromycin), acute generalized exanthematous pustulosis (spiramycin + métronidazole), vasculitis with or without cutaneous manifestations (clarithromycin), contact dermatitis (with topical use), Baboon syndrome after oral ingestion of macrolides, rash induced in infectious mononucleosis (azithromycin).

- **Respiratory:** asthma (spiramycin ++).

- **Others:** Acute hepatitis resulting in death in some cases (telithromycin). Myasthenic crisis (telithromycin).

■ Diagnostic methods

Skin tests: none available. Quite often negative.

Rare cases with positive skin prick tests (erythromycin, roxithromycin, spiramycin, fosfomycin)

Patch tests: Potential interest in reactions with a delayed mechanism.

Erythromycin base: 10% in pet

Spiramycin: 10% in pet

Clarithromycin: 10% in pet

Specific serum IgE: no assay commercially available.

Evidence of serum IgE to erythromycin in a solid phase sepharose assay (3 reports).

Challenge test.

I Mechanisms

IgE-mediated hypersensitivity with erythromycin in some cases. The mechanism remains essentially unknown.

I Management

Avoidance could be limited to the single causal macrolide.

Cross-reactivity among macrolides has not been demonstrated.

Cross-reactivity between tacrolimus and macrolide antibiotics has been demonstrated.

References

- Bottenberg MM, Wall GC, Hicklin GA. Apparent anaphylactoid reaction after treatment with a single dose of telithromycin. *Ann Allergy Asthma Immunol* 2007;98:89-91.
- Campi P, Manfredi M, Severino M. IgE-mediated allergy to pyrazolones, quinolones and other non-beta-lactam antibiotics. In: Pichler WJ, ed. *Drug Hypersensitivity*. Basel: Karger, 2007:216-32.
- Clay KD, Hanson JS, Pope SD, et al. Brief communication: severe hepatotoxicity of telithromycin: three case reports and literature review. *Ann Intern Med* 2006;144:415-20.
- Khalidi N, Miras A, Gromb S. Toxic epidermal necrolysis and clarithromycin. *Can J Clin Pharmacol* 2005;12:e264-8.
- Amichai B, Grunwald MH. Baboon syndrome following oral roxithromycin. *Clin Exp Dermatol* 2002;27:523.
- Dakdouki GK, Obeid KH, Kanj SS. Azithromycin-induced rash in infectious mononucleosis. *Scand J Infect Dis* 2002;34:939-41.

Penicillin and other beta-lactams

- ▶ **Beta-lactams:** bactericidal antibiotics that act on bacteria during their growth phase by inhibiting the formation of specific peptide bonds on the bacterial wall.
- ▶ **Penicillins:** the beta-lactam nucleus is attached to a thiazolidine group. The side chain contributes to the specific name of the penicillin, which is relevant for its immunological specificity, because it contributes to the structure of the epitope.
- ▶ **Cephalosporins:** beta-lactams that contain a dihydrothiazine in place of the thiazolidine ring with two different side chains.
- ▶ **Carbapenems** differ from penicillins in that they are unsaturated and contain a carbon atom instead of sulfur in the thiazolidine ring.
- ▶ **Aztreonam** is a monocyclic beta-lactam isolated from *Chromobacterium violaceum*.
- ▶ **A group of betalactamase inhibitors**, the most relevant of which is clavulanic acid, produced by *Streptomyces clavuligerus*.

Allergic reactions to beta-lactam are the most common cause of adverse reaction mediated by a specific immunological mechanism. Reactions may be induced by all beta-lactams currently available, ranging from benzylpenicillin to other more recently introduced beta-lactams, such as aztreonam or the related betalactamase-inhibitor clavulanic acid.

■ Incidence

Penicillin allergy is reported in up to 10% of patients. At the same time, more than 90% of them are found to lack penicillin-specific IgE and can tolerate the antibiotic safely.

Anaphylaxis: 0.015-0.04% (1.5-4/10,000) of treated patients; 1.23/10,000 injections in children and young adults population; 2.17/10,000 in prophylactic treatment in healthy military recruits. Incidence of anaphylaxis to cephalosporins and other beta-lactams has not been studied in large-scale surveys but it is lower than with penicillin. Studies suggest that anaphylactic reactions to cephalosporin are rare, 0.0001 to 0.1%. However, death has been reported. The incidence of cutaneous reactions range from 1% to 3%.

■ Risk factors

A previous life-threatening reaction, such as anaphylactic shock with penicillin
Concomitant illness, such as cardiovascular disease, respiratory or oncologic problems
Patients who are taking certain drugs, such as beta-blockers.

■ Clinical manifestations

Immediate (< 1 h): anaphylactic shock, urticaria, angioedema, laryngospasm, bronchospasm.

• **Cutaneous manifestations:**

Delayed reactions (>1 h):

Maculopapular rash (ampicillin and amoxycillin with or without Epstein-Barr virus infection), urticaria, angioedema, erythroderma

Acute generalized exanthematous pustulosis (amoxycillin or amoxycillin with clavulanate)

Baboon syndrome and SDRIFE (Symmetrical Drug-Related Intertriginous and Flexural Exanthema): appears within a few hours or days after administration (amoxycillin)

Erythema multiforme, Stevens-Johnson syndrome and toxic epidermal necrolysis

Serum sickness (cefaclor +++, children; amoxycillin)

Fixed drug eruption (amoxycillin)

Childhood linear IgA bullous disease (amoxycillin)

Clavulanic acid: delayed selective reaction and delayed reaction to clavulanic acid are rare.

I Diagnostic methods

- **Immediate reactions:**

Skin tests: Prick tests first. If response is negative, intradermal tests are then carried out.

Concentrations: The maximum concentration accepted nowadays for both prick and intradermal testing are:

PPL: 5×10^{-3} mmol/l

MDM: 2×10^{-2} mmol/l

Amoxycillin: 20-25 mg/ml

Ampicillin: 20-25 mg/ml

Cephalosporins: 1-2 mg/ml

In the absence of PPL and MDM, benzylpenicillin has to be used: 25,000 U/ml

In patients reporting symptoms compatible with severe reactions or who have experienced mild symptoms but are at special risk, the intradermal tests and even the prick tests should begin with a thousand-fold dilution, which is gradually increased until the maximum concentration described above is reached.

Reactions occurring after skin testing may resemble the original symptoms. 11% of patients, mostly skin test positive, developed systemic symptoms: amoxycillin in 50% of cases, PPL in 29%, MDM in 15% and ampicillin in 6%.

Retrospective studies have shown that the longer the time interval between the initial reaction and the skin test, the less likely a positive response will be obtained.

The natural history of allergy to penicillins indicates that patients can lose sensitivity and become negative over time

Sensitivity of skin testing with a clinical history of urticaria and/or anaphylaxis has been reported to be as low as 22% for PPL, 21% for MDM, 43% for amoxycillin and 33% for ampicillin. The combination of all four haptens has a sensitivity of 70%.

Specificity of skin testing was proven to be very good, from 97 to 99%.

Specific serum IgE:

ImmunoCAP Phadia: low sensitivity and high specificity

Other tests:

Cellular Allergen Stimulation test (CAST): overall sensitivity of 46% and specificity: between 79 and 89%.

Flow cytometric basophil activation test (FAST, FLOW-CAST or BASOTEST): sensitivity of 50% and specificity of 93%

Drug provocation test (DPT):

This should be done only after performing skin tests and possibly determining specific IgE-antibodies. The drug is administered at increasing doses, with a minimum of a 30 to 60 minute interval between each dose, if good tolerance is established at the previous dose.

Diagnostic algorithm

• **Short algorithm:**

- First step: clinical history, sIgE, skin tests with all reagents: prick tests followed by intradermal tests with PPL, MDM, or benzylpenicillin and the culprit drug

If any of the skin or *in vitro* tests are positive:

- Second step: drug provocation test with the apparent culprit drug may be considered.

If DPT results in good tolerance the patient could be considered to be non-allergic, but if the history is clearly positive and there is a long interval between the reaction and the diagnostic evaluation, a re-evaluation following the same protocol at least 2 to 4 weeks later has to be performed before considering the patient to be non-allergic.

• **Long algorithm:**

- First step: clinical history, sIgE, skin tests: PPL and MDM

If any of the skin or *in vitro* tests are positive:

- Second step: DPT with benzylpenicillin

If the DPT results in good tolerance, one week later:

- Third step: Prick and intradermal tests with the culprit drug

If any of the skin tests are positive:

- Fourth step: DPT with the culprit drug

Patients are considered to have a selective reaction to one betalactam when they have had an immediate allergic reaction to a betalactam, by skin test or DPT and have good tolerance to benzylpenicillin DPT.

- **Delayed reactions:**

Patch tests and intradermal reaction with delayed reading are used when a cell-mediated pathogenic mechanism, such as a maculo-papular rash, SDRIFE, erythroderma, acute generalized exanthematous pustulosis, is suggested.

Intradermal skin test: same concentration as in immediate reaction.

Patch tests following the recommendations:

Penicillin G, potassium salt: 10 % in pet

Dicloxacillin sodium salt hydrate: 10 % in pet

Amoxicillin trihydrate: 10 % in pet

Cefotaxim sodium salt: 10 % in pet

Cefalexin: 10 % in pet

Cefradine: 10 % in pet

Delayed hypersensitivity may be a long lasting condition, which does not appear to be influenced by the time interval between the last adverse reaction and allergy testing.

Generally, intradermal tests appear to be more sensitive but less specific than patch tests.

Lymphocyte transformation test:

Sensitivity of 74%, higher than that of skin tests (62%) and specificity of 85%.

In the group of high-risk patients, e.g. TEN, severe bullous exanthems, AGEP, SJS, DRESS, patch tests should be used as the first line of investigation. In case of positive results, intradermal testing may be avoided. In case of patch test negativity, for intradermal testing, the drug should be initially tested with the highest dilution. Provocation tests must be avoided.

I Mechanisms

Beta-lactam molecules have the capacity, by spontaneous opening of the beta-lactam ring, to bind to serum and cell membrane proteins forming stable covalent drug-protein adducts, known as hapten-carrier conjugates.

Immediate IgE hypersensitivity:

• To penicillins:

The penicillin molecule can open spontaneously and in the presence of an amino group, thereby forming stable covalent conjugates. Generation by penicillins of different metabolites: Major determinant: Benzylpenicilloyl and minor determinants: benzylpenicilloic, benzyl penicinellic, benzyl penamaldate, benzyl penaldate, benzyl penicoyl, benzyl penicilanyl.

Detection of sIgE against major determinant: PPL.

Detection of sIgE against minor components: MDM.

Detection of sIgE against side chains.

• To cephalosporins:

Under physiological conditions, the cephalosporin beta-lactam ring opens and with its carbonyl moiety binds a protein, forming cephalosporoyl determinant. Side chain structure usually survives such fragmentation and may be responsible for cross-reactivity among beta-lactams, including other cephalosporins.

Detection of specific IgE against side chains group R1.

Detection of specific IgE against the ring structures with the attached R2 group.

Delayed cell-mediated hypersensitivity

In delayed allergy to aminopenicillins, both the beta-lactam core structure and the whole molecule (core structure and the amino-benzyl group of the side chain) are recognized by T cells. However, the amino-benzyl group plays a predominant role, which means that the alteration of the side chain affects the recognition but also that the same side chains presented by cephalosporin core structures are not recognized. Thus, cross-reactivity between cephalosporins and penicillins seems to be rare for T cell reactions.

I Management

Cross-reactivity between penicillins and cephalosporins of the first generation had been reported. Cross-reactivity between penicillins and cephalosporins of the third and fourth generations has become rare.

Algorithms for evaluation and management of patients with histories of penicillin/cephalosporin allergy:

Patients with penicillin allergy, administration of a cephalosporin:

Only 15% of patients with a history of allergy to penicillin have positive skin tests and of those, 98% will tolerate a cephalosporin. However, those patients who react (<1%) may have fatal anaphylaxis. Before administration of a cephalosporin, 1- do a skin test to cephalosporin: 2- if negative, do a

drug provocation test to cephalosporin, 3- if negative, give cephalosporin.

Patients with cephalosporin allergy, administration of penicillin:

Skin tests to penicillin: 1- if negative, give penicillin; 2- if positive, give alternate drug or desensitize to penicillin.

Patients with cephalosporin allergy, administration of cephalosporin:

First proposition: use a cephalosporin that does not share a side chain similar to the first cephalosporin

Second proposition: skin tests to the new cephalosporin: 1- if negative: Drug provocation test with the new cephalosporin, 2- if positive: use alternate drugs or desensitize to the cephalosporin.

The pattern of cross-reactivity in delayed cutaneous reactions indicates that consideration should be given to controlled administration because many subjects who respond to aminopenicillins tolerate benzylpenicillin and subjects who respond to cephalosporins may tolerate penicillin derivatives.

Between penicillins and carbopenems, a 50% rate of cross-reactivity has been demonstrated with imipenem in patients with IgE-mediated hypersensitivity to penicillin.

Monobactam seems to have a weak cross-reactivity with other classes of beta-lactams and to be well tolerated by patients with IgE-mediated hypersensitivity to penicillin.

Desensitization

Intramuscular penicillin desensitization:

100 U, 200 U, 400 U, 800 U, 1600 U, 3200 U, 6400 U, 12,800 U, 25,000 U, 50,000 U, 100,000 U, 200,000 U, 400,000 U orally, then, 200,000 U, 400,000 U, 800,000 U subcutaneously, then 1,000,000 U intramuscularly

Interval between doses is 15 min.

Intravenous penicillin desensitization:

0.015, 0.03, 0.06, 0.125, 0.25, 0.5, 1, 2, 4, 7.5, 15, 30, 62.5, 125, 250, 500 mg.

Cumulative dose: 1000 mg.

Interval between doses is 15 min.

Penicillin oral desensitization:

0.05, 0.1, 0.2, 0.4, 0.8, 1.6, 3.2, 6, 12, 25, 50, 100, 200, 400 mg.

Cumulative dose: 800 mg.

Interval between doses is 30 min.

Intravenous cephalosporin desensitization:

Goal dose 1g:

0.1; 0.2; 1.0; 2.0; 10; 20; 70; 200; 700 mg

Cumulative dose: 1,003.3 mg

Interval between doses is 15 min.

Goal dose 2 g

0.1; 0.4; 1.0; 4.0; 10; 40; 140; 400; 1400 mg

Cumulative dose: 1995.5 mg

Interval between doses is 15 min.

References

- Padial A, Antunez C, Blanca-Lopez N, et al. Non-immediate reactions to beta-lactams: diagnostic value of skin testing and drug provocation test. *Clin Exp Allergy* 2008;38:822-8.
- Gonzalez de Olano D, Losada Pena A, de la Hoz Caballer B, et al. Selective sensitization to clavulanic acid and penicillin V. *J Invest Allergol Clin Immunol* 2007;17:119-21.
- Ponvert C, Weilenmann C, Wassenberg J, et al. Allergy to betalactam antibiotics in children: a prospective follow-up study in retreated children after negative response in skin and challenge tests. *Allergy* 2007;62:42-6.
- Torres MJ, Blanca M, and the European Network for Drug Allergy and the EAACI interest group on drug hypersensitivity. Importance of skin testing with major and minor determinants of benzylpenicillin in the diagnostic of allergy to betalactams. Statement from European Network for Drug Allergy concerning Allergopen withdrawal. *Allergy* 2006;61:910-1.
- Bonadonna P, Schiappoli M, Senna G, et al. Delayed selective reaction to clavulanic acid: a case report. *J Invest Allergol Clin Immunol* 2005;15:302-4.
- Romano A, Guéant-Rodriguez R-M, Viola M, et al. Diagnosing immediate reactions to cephalosporins. *Clin Exp Allergy* 2005;35:1234-42.
- Win PH, Brown H, Zankar A, et al. Rapid intravenous cephalosporin desensitization. *J Allergy Clin Immunol* 2005;116:225-7.
- Romano A, Blanca M, Torres MJ, et al. Diagnosis of non-immediate reactions to beta-lactam antibiotics. *Allergy* 2004;59:1153-60.
- Torres MJ, Blanca M, Fernandez J, et al. Diagnosis of immediate allergic reactions to beta-lactam antibiotics. *Allergy* 2003 ;58:961-72.
- Blanca M, Mayorga C, Torres MJ, et al. Clinical evaluation of Phadia CAP System RAST FEIA amoxicilloyl and benzylpenicilloyl in patients with penicillin allergy. *Allergy* 2001;56:862-70.
- Kelkar PS, Li J T C. Cephalosporin allergy. *N Engl J Med* 2001;354:804-9.

Pentamidine

Aerosolized pentamidine is widely used to treat *Pneumocystis carinii* pneumonitis in AIDS patients. Conversely, for reasons of efficacy and toxicity, the intravenous form of the drug is seldom used.

■ Incidence

Bronchospasm: 10 to 29%.

Cutaneous reactions: morbilliform eruptions 15%.

■ Risk factors

Number of concomitant medication

Non-white ethnicity

Cumulative dosage of pentamidine

Concurrent use of other nephrotoxic drug

■ Clinical manifestations

• **Cutaneous:** pruritus, contact urticaria, rash and exanthem (frequent), Stevens-Johnson syndrome and toxic epidermal necrolysis (rare), injection site reactions (frequent).

• **Respiratory:** bronchospasm (aerosolized pentamidine), laryngeal edema, tongue swelling, hypersensitivity pneumonitis.

• **Others:** conjunctivitis, cardiotoxicity, nephrotoxicity, dysglycemia, hepatotoxicity, hyperkalemia, hyperamylasemia.

■ Diagnostic methods

Skin tests: none validated.

Prick tests positive with 3 mg/ml pentamidine isethionate in contact urticaria and in some cases of bronchospasm.

Intradermal skin tests: false positive with 0.015 and 0.15 mg/ml pentamidine.

Specific serum IgE: no evidence of serum specific IgE. No assay commercially available.

Challenge tests: intravenous test dose is dangerous (2 deaths reported).

■ Mechanisms

Nonspecific histamine release (documented with intravenous pentamidine).

IgE-mediated hypersensitivity (contact urticaria, some cases of bronchospasm).

Irritative effect with nebulized use (bronchospasm).

■ Management

Premedicate with nebulized beta-2 mimetic before aerosolized pentamidine.

Slow intravenous administration (decreases nonspecific histamine release).

In patients with hypersensitivity to systemic pentamidine, the cautious administration of aerosolized pentamidine is safe when the following protocol is applied:

Dilution of 300 mg of pentamidine isethionate in 20 ml of sterile water (15 mg/ ml).

Dilution	Volume inhaled	Pentamidine (mg)
1/10,000	4	0.006
1/1,000	4	0.06
1/100	4	0.6
1/10	4	6
Full strength	20	300

References

Antoniou T, Gough KA. Early-onset pentamidine-associated second-degree heart block and sinus bradycardia: case report and review of the literature. *Pharmacotherapy* 2005;25:899-903.

O'Brien JG, Dong BJ, Coleman RL, et al. A 5-year retrospective review of adverse drug reactions and their risk factors in human immunodeficiency virus-infected patients who were receiving intravenous pentamidine therapy for pneumocystis carinii pneumonia. *Clin Infect Dis* 1997;24:854-9.

Carr A, Cooper DA. Pathogenesis and management of HIV-associated drug hypersensitivity. *AIDS Clin Rev* 1995;96:65-97.

Belsito DV. Contact urticaria from pentamidine isethionate. *Contact Dermatitis* 1993;29:158-9.

Pradalier A, Vincent D, Bouée S, et al. Bronchospasm of allergic mechanism caused by pentamidine isethionate aerosols (Article in French). *Presse Med* 1993;22:554.

Baum CG, Sonnabend JA, O'Sullivan M. Prophylaxis of AIDS-related *Pneumocystis carinii* pneumonia with aerosolized pentamidine in a patient with hypersensitivity to systemic pentamidine. *J Allergy Clin Immunol* 1992;90:268-9.

Praziquantel

Praziquantel is an isoquinolin drug widely used as a trematodicide.

■ Incidence

Exceptional.

■ Risk factors

Unknown.

■ Clinical manifestations

- **General:** anaphylactic systemic manifestations
- **Cutaneous:** pruritus, urticaria, angioedema, rash.
- **Respiratory:** dyspnea

■ Diagnostic methods

None available.

■ Mechanisms

Unknown.

■ Management

Desensitization:

Premedication with hydroxyzine, dexamethasone and prednisone 6 hours prior to administration of praziquantel: 18 mg x 6 then 180 mg x 3, then 360 mg x 3 (at 15 minute intervals).

References

Shen C, Choi MH, Bae YM, et al. A case of anaphylactic reaction to praziquantel treatment . *Am J Trop Med Hyg* 2007;76:603-5.

Huang S.W. A clinical approach to a patient with praziquantel hypersensitivity. *J Allergy Clin Immunol* 1992;90:867.

Pyrazinamide

A synthetic pyrazine analogue of nicotinamide used in the treatment of tuberculosis. It has gained importance in the past years as the incidence of multi-resistant tuberculosis has been increasing.

■ Incidence

Major adverse effects: 1.31 to 1.61 per person-months of exposure.

■ Risk factors

Female sex
Age over 60 years
Birthplace in Asia
HIV-positive status

■ Clinical manifestations

• *Mainly cutaneous:*

Maculopapular rash, pruritus, urticaria, flushing, photosensitivity, lichenoid photodermatitis, erythema multiforme, fixed drug eruption.

• *Others:*

Liver injury rare but sometimes lethal.
Joint symptoms, usually due to hyperuricemia
Fever

■ Diagnostic methods

Skin tests

Prick tests and intradermal skin test: no evidence of cutaneous specific IgE.
Patch-tests: pyrazinamide 1% eth and 10% eth. Positive in one patient with a pruriginous rash.

Specific serum IgE: no evidence of specific serum IgE.

■ Mechanisms

Undetermined.

Nicotinamide, from which pyrazinamide has been synthesized, regularly causes truncal and facial flushing and itching. These reactions appear to be prostaglandin-mediated and can be prevented by aspirin. One could hypothesize that a similar mechanism is responsible for pyrazinamide-induced flushing and skin rash.

■ Management

Desensitization if absolutely necessary: starting dose 5 mg, increasing by 50 to 100% every 30 minutes up to the total dose.

References

Yee D, Valiquette C, Pelletier M, et al. Incidence of serious side effects from first-line antituberculosis drugs among patients treated for active tuberculosis. *Am J Respir Crit Care Med* 2003;167:1472-7.

Ribi C, Hauser H. Adverse reaction to pyrazinamide. *Allergy* 2002;57:964-5.

Choonhakarn C, Janma J. Pyrazinamide-induced lichenoid photodermatitis. *J Am Acad Dermatol* 1999;40:645-6.

Shorr AF, Trotta RF. Pyrazinamide hypersensitivity. *Chest* 1996;109:855-6.

Goday J, Aguirre A, Diaz-Perez JL. A positive patch test in a pyrazinamide drug eruption. *Contact Dermatitis* 1990;22:181-2.

Quinine

Quinine is the main alkaloid derived from cinchona bark. It is used in medicine mainly as an antimalarial drug but also as an antipyretic and analgesic. It is easily available in many over-the-counter preparations (e.g., for treatment of nocturnal leg cramps).

■ Incidence

Anaphylaxis is uncommon.

Thrombocytopenia is more frequent (1/1000 to 1/3500).

■ Clinical manifestations

• **General:** anaphylactic shock, fever.

• **Cutaneous:** pruritus, urticaria, angioedema, exanthems and rash, photosensitivity, fixed drug eruption, DRESS syndrome, erythema multiforme, Stevens-Johnson syndrome, toxic epidermal necrolysis, oral mucous ulceration, lichenoid eruption, purpura, vasculitis, acral necroses, pigmentation.

• **Others:** anemia, neutropenia, thrombocytopenia.

Thrombotic thrombocytopenic purpura, hemolytic uremic syndrome.

A survey carried out in the Eastern United States estimated that quinine/quinidine cause acute immune thrombocytopenia in 26 per millions users per week.

Hepatitis.

■ Diagnostic methods

Skin tests: no reference on specificity limit.

Intradermal skin tests: positive 1/1000 in one case of anaphylaxis.

Patch tests and photopatch tests: Quinine sulphate 1% in aq; UVA irradiation.

Specific serum IgE: no assay commercially available.

Positive RAST and RAST-inhibition assays in one case of anaphylaxis.

Serologic methods

- Quinine-dependent neutrophil antibodies IgG, IgM (immuno-fluorescence, agglutination).
- Quinine-dependent platelet antibodies IgG, IgM (immuno-fluorescence).
- Quinine-dependent erythrocyte antibodies (antiglobulin test).

Oral provocation test: positive in one case of anaphylaxis.

■ Mechanisms

IgE-mediated hypersensitivity in rare cases.

Possible unifying concept in which one structural element of the drug binds to antibody and a second binds to the target glycoprotein.

Cytotoxicity: thrombocytopenia, anemia, leukopenia.

Delayed cell-mediated hypersensitivity: contact dermatitis.

I Management

Cross-reactivity between quinine and quinidine (photoallergy)

Warning of quinine potentially harmful effects should be printed on all over the counter preparations and on bottles of quinine-containing tonic water.

References

- Hickey JR, Dunnill GS, Sansom JE. Photoallergic reaction to systemic quinine sulphate. *Contact Dermatitis* 2007;57:384-6.
- Muso Y, Kentarou O, Itami S, et al. Fixed eruption due to quinine: report of two cases. *J Dermatol* 2007;34:385-6.
- Bougie DW, Wilker PR, Aster RH. Patients with quinine-induced immune thrombocytopenia have both 'drug dependent' and 'drug-specific' antibodies. *Blood* 2006;108:922-7.
- Gréco M, Dupré-Goetghebeur D, Leroy JP, et al. DRESS syndrome related to Hexaquine (quinine and thiamine) - (Article in French). *Ann Dermatol Venereol* 2006;133:354-8.
- Kojouri K, Vesely SK, George JN. Quinine-associated thrombotic thrombocytopenic purpura-hemolytic uremic syndrome: frequency, clinical features, and longterm outcomes. *Ann Intern Med* 2001;135:1047-51.
- Abreu-Gerke L, Goerz G, Miller A, et al. Acral necroses after therapy with quinine sulfate for calf cramps. *Hautartz* 2000;51:332-5.

Quinolones

Quinolones form a family of synthetic antibiotics which have been used for more than 30 years. Because of their broad antibacterial activity in the gram-negative and gram-positive spectrum and their enhanced potency, they are widely used.

Ciprofloxacin, Enoxacin, Levofloxacin, Lomefloxacin, Moxifloxacin, Norfloxacin, Ofloxacin, Péfloxacin, Sparfloxacin.

■ Incidence

1.8 to 23/10 million days of treatment.

■ Risk factors

AIDS.

Female gender.

Sun exposure (photosensitivity).

Past exposure to quinolones or related compounds (Chloroquine, Glafenine, Tiliquinol, Nitroxolin).

■ Clinical manifestations

Immediate reactions:

Fluoroquinolones rarely cause anaphylactic or anaphylactoid reactions; they can cause pruritus, urticaria, and angioedema.

Delayed reactions:

• *Cutaneous:*

Exanthems: maculopapular exanthema are usually not very severe.

Acute generalized exanthematous pustulosis.

Fixed drug eruptions have been observed with ciprofloxacin, norfloxacin, moxifloxacin and ofloxacin.

Photosensitivity and phototoxicity are the most common adverse reactions with bullous eruption, photo-onycholysis, petechia localized to sunlight-exposed areas. Sparfloxacin photosensitivity is severe and frequent.

• *Severe cutaneous drug reactions:* acute generalized exanthematous pustulosis, erythema multiforme, Stevens-Johnson syndrome (moxifloxacin), toxic epidermal necrolysis, acute febrile neutrophilic dermatitis (Sweet's syndrome), auto-immune bullous disease (ciprofloxacin).

• *Others:*

Hematologic side effects: Thrombocytopenia and haemolytic anemia have been repeatedly attributed to fluoroquinolone therapy (estimated incidence for ciprofloxacin 1:17,000, for norfloxacin 1:25,000, for ofloxacin 1:33,000)

Hepatic side effects : Elevated hepatic laboratory indices are observed in 2%-3% of patients for most fluoroquinolones without serious hepatotoxic events. Serious hepatotoxic events occur with an incidence 0.1% to 1%. Ciprofloxacin was the culprit in 44% of reports, but at the same time it is the most frequently prescribed. Acute hepatitis begins 4 to 10 days after the end of treatment. Other disor-

ders reported are acute interstitial nephritis associated with arthralgias, eosinophilia, fever and skin rashes.

Fatal reactions due to hepatitis, hematologic disorders, acute interstitial nephritis, vasculitis and shock (ciprofloxacin) have been reported.

Differentiate from other side effects: gastrointestinal disturbance, neuropsychiatric manifestations.

I Diagnostic methods

Skin tests: Prick test and Intradermal tests results are considered to be unreliable because they are often positive in healthy controls (direct histamine release).

Recommended non-irritant intradermal test concentrations differ according to studies: ciprofloxacin: 0.004 mg/ml; 0.02g/ml; 0.002/ml. Levofloxacin: 0.025g/ml. Ofloxacin: 0.5 mg/ml

Patch test: Norfloxaxine: 10% en pet

Ciprofloxacin hydrochloride: 10% in pet

Specific serum IgE: no commercial assay available.

Specific IgE to quinolones using epoxy-activated 6B as a solid phase used in 55 patients detected about 50% of immediate reactions to quinolones. Cross-reactivity of IgE among different quinolones is frequent, suggesting a common avoidance of quinolones in symptomatic patients.

Challenge test: Diagnosis based solely on provocation test. Several cases of positive challenges have been reported even though the skin test was negative.

I Mechanisms

In immediate-type reactions, an assay detecting quinolone-specific IgE revealed specific antibodies in more than 50% of patients, and the majority of sera also reacted with related compounds.

In maculopapular exanthemas caused by ciprofloxacin, specific T cells could be detected and cloned. Cross-reactivity to related compounds was detected in approximately 50% of the clones.

I Management

Avoidance.

The structural similarity of quinolones, the clinical data on cross-reactions and some *in vitro* analyses suggest frequent cross-reactivity. Strict avoidance of all quinolones is advisable.

Desensitization: Induction of tolerance is obviously possible, but this should be done for vital indications and when no alternative drug are available.

Ciprofloxacin 0.05 mg to 250 mg (0.05/0.1/0.2/0.4/0.8/1.6/3.2/6.4/12.8/25/50/ 100/250g doses administered every 15 minutes).

References

Urbina F, Barrios M, Sudy E. *Photolocalized purpura during ciprofloxacin therapy. Photodermatol Photoimmunol Photomed* 2006;22:111-2

Scherer K, Bircher AJ. *Hypersensitivity reactions to fluoroquinolones. Current Allergy and Asthma reports* 2005;5:15-21.

Hausermann P, Scherer K, Weber M, et al. *Ciprofloxacin-induced acute generalized exanthematous pustulosis*

mimicking bullous drug eruption confirmed by a positive patch test. Dermatology 2005;211:277-80.

Manfredi M, Severino M, Testi S, et al. Detection of specific IgE to quinolones. J Allergy Clin Immunol 2004;113:155-60.

Campi P, Pichler WJ. Quinolone hypersensitivity. Curr Opin Allergy Clinical Immunol 2003;3:275-81.

Lantner RR. Ciprofloxacin desensitization in a patient with cystic fibrosis. J Allergy Clin Immunol 1995;96:1001-2.

Rifampicin

Rifampicin is a semi-synthetic broad-spectrum antibiotic very effective against mycobacteria, Brucella, and Staphylococci.

■ Incidence

Mild cutaneous reaction have been observed in 0.5-5% of patients. Skin rash: 0.8%
Major adverse effects: 0.43 per 100 persons-months of exposure.

Anaphylactic shock is rare (6/30,000 reports of possible allergic reactions to rifampicin).

In up to 20% of patients, there are adverse effects. Most often a “flu-like” syndrome has been reported, rare when administered in daily regimens (0.1 to 4%); frequent in intermittent or discontinuous regimens (20%).

■ Risk factors

Age over 60 years

HIV-positive status (up to 47% of adverse reactions)

Intermittent treatment (flu-like syndrome, acute haemolytic anemia, renal failure, thrombocytopenic purpura).

■ Clinical manifestations

- **General:** anaphylactic shock, serum sickness.

- **Cutaneous:** pruritus, urticaria, angioedema, exanthems

Erythema multiforme, Stevens-Johnson syndrome and toxic epidermal necrolysis (risk factor: HIV infection, association of rifampicin with isoniazid, severe and sometimes fatal), fixed drug eruption, acute generalized exanthematous pustulosis, red man syndrome (red discoloration and facial and periorbital oedema), vasculitis, auto-immune diseases (lupus erythematosus, linear IgA dermatosis, pemphigus)

- **Respiratory:** dyspnea, bronchospasm.

- **Others:** “Flu-like” syndrome: fever, shivering, faintness, headache, myalgia, arthralgia, skin reaction like exanthema and urticaria, abdominal pain and cramps, dyspnea or rarely shock.

Thrombocytopenic purpura, haemolytic anemia.

Renal failure.

■ Diagnostic methods

Skin tests

Intradermal skin tests: non-irritative intradermal cutoff concentration was established in 24 volunteers at a dilution to 1:10,000 (approximately 0.006mg/ml)

Positive at a dilution of 1:10,000.

Some reported cases with positive skin tests may have been false positive due to irritant characteristics of Rifampicin.

Patch tests: not validated. No standard for concentration and vehicle

Specific IgE (ImmunoCAP Phadia): positive in some cases

I Mechanisms

Possible IgE-mediated hypersensitivity: Rifampicin may form conjugates with proteins and induce specific IgE.

There is some evidence that the “flu-like” syndrome is due to circulating antibodies complexing with rifampicin.

I Management

Desensitization (contra-indicated if severe manifestations: renal failure, thrombocytopenia).

Examples of some protocols:

- 0.1 mg ; 0.5 mg ; 1 mg ; 2 mg ; 4 mg ; 8 mg ; 16 mg ; 32 mg ; 50 mg ; 100 mg ; 150 mg at 45 minutes intervals, then 300 mg 3H30 later, then 300 mg x 2 next day.
- 0.1 mg to 300 mg within 17 hours.
- 7 days desensitization:
Day 1: 5 mg x 6,
Day 2: 10/20/30/40/50/60 mg,
Day 3: 20/40/60/80/100/120 mg,
Day 4: 50/100/150/200/250/300 mg,
Day 5: 100/200/300/400/500/600 mg,
Day 6: 150/300/450/600/750/900,
Day 7: 300 x 3 mg.

References

- Buergin S, Scherer K, Häusermann P, et al. Immediate hypersensitivity to Rifampicin in 3 patients: Diagnostic procedure and induction of clinical tolerance. *Int Arch Allergy Immunol* 2006;140:20-6.
- Azad A, Connelly N. Case of rifampicin-induced acute generalized exanthematous pustulosis. *Intern Med J* 2006;36:619- 20.
- Pitche P, Mouzou T, Padonou C, et al. Stevens-Johnson syndrome and toxic epidermal necrolysis after intake of rifampicin-isoniazid: report of 8 cases in HIV-infected patients in Togo. *Med Trop* 2005;65:359-62.
- Yee D, Valiquette C, Pelletier M, et al. Incidence of serious side effects from first-line antituberculosis drugs among patients treated for active tuberculosis. *Am J Respir Crit Care Med* 2003;167:1472-7.

Rifamycin SV

Semi-synthetic antibiotic derived from Rifamycin B.
Widely used by surgeons for local application.

■ Clinical manifestations

- **General:** anaphylactic reactions.
- **Cutaneous:** contact dermatitis, contact urticaria.

■ Diagnostic methods

Skin tests

Prick tests 50 µg/ml. Negative in control for undiluted drug.

Intradermal tests 50 µg/ml to 5000 µg/ml

Patch tests: no standard for concentration and vehicle. No available.

Specific serum IgE: detected in at least one case.

Basophil activation test.

■ Mechanisms

IgE-mediated allergy.

■ Management

Avoidance.

Possible cross-reactivity with Rifampicin and Rifabutin.

References

Ebo DG, Verheecke G, Bridts CH, et al. Perioperative anaphylaxis from locally applied rifamycin SV and latex. *Br J Anaesth* 2006;96:738-42.

Magnan A, Venemalm L, Vervloet D, et al. Anaphylactic reaction to rifamycin SV: presence of specific IgE antibodies. *J Allergy Clin Immunol* 1999;103:954-6.

Erel F, Karaayvaz M, Deveci M, et al. Severe anaphylaxis from rifamycin SV. *Ann Allergy Asthma Immunol* 1998;81:257-60.

Cardot E, Tillie-Leblond I, Jeannin P, et al. Anaphylactic reaction to local administration of rifamycin SV. *J Allergy Clin Immunol* 1995;95:1-7.

Grob JJ, Pommier G, Robaglia A, et al. Contact urticaria from Rifamycin. *Contact Dermatitis* 1987;16:284-5.

Sulfamethoxazole-trimethoprim (SMX-TMP)

Both components of cotrimoxazole act as antifolate drugs by inhibiting the biosynthesis of tetrahydrofolic acid.

Cotrimoxazole is widely used in AIDS patients with *Pneumocystis carinii* pneumonia.

■ Incidence

General population: less than 10%

Between 44% to 83% of HIV-infected individuals experience some form of adverse reactions with SMX-TMP.

Severe, life threatening idiosyncratic toxicity: 1/10,000.

■ Risk factors

Higher CD4+ T cell count > 20 x 10⁶ cells/l, CD4:CD8 ratio <0.10, treatment for less than 14 days and, possibly, a slow acetylation phenotype.

Male sex, a history of syphilis, and a high total protein are associated with cutaneous reactions.

Human immunodeficiency virus (low CD4+ T cells)

■ Clinical manifestations

• *Differentiate:*

• 1- Pharmacologic toxicity: blood dyscrasias associated with folate deficiency, renal tubular acidosis, nausea and vomiting, headache and neurological disturbances, hypoglycemia, goitrogenic effects.

• 2- Intrinsic toxicity: renal toxicity, methaemoglobinaemia, keratoconjunctivitis sicca.

• 3- Idiosyncratic or hypersensitivity toxicity result in a wide variety of hypersensitivity reactions:

- Sulfonamide allergy (rare).

Anaphylactic shock.

Bronchospasm.

Urticaria, rash.

- Sulfonamide hypersensitivity reactions (AIDS), occurring 7-12 days after starting treatment:

• *Cutaneous:*

Pruritus, urticaria, angioedema

Maculopapular exanthema (the most frequent cutaneous reaction, appearing one to three weeks after the initiation of treatment, disappearing spontaneously in a few days, may be the first manifestation of a more severe cutaneous drug reaction)

Erythema multiforme, Stevens-Johnson syndrome, toxic epidermal necrolysis (frequent)

DRESS syndrome (frequent)

Fixed drug eruption (frequent; HLA A30 B 13 Cw 6 is a potential risk factor)

Acute generalized exanthematous pustulosis (rare)

Others: Photosensitivity, erythema nodosum, Sweet's syndrome, lupus erythematosus, linear IgA dermatosis, bullous pemphigoid, vasculitis (one or two weeks after the initiation of the treatment)

- **Others:**

Anicteric hepatitis.

Acute interstitial pneumonitis.

Aseptic meningitis, myocarditis, serum sickness, uveitis, eosinophilia, leukocytosis.

Severe hypersensitivity reactions with fever, eosinophilia affecting liver, kidney, skin and bone marrow

I Diagnostic methods (in immediate hypersensitivity reactions)

Skin tests

Full-strength concentration, sulfamethoxazole component: 80mg/ml;

Intradermal skin tests: non irritating concentration = 100-fold dilution from full-strength

Patch tests

Cotrimoxazole: 10% in pet

Specific serum anti-SMX IgE: evidence in 4 studies using a sepharose solid phase.

I Mechanisms

1- IgE-mediated hypersensitivity (rare).

The major determinant is N4-sulfonamidyl group. Positive skin tests, specific IgE.

2- Sulfonamide hypersensitivity reactions in AIDS patients.

The exact pathogenesis of SMX-TMP reactions is not completely understood.

Involvement of one or more metabolic, toxic, and/or immunologic factors is likely.

In normal hosts, 45% to 70% of SMX is acetylated by N-acetyltransferase to N-acetylsulfamethoxazole, and only a small fraction of SMX undergoes oxidation by cytochrome P450 to sulfamethoxazole hydroxylamine. Sulfamethoxazole hydroxylamine is a reactive metabolite and may spontaneously form nitrosulfamethoxazole. The nitroso metabolite may covalently link to host proteins, causing direct cellular toxicity, which leads to immune responses.

It has also been suggested that when glutathione levels are low and there is a deficiency in the ability to detoxify reactive metabolites, patients are at higher risk for hypersensitivity reactions.

I Management

Treatment of patients with corticosteroids within the first 24 hours of SMX-TMP treatment decreases the incidence of hypersensitivity.

Faced with hypersensitivity reaction to SMX-TMP in AIDS patients, there are 3 possibilities:

- Treatment throughout the duration of hypersensitivity.

The rash (pruritic or non-pruritic general exanthema, fever) may be treated symptomatically with antihistamines and may resolve.

- Re-challenge

A history of cutaneous rash is not a contra-indication to retreatment, since only 20 to 66% of cutaneous reactions occur on re-challenge.

- Desensitization

Several desensitization protocols have been developed. Graded challenges involve increasing the amount of antigen over a longer period, from 48 hours to 14 days. One example: doses of SMX-TMP (mg): Day 1: 4-0.8/8-1.6/ 20-4/40-8 mg. Day 2: 80-16/160-32/200-40 mg. Day 3: 400-80 mg. Success varies from 80% to 100%.

Risk factor of desensitization failure: female sex. Life-threatening reactions may occur during desensitization.

Cross-sensitivity between SMX-TMP and sulfadiazine is frequent.

For patients who have a history of allergy to sulfonamide antibiotics, concern has been raised about the use of other sulfonamide-containing drugs (diuretics, sulfonyleureas, and celecoxib). However, sulfonamide antimicrobial agents (sulfamethoxazole, sulfadiazine, sulfisoxazole, and sulfacetamide) differ from other sulfonamide-containing medications by having an aromatic amine group at the N4 position and a substituted ring at the N1 position; these groups are not found in non-antibiotic sulfonamide-containing drugs. Thus, despite product-labeling warnings, cross-reactivity between these two groups of sulfonamides is believed to be unlikely.

References

- Hemstreet BA, Page RL. Sulfonamide allergies and outcomes related to use of potentially cross-reactive drugs in hospitalized patients. *Pharmacotherapy* 2006;26:551-17.
- Morimoto T, Sato T, Matsuoka A, et al. Trimethoprim sulfamethoxazole induced hypersensitivity syndrome associated with reactivation of human herpesvirus 6. *Intern Med* 2006;45:101-5.
- Strom BL, Schinnar R, Apter AJ, et al. Absence of cross-reactivity between sulfonamide antibiotics and sulfonamides nonantibiotics. *N Engl J Med* 2003;349:1628-35.
- Reilly TP, Ju C. Mechanistic perspectives on sulfonamide-induced cutaneous drug reactions. *Curr Opin Allergy Clin Immunol* 2002;2:307-15.
- Rabaud C, Charreau I, Izard S, et al. Adverse reactions to cotrimoxazole in HIV-infected patients: predictive factors and subsequent HIV disease progression. *Scand J Infect Dis* 2001;33:759-64.
- Oskaya-Bayazit E, Akar U. Fixed drug eruption induced by trimethoprim-sulfamethoxazole: evidence for a link to HLA-A 30 B 13. *J Am Acad Dermatol* 2001;45:712-7.
- Hennessy S, Strom BL, Berlin JA, et al. Predicting cutaneous hypersensitivity reactions to cotrimoxazole in HIV infected individuals receiving primary *Pneumocystis carinii* pneumonia prophylaxis. *J Gen Intern Med* 1995;10:380-6.

Sodium fusidate

Sodium fusidate is a sodium salt of fusidic acid widely used for the treatment of cutaneous *Staphylococcus aureus* infections.

■ Incidence

Low, despite increasing usage

■ Risk factors

Atopic dermatitis.
Stasis dermatosis
Venous stasis
Leg ulcers.

■ Clinical manifestations

• **Cutaneous:** contact eczema.

• **Others:** reversible hepatotoxicity. Rarely agranulocytopenia, thrombocytopenia and venous spasm.

■ Diagnostic methods

Patch tests
Fucidic acid sodium salt (2% in pet)

■ Mechanisms

Type IV delayed hypersensitivity.

■ Management

Avoidance.

References

De Castro Martinez FJ, Ruiz FJ, Tornero P, et al. Systemic contact dermatitis due to fusidic acid. *Contact Dermatitis* 2006;54:169.

Morris SD, Rycroft RJ, White IR, et al. Comparative frequency of patch test reactions to topical antibiotics. *Br J Dermatol* 2002;146:1047-51.

Christiansen K. Fusidic acid adverse drug reactions. *Int J Antimicrob Agents* 1999;12 Suppl 2:S3-9.

Giordano-Labadie F, Pelletier N, Bazex J. Contact dermatitis from sodium fusidate. *Contact Dermatitis* 1996;34:159.

Streptomycin

Streptomycin is a chemical complex substance that is composed of a central hexose (streptidine) linked to an amine-substituted disaccharide. Widely used in the past (tuberculosis), its use has declined drastically but is now routinely added to cell culture media (PHA-LAK) and to Ham's F-10 medium, which is used for in vitro fertilization.

I Incidence

> 2% of treatments

I Clinical manifestations

- **General:** anaphylactic shock, fever (11% with long-term streptomycin), serum sickness.
- **Cutaneous:** rash, urticaria and contact dermatitis and, less frequently: Stevens-Johnson syndrome, toxic epidermal necrolysis.
- **Others:** eosinophilia, haemolytic anemia.

I Diagnostic methods

Skin tests

One study reported positive prick tests at a concentration of 1mg/ml and with negative prick tests and intradermal tests at the same concentration in 20 healthy control subjects

Prick-tests: 1 to 10 mg/ml.

Intradermal skin tests: 1 mg/ ml.

Patch-tests

streptomycin 20% in pet

Specific serum IgE: no evidence of specific serum IgE.

I Mechanisms

High molecular weight impurities (streptomycin polymers) related to some reactions; amino groups of streptomycin are the epitopes involved in immediate-type allergies.

I Management

Desensitization (3 hours) beginning with 1mg intravenously.

References

Hmouda H, Laouani-Kehrid C, Nejib Karaoui M, et al. A rare cause of streptomycin-induced toxic epidermal necrolysis in a patient with tuberculosis: a therapeutic dilemma. *Ann Pharmacother* 2005;39:165-8.

Romano A, Viola M, Di Fonso M, et al. Anaphylaxis to streptomycin. *Allergy* 2002;57:1087-8.

Iikura M, Yamaguchi M, Hirai K, et al. Case report: streptomycin-induced anaphylactic shock during oocyte retrieval procedures for in vitro fertilization. *J Allergy Clin Immunol* 2002;109:571-7.

Perez R, Garces M, Marcos M, et al. Anaphylaxis induced by streptomycin in cell media. *Allergy* 1996;51:135-6.

Tinkelman DG, Bock A. Anaphylaxis presumed to be caused by beef containing streptomycin. *Ann Allergy* 1984;53:242-4.

Sulphadiazine-Sulfadoxine

Sulphadiazine combined with pyrimethamine is the most effective first-line treatment of cerebral toxoplasmosis in AIDS patients

■ Incidence

High, but no accurate findings.

Adverse reactions were estimated to be 1.2 per 100,000 exposures for sulfadoxine-pyrimethamine, higher in adults: 1.7 per 100,000 exposures.

■ Risk factors

AIDS.

■ Clinical manifestations

• **General:** fever (10%), conjunctivitis.

• **Cutaneous:**

Rash, pruritus, urticaria, periorbital edema, anaphylaxis

Photosensitivity

Fixed drug eruption

Erythema multiforme, Stevens-Johnson syndrome, toxic epidermal necrolysis (possibly fatal)

DRESS syndrome

Lupus erythematosus

Serum sickness

Contact dermatitis and argyria with silver sulphadiazine

• **Others:** acute renal failure, Haematological: leukopenia (40%), thrombocytopenia (12%).

■ Diagnostic methods

None

Skin tests: prick tests, Intradermal skin tests, Patch tests. None validated.

Specific serum IgE: no evidence for specific IgE.

■ Mechanisms

Two different pathways: The N-acetylation pathway which is genetically determined and saturable and the cytochrome P450 pathway which produces toxic hydroxylamine metabolites “detoxified” by glutathione.

■ Management

Cross-reactivity between different sulfonamide antibiotics is variable (52%) being most likely between sulfamethoxazole and sulphadiazine.

No adverse effect were reported with sulphonamide non-antibiotic use among patients with histories of life-threatening reactions to sulfonamides.

Alternative therapy

Replace sulphadiazine with clindamycin, azithromycin, clarithromycin or atovaquone.

Desensitization:

1°- Oral route in 5 days +/- corticosteroids

Day 1: 10 µg to 200 µg

Day 2: 300 µg to 8 mg

Day 3: 15 mg to 500 mg

Day 4: 500 mg: 1 x 4/day

Day 5: 500 mg: 2 x 4/day

Success rate: 62%

2°- Oral route in 10 days without corticosteroids

Day 1: 5 mg and 10 mg

Day 2: 20 mg and 40 mg

Day 3: 80 mg and 160 mg

Day 4: 250 mg and 500 mg

Day 5: 750 mg and 750 mg

Day 6: 1 g and 1 g

Day 7: 1 g/8 hours

Day 8: 1g/6 hours

Day 9: 1.5 g/6 hours

Day 10: 2 g/6 hours

Success rate: 100%

References

Hemstreet BA, Page RL 2nd. Sulfonamide allergies and outcomes related to use of potentially cross-reactive drugs in hospitalized patients. *Pharmacotherapy* 2006;26:551-7.

Gimnig JE, MacArthur JR, M'bang'ombe M, et al. Severe cutaneous reactions to sulfadoxine-pyrimethamine and trimethoprim-sulfamethoxazole in Blantyre District, Malawi. *Am J Trop Med Hyg* 2006;74:738-43.

Chaby G, Viseux V, Poulain JF, et al. Topical silver sulfadiazine-induced acute renal failure (Article in French). *Ann Dermatol Venereol* 2005;132:891-3.

Fisher NM, Marsh E, Lazova R. Scar-localized argyria secondary to silver sulfadiazine cream. *J Am Acad Dermatol* 2003;49:730-2.

Tenant-Flowers M, Boyle MJ, Carey D, et al. Sulphadiazine desensitization in patients with AIDS and cerebral toxoplasmosis. *AIDS* 1991;5:311-.5

Synergistin

A broad spectrum antibiotic (pristinamycin, the more common) which is active against staphylococcus, streptococcus, haemophilus, etc.

■ Incidence

Between 1984 and 1992, 35 adverse reactions, mainly cutaneous, were reported for 8 millions of boxes sold in France.

■ Risk factors

Contact dermatitis to virginiamycin

■ Clinical manifestations

- **General:** anaphylaxis (rare), angioedema, dyspnea, fever.

- **Cutaneous:**

Maculopapular, morbilliform, vesicular, purpuric rash

Erythroderma

Pruritus, urticaria

Acute generalized exanthematous pustulosis (frequent with pristinamycin)

Erythema multiforme, Stevens-Johnson syndrome, toxic epidermal necrolysis (rare)

■ Diagnostic methods

Skin tests: no reference available.

One case with positive skin test at a dilution of 1/10,000.

Patch tests: pristinamycin: 10 % in pet

Specific serum IgE: no assay commercially available.

Oral provocation tests

■ Mechanisms

Previous sensitization by virginiamycin after topical application

■ Management

Cross-reactions between synergistins: synergistins are composed of 2 chains (one depsipeptide and 1 macrocyclic lactone) with many structural analogies between all synergistins.

Avoidance of all synergistins.

References

Lammintausta K, Kortekangas-Savolainen O. The usefulness of skin tests to prove drug hypersensitivity. *Br J Dermatol* 2005;152:968-74.

Boniface S, Magnan A, Vervloet D, et al. *Pyostacin allergy: a case report (Article in French)*. *Rev Fr Allergol Immunol Clin* 2004;44:516-8.

Barbaud A, Trechot P, Weber-Muller F, et al. *Drug skin tests in cutaneous adverse drug reactions to pristinamycin: 29 cases with a study of cross-reactions between synergistins*. *Contact Dermatitis* 2004;50:22-6.

Michel M, Dompmartin A, Szczurko C, et al. *Eczematous-like drug eruption induced by synergistins*. *Contact Dermatitis* 1996;34:86-7.

Telithromycin

Telithromycin is a ketolide, a semisynthetic derivative of the 14-membered ring macrolide antibiotics, structural analogues of erythromycin.

■ Incidence

Rare

1 severe reaction per 1, 100.000 patients exposed

■ Clinical manifestations

• **General:** anaphylaxis.

• **Cutaneous** (infrequent): rash, pruritus, urticaria, angioedema, eczema, erythema multiforme, toxic epidermal necrolysis.

• **Others:** hepatotoxicity, visual disturbances (blurred vision, diplopia, accommodation difficulties).

■ Diagnostic methods

None

No evidence of specific IgE

■ Management

Avoidance.

References

Bédard MS, Gilbert M. Telithromycin-induced TEN: report of a case. *Arch Dermatol* 2007;143:427-8.

Bottenberg MM, Wall GC, Hicklin GA. Apparent anaphylactoid reaction after treatment with a single dose of telithromycin. *Ann Allergy Asthma Immunol* 2007;98:89-91.

Bertino JS. Severe hepatotoxicity of telithromycin. *Ann Intern Med* 2006;145:415.

Clay KD, Hanson JS, Pope SD, et al. Brief communication: severe hepatotoxicity of telithromycin: three cases reports and literature review. *Ann Intern Med* 2006;144:415-20.

Tetracycline group

The tetracycline antibiotics are a group of broad spectrum protein synthesis inhibiting compounds used in the treatment of Gram+ and Gram – infections, often used in acne treatment.

Natural tetracyclines: basic tetracycline, chlortetracycline, oxytetracycline

Semi-synthetic derivative of tetracycline: doxycycline, minocycline

A new glycycline, Tigecycline, covers a broad spectrum of Gram –, Gram+ and anaerobic pathogens.

■ Incidence

Uncommon.

Deaths reported.

Minocycline is the most widely incriminated molecule, with 72 adverse reactions per million of treatments and 13 adverse reactions per million for doxycyclin (USA).

Few data are available regarding the adverse effects of tigecycline, but it is mainly well tolerated.

■ Clinical manifestations

Adverse effects (mainly with minocyclin) include:

- Hypersensitivity reactions usually occur within a few weeks after the onset of treatment and may lead to exfoliative dermatitis, eosinophilic pneumopathy, pericarditis, nephropathy, lymphadenopathy, pseudoinfectious reactions, and blood eosinophilia ($>0.6 \times 10^9/l$).
- Autoimmune disorders usually present after exposure to minocycline for 1 year or more and include autoimmune hepatitis, autoimmune hemolytic anemia, thrombo-cytopenia, leukopenia, lupus, polyarteritis nodosa and vasculitis. Pigmentations of the skin, fingernails, bones, and teeth have also been described. Cases of scleral pigmentation presumed to have been induced by oral minocycline treatment have been reported.

- **General:** anaphylactic shock, serum sickness, fever, arthralgia, arthritis.

- **Respiratory:** bronchospasm.

- **Cutaneous:** pruritus, urticaria, angioedema, rash, fixed drug eruption, photosensitivity (cutaneous and ungueal with photoonycholysis), pigmentation (cutaneous, ungueal and mucosal), serum sickness (minocycline), erythema multiforme, Stevens-Johnson syndrome, toxic epidermal necrolysis (extremely rare), acute generalized exanthematous pustulosis, Sweet's syndrome, lichenoid eruption

Distinct syndromes:

Hypersensitivity syndrome or DRESS syndrome (minocycline > doxycycline and tetracyclines)

Lupus erythematosus (minocycline)

Polyarteritis nodosa (minocycline)

■ Diagnostic methods

Skin tests: none validated.

Intradermal skin tests: positive in one study with tetracycline.

Patch tests:

Doxycycline monohydrate: 10% in pet

Minocycline hydrochloride: 10% in pet

Specific serum IgE: none found

Challenge test is currently not recommended for patients who develop serious reactions.

I Mechanisms

Potential reactive metabolites generated by minocycline may bind to tissue macromolecules, thereby causing direct cell damage, or they may act as haptens.

I Management

Cross-reactivity between tetracycline/doxycycline and minocycline concerning fixed drug eruptions is not constant.

Patients who experienced a serious adverse event while receiving one of the tetracycline antibiotics must avoid all tetracyclines until more information is available.

Patients receiving long-term minocycline therapy should have antinuclear antibody and hepatic transaminase levels determined at baseline.

References

- Madan V, Lear JT. Minocycline-induced pigmentation of pre-existing capillaritis. *Br J Dermatol* 2007;156:590-1.
- Favrolt N, Bonniaud P, Collet E, et al. Severe drug rash with eosinophilia and systemic symptoms after treatment with minocycline (Article in French). *Rev Mal Respir* 2007;24:892-5.
- Marzo-Ortega H, Baxter K, Strauss RM, et al. Is minocycline therapy in acne associated with antineutrophil cytoplasmic antibody positivity? A cross sectional study. *Br J Dermatol* 2007;156:1005-9.
- Tehrani R, Nash-Goelitz A, Adals E, et al. Minocycline-induced cutaneous polyarteritis nodosa. *J Clin Rheumatol* 2007;13:146-9.
- Smith K, Leyden JJ. Safety of doxycycline and minocycline: a systematic review. *Clin Ther* 2005;27:1329.

Thiamphenicol

A broad-spectrum antimicrobial agent active against penicillin-resistant *Streptococcus pneumoniae*, *Staphylococcus aureus*, most methicillin-resistant isolates and atypical pathogens such as *Mycoplasma pneumoniae* and *Chlamydia pneumoniae*

■ Incidence

Uncommon.

■ Risk factors

Unknown.

■ Clinical manifestations

Pruritus

Contact dermatitis

Occupational asthma and rhinitis

■ Diagnostic methods

Skin tests: none validated

Positive skin prick tests in few cases

Specific serum IgE: no assay commercially available

Positive sIgE in few cases

■ Mechanisms

Unknown.

■ Management

Avoidance.

Possible cross-reactivity with chloramphenicol.

References

Serra A, Schito GC, Nicoletti G, et al. A therapeutic approach in the treatment of infections of the upper airways: thiamphenicol glycinate acetylcysteinate in sequential treatment (systemic-inhalatory route). *Int J Immunopathol Pharmacol* 2007;20:607-17.

Ye Y, Kim H, Suh C, et al. Three cases of occupational asthma induced by thiamphenicol: detection of serum-specific IgE. *Allergy* 2006;61:394-5.

Grassi C, De Benedetto F. Recent clinical evidence of the efficacy and safety of thiamphenicol glycinate acetylcysteinate and thiamphenicol glycinate. *J Chemother* 2002;14:279-84.

Sachs B, Erdmann S, Masaoudi T, et al. Molecular features determining reactivity in allergic contact dermatitis to chloramphenicol and azidam phenical. *Allergy* 2001;56:69-72

Le Coz CJ, Santinelli F. Facial contact dermatitis from chloramphenicol with cross-reactivity to thiamphenicol. *Contact Dermatitis* 1998;38:108-9.

Vancomycin and Teicoplanin

Vancomycin is a complex tricyclic glycopeptide obtained from the *Nocardia* species *Amycolatopsis orientalis*. It is frequently used in patients with Gram-positive bacterial infections. Preferred antimicrobial agent for the treatment of methicillin-resistant *Staphylococcus aureus*.

■ Incidence

Adults: 5 to 14%.

Children: 1.6 to 35%.

■ Risk factors

Association with narcotics.

Rapid infusion.

Age < 40 years: risk factor for infusion-related and delayed reactions.

Duration > 7 days: risk factor for delayed reactions.

■ Clinical manifestations

• *General:*

Red man syndrome or Red neck syndrome. Signs appear a few mins after the beginning of the injection or soon after the end of the infusion. Frequent with vancomycin and rare with teicoplanin. This reaction is associated to a rapid injection of the vancomycin (<1 hour). It is characterized by pruritus, flushing, erythematous rash (face, neck and upper thorax predominantly) associated to fever, chills and in severe cases to angioedema, hypotension.

• *Cutaneous:*

Pruritus, angioedema, urticaria, anaphylaxis (more rare than red man syndrome).

Delayed reactions (7-21 days)

Maculopapular rash (frequent with vancomycin and rare with teicoplanin) +/- fever +/- hypereosinophilia

Erythroderma

Erythema multiforme, Stevens - Johnson syndrome, Toxic epidermal necrolysis

Linear IgA bullous disease (mimicking sometimes toxic epidermal necrolysis)

DRESS syndrome

Fixed drug eruption (sometimes severe and extensive)

Acute generalized exanthematous pustulosis

Leucocytoclastic vasculitis, purpura with thrombocytopenia, Henock - Schoenlein purpura, vasculitis and lupus erythematosus

• *Others:* thrombocytopenia

One case with dyspnea, fever, hypoxia and eosinophilia (inhaled vancomycin used in decontamination of the respiratory tract in cases of allogenic bone marrow transplantation).

I Diagnostic methods

Skin tests: none validated. Evidence of positive skin tests in 4 studies.

Prick tests are usually negative.

Intradermal skin tests: a few cases with positive with 0.02 ml at 0.1 µg/ml have been reported.

Patch test: Vaneomycin 0.005% in water

Teicoplanin : 4% in water

Specific serum IgE: none available.

Basophil histamine release test.

One case reported with specific histamine release and cross-reactivity between vancomycin and teicoplanin.

I Mechanisms

“Red man syndrome” is due to histamine release into the blood by vancomycin with no antibody or complement involved. Hypotension is linked to peripheral vasodilatation following histamine release. Myocardial dysfunction is secondary to endogenous myocardial histamine release, or direct inotropic myocardial depression.

IgE-mediated hypersensitivity reactions have been demonstrated in a few cases.

I Management

Prevention of the “red man syndrome”:

Decreasing vancomycin doses.

Slowing infusion rate (no faster than 10 mg/min).

Pretreatment with an antihistamine (hydroxyzine 50 mg 2 hours before a vancomycin dose).

Desensitization: Successful

Slow: 0.5 mg/500 ml during 4 hours to 1000 mg/250 ml during 4 hours in 13 days

Fast: 0.0001 mg/ml to 10 mg/ml infusion in 100 minutes with pre-treatment by antihistamines.

Possible cross-reactivity between vancomycin and teicoplanin.

References

Campi P, Manfredi M, Severino M. IgE-mediated allergy to pyrazolones, quinolones and other non-beta-lactam antibiotics. In: Pichler WJ, ed. *Drug Hypersensitivity*. Basel: Karger, 2007;216-32.

Prey S, Sparsa A, Boumediene A, et al. Cutaneous drug reactions induced by glycopeptides (Article in French). *Med Mal Infect* 2007;37:270-4.

Tamagawa-Mineoka R, Katoh N, Nara T, et al. DRESS syndrome caused by teicoplanin and vancomycin, associated with reactivation of human herpesvirus-6. *Int J Dermatol* 2007;46:654-5.

Bouaziz JD, Valeyrie-Allanore L, Damak H, et al. Toxic epidermal necrolysis after vancomycin in a patient with terminal renal insufficiency: interest for intensive haemodialysis? *J Eur Acad Dermatol Venereol*. 2006 ;20: 1011-3.

- Coelho S, Tellechea O, Reis JP, et al. Vancomycin-associated linear IgA bullous dermatosis mimicking toxic epidermal necrolysis. *Int J Dermatol*. 2006;45:995-6.
- Kitazawa T, Ota Y, Kada N, et al. Successful vancomycin desensitization with a combination of rapid and slow infusion methods. *Intern Med*. 2006;45:317-21.
- Gilmore ES, Friedman JS, Morrell DS. Extensive fixed drug eruption secondary to vancomycin. *Pediatr Dermatol*. 2004;21:600-2.
- Waldman MA, Black DR, Callen JP. Vancomycin-induced linear IgA bullous disease presenting as toxic epidermal necrolysis. *Clin Exp Dermatol* 2004;29:633-6.
- Marraffa J, Guharoy R, Duggan D, et al. Vancomycin-induced thrombocytopenia: a case proven with rechallenge. *Pharmacotherapy*. 2003;23:1195-8.
- Joshi PP, Ahmed N. Fixed drug eruption with vancomycin. *Ann Pharmacother* 2002;36:1104.
- Bernedo N, Gonzalez I, Gastaminza G, et al. Positive patch test in vancomycin allergy. *Contact Dermatitis* 2001;45:43.
- Chu CY, Wu, Jean SS, et al. Acute generalized exanthematous pustulosis due to teicoplanin. *Dermatology* 2001;202:141-2.
- Khurana C, de Belder MA. Red-man syndrome after vancomycin: potential cross-reactivity with teicoplanin. *Postgrad Med J* 1999;75:41-3.

2• ANTIVIRAL DRUGS AND ANTIFUNGAL DRUGS

Amphotericin B

Liposomal preparations of amphotericin B have the advantage of lower toxicity compared with conventional preparations, and they have proved effective in the treatment of fungal infections including candida, aspergillus and cryptococcus.

In spite of the development of new antifungal drugs, amphotericin B deoxycholate remains the gold standard in the treatment of severe fungal infections in immunosuppressed hosts.

■ Incidence

Rare allergic reactions: 3/133 patients treated with amphotericin B deoxycholate; some cases with liposomal amphotericin B.

Hepatotoxicity in bone marrow transplant recipients: 0.78 cases per 100 patients-days of exposure to amphotericin deoxycholate.

Lower nephrotoxicity with liposomal amphotericin B compared to other amphotericins.

Liposomal amphotericin B induces fewer adverse events.

One case of fatal cardiac arrest.

■ Risk factors

AIDS.

■ Clinical manifestations

- **General:** anaphylactic shock.
- **Cutaneous:** acute generalized exanthematous pustulosis, maculo-papular rash sometimes severe.
- **Others:** nephrotoxicity, hepatotoxicity, cardiac toxicity, severe hypertension.
- **Respiratory:** dyspnea, tachypnea, stridor, bronchospasm, hemoptysis, hypoxemia.
- **Common adverse effects:** chills, fever, nausea, vomiting.

■ Diagnostic methods

None available.

Skin tests: no evidence of specific IgE by means of prick test or intradermal test.

Specific serum IgE: no evidence of specific serum IgE.

■ Mechanisms

This drug increases TNF-alpha concentrations in macrophages, increases INF-gamma, induces pros-

taglandins E2 synthesis and increases the production of interleukin-1 beta in mononuclear cells.

The lipid content of the drug is suspected to be the culprit.

I Management

In most cases of liposomal amphotericin B reactions, switching to a different lipid formulation of amphotericin B is advised. Paradoxically, in some patients lipid formulations may be less well tolerated than conventional amphotericin B.

References

Heinemann C, Wiesend CL, Hipler C, et al. Acute generalized exanthematous pustulosis (AGEP) after oral use of amphotericin B. *J Am Acad Dermatol* 2007;57:S61-3.

Fischer MA, Winkelmayer WC, Rubin RH, et al. The hepatotoxicity of antifungal medications in bone marrow transplant recipients. *Clin Infect Dis* 2005;41:301-7.

Lowery MM, Greenberger PA. Amphotericin-induced stridor: a review of stridor, amphotericin preparations, and their immunoregulatory effects. *Ann Allergy Asthma Immunol* 2003;91:460-6.

Vaidya SJ, Seydel C, Patel SR, et al. Anaphylactic reaction to liposomal amphotericin B. *Ann Pharmacother* 2002;36:1480-1.

Bishara J, Weinberger M, Lin AY, et al. Amphotericin B-not so terrible. *Ann Pharmacother* 2001;35:308-10.

ANTI-HERPES AND ANTI-CMV

1) Acyclovir and Valaciclovir

Acyclovir is a structural analogue of desoxyguanosine which inhibits viral DNA – polymerase and is widely used as an antiviral drug in herpes and herpes - zoster infections.

■ Incidence

Rare.

■ Risk factors

AIDS.

Repeated topical use.

■ Clinical manifestations

• *Cutaneous:*

They are observed with topical use: irritating dermatitis and contact dermatitis, often unrecognized, because imputed to an increase of the initial herpes, photoallergic contact dermatitis.

Systemic administration: generalized eczema, vesicular eruption, phlebitis, urticaria.

■ Diagnostic methods

Skin tests

Patch-tests with the antiviral topical drug and with detail of the constituents: acyclovir 10% in pet, propylene glycol 5% in pet, poloxamere 407 10% in pet, cetyl stearyl alcohol 20% in pet, sodium lauryl sulfate 1% in water. Readings: 30 mins, 48 H, 72 H and 96 H.

Valaciclovir: commercialized form (30% in pet, water, alcohol).

Photopatch - tests.

Some cases of sensitization are due to vehicle constituents (propylene glycol).

■ Mechanisms

Delayed contact dermatitis.

■ Management

Avoidance.

After contact dermatitis, cross reaction when systemic administration with acyclovir, valaciclovir and famciclovir. Foscarnet and cidofovir could be an alternative.

References

Vernassiere C, Barbaud A, Trechot PH, et al. Systemic acyclovir reaction subsequent to acyclovir contact allergy: wick systemic antiviral drug should then be used? *Contact Dermatitis* 2003;49:155 -157

Serpentier – Daude A, Collet E, Didier AF, et al. Contact dermatitis to topical antiviral drugs (Article in French). *Ann Dermatol Venereol* 2000;127:91-193.

2) Foscarnet

Antiviral (DNA and RNA polymerase inhibitor)

I Clinical manifestations

• *Cutaneous:*

Penile ulceration (frequent), vulvar ulceration

Oral ulcerations (less frequent)

Maculopapular rash

Pruritus

Urticaria (rare)

Toxic epidermal necrolysis (rare)

Fixed drug eruption (rare)

Injection site reaction

3) Cidofovir

Antiviral

Nucleotid analog

Indications: CMV retinitis in patients with AIDS (infusion)

Case reports of use of topical cidofovir (gel 1%) and intralesional cidofovir in cutaneous viral infections

I Clinical manifestations

• *Cutaneous:*

Alopecia (frequent)

Rash, pruritus, urticaria

Pigmentation

Stomatitis

Applications site reactions (frequent and occasionally severe)

References

Toutous-Trellu L, Hirschel B, Piquet V, et al. Treatment of cutaneous human papilloma virus, poxvirus and herpes simplex virus infections with topical cidofovir in HIV positive patients (Article in French). *Ann Dermatol Venereol* 2004;131:445-449.

4) Ganciclovir

Antiviral
Guanine nucleoside analog

I Clinical manifestations

• *Cutaneous:*

Injection site reactions
Cutaneous rash, pruritus, urticaria
Alopecia

I Diagnostic methods

Skin tests

Patch tests: as is, 20% in pet
Interest to study cross reactivity with acyclovir.

5) Famciclovir

Antiviral
Guanine nucleoside analog

I Clinical manifestations

• *Cutaneous:*

Rash, pruritus, urticaria, vasculitis.

I Diagnostic methods

Skin tests

Patch tests: 50 % in pet (commercialized form).

References

Ali SO, McCarty RD, Davis BM. Case reports: cutaneous small vasculitis due to famciclovir therapy. *J Drugs Dermatol* 2005;4:486-489

Fluconazole

Fluconazole is a triazole antifungal agent used in the treatment of infections of the nails, skin, oral and vaginal mucosa; systemic candidiasis, cryptococcal meningitis and as prophylaxis for cryptococcal infections in HIV patients.

I Incidence

Probably very low.

I Risk Factors

AIDS (Stevens-Johnson syndrome and toxic epidermal necrolysis)

I Clinical manifestations

• **General:** anaphylactic shock.

• **Cutaneous:** rash, acute generalized exanthematous pustulosis, fixed drug eruption, erythema multiforme, Stevens-Johnson syndrome and toxic epidermal necrolysis.

• **Others:** hepatitis.

I Diagnostic methods

Skin tests: none validated

One case with positive skin prick tests 1/10.

Patch tests with fluconazole 10% in petrolatum applied at the site of previous lesion (fixed drug eruption).

Specific serum IgE: no evidence of specific serum IgE.

I Mechanisms

Unknown.

I Management

Cross-reactivity with other azole derivatives is likely.

Desensitization (orally): 0.2 mg to 400 mg in 15 days, with doubling doses each day.

References

Dalle S, Skowron S, Ronger-Savla B, et al. Erythema multiforme induced by fluconazole. *Dermatology* 2005;211:169.

Su FW, Perumalswani P, Grammer LC. Acute hepatitis and rash to fluconazole. *Allergy* 2003;58:1215-6.

Fabre B, Albès B, Belhadjali H, et al. Acute generalized exanthematous pustulosis due to fluconazole (Article in French). *Ann Dermatol Venereol* 2002;129:294-7.

Akahashi T, Hitani A, Yamada H, et al. Desensitisation to fluconazole in an AIDS patient. *Ann Pharmacother* 2001;35:642-3.

Heikkilä H, Timonen K, Stubb S. Fixed drug eruption due to fluconazole. *J Am Acad Dermatol* 2000;42:883-4.

Craig TJ, Peralta F, Boggavarapu J. Desensitization for fluconazole hypersensitivity. *J Allergy Clin Immunol* 1996;98:845-6.

FUSION INHIBITOR

Enfuvirtide

■ Incidence

Less than 1% of HIV-infected patients

■ Clinical manifestations

• *Cutaneous:*

Local reaction at the site of injection in the majority of cases (98%): erythema, pain, pruritus (frequent), mild induration, nodules, granuloma, urticaria, vasculitis

Rash delayed days to weeks after the drug initiation

• *Others:*

Any documented immediate hypersensitivity reactions except in one case with chest tightness, fever, diffuse myalgias, shortness of breath, nausea few minutes after taking the first dose.

■ Diagnostic methods

No *in vitro* or *in vivo* tests are available

■ Mechanisms

Unknown.

■ Management

Avoidance.

Desensitization possible for isolated generalized severe rash: beginning doses of 0.0009mg are doubled to 90mg at 30-minute intervals, followed by a full dose challenge.

References

Shahar E, Moar C, Pollack S. Successful desensitization of enfuvirtide induced skin hypersensitivity reaction. *AIDS* 2005;19:451-452

DeSimone JA, Ojha A, Pathak R, et al. Successful desensitization to enfuvirtide after a hypersensitivity reaction in an HIV-1 infected man. *Clin Infect Dis* 2004;39:110-112

Ball RA, Kinchelov Y, ISR Substudy group. Injection site reactions with the HIV-1 fusion inhibitor enfuvirtide. *J Am Acad Dermatol* 2003;49:826-831

INTEGRASE INHIBITOR

Raltegravir

An HIV-1 integrase strand transfer inhibitor which has been shown to be active against multidrug-resistant HIV-1

■ Incidence

Safety profile

Pruritus in 4 to 9% of patients

■ Clinical manifestations

Pruritus

No rashes reported

No hypersensitivity reactions reported

■ Diagnostic methods

No *in vitro* or *in vivo* tests are available

References

Grinsztejn B, Nguyen BY, Katlama C, et al. For the protocol 005 Team. Safety and efficacy of the HIV-1 integrase inhibitor raltegravir(MK-0518) in treatment-experienced patients with multidrug-resistant virus: a phase II randomized controlled trial. *Lancet* 2007;369:1261-9.

Itraconazole

First-generation triazole antifungal agent used for treatment of histoplasmosis, coccidioidomycosis, paracoccidioidomycosis, sporotrichosis, candidosis and aspergillosis.

■ Incidence

Probably low.

■ Clinical manifestations

- **Cutaneous:** urticaria, angioedema, purpuric drug eruption, maculopapular eruption, acute generalized exanthematous pustulosis, photosensitivity (rare), fixed drug reaction (rare)
- **Others:** hepatotoxicity, serum sickness-like illness

■ Diagnostic methods

None

Skin tests: no evidence of specific IgE by means of prick test or intradermal test.

Specific serum IgE: no evidence of specific serum IgE.

Challenge test.

In one case of photosensitivity, oral photo-challenge using itraconazole and sun irradiation was positive but photopatch test was negative.

■ Mechanisms

Unknown.

■ Management

Desensitization: 1 mg to 200 mg over 4 hours.

References

- Gupta R, Thami GP. Fixed drug eruption caused by itraconazole: reactivity and cross reactivity. *J Am Acad Dermatol* 2008;58:521-2.
- Martinez-Alonso JC, Dominguez-Ortega FJ, Fuentes-Gonzalo MJ. Urticaria and angioedema due to itraconazole. *Allergy* 2003 58:1317-8.
- Alvarez-Fernandez JG, Castano-Suarez E, Cornejo-Navarro P, et al. Photosensitivity induced by oral itraconazole. *J Eur Acad Dermatol Venereol* 2000;14:501-3.
- Douglas R, Spelman D, Czarny D, et al. Desensitization to itraconazole. *J Allergy Clin Immunol* 1997; 99:269.
- Park YM, Kim JW, Kim CW. Acute generalized exanthematous pustulosis induced by itraconazole. *J Am Acad Dermatol* 1997;36:794-6.

Ketoconazole

Ketoconazole is a synthetic imidazole derivative antifungal agent used in the treatment of systemic and subcutaneous mycosis; also effective in the treatment of dermatophytosis and superficial mycosis.

I Incidence

Very low.

I Clinical manifestations

- **General:** anaphylactic shock.

- **Cutaneous:**

Topical use: irritant and contact dermatitis (rare)

Systemic use: pruritus, cutaneous rash, urticaria and angioedema, fixed drug eruption, purpura

I Diagnostic methods

Skin tests

Prick tests with 1, 10, 20, 40 mg/ml positive with a concentration of 10 mg/ml in a patient with allergic reaction to ketoconazole.

Patch tests: ketoconazole cream, excipients (propylene glycol)

Specific serum IgE: no evidence of specific serum IgE.

Histamine release test was positive in the same patient.

Challenge test:

Oral challenge: 25 mg, 50 mg, 100 mg, 200 mg.

I Mechanisms

IgE-mediated hypersensitivity is likely.

Cross-reactivity with other azole derivatives is possible, but has not been demonstrated.

I Management

Avoidance.

References

Liu PY, Lee CH, Lin LJ, et al. Refractory anaphylactic shock associated with ketoconazole treatment. *Ann Pharmacother* 2005;39:547-50.

Gonzalez-Delgado P, Florido-Lopez F, Saenz de San Pedro B, et al. Hypersensitivity to ketoconazole. *Ann Allergy* 1994;73:326-8.

Valsecchi R, Pansera B, di Landro A, et al. Contact dermatitis from ketoconazole. *Contact Dermatitis* 1993;29:162.

Metronidazole

A nitroimidazole derivative used for the treatment of anaerobic infections and trichomonas infections.

■ Incidence

Uncommon.

The most common reactions are urticaria (47%) and facial edema (11%)

■ Clinical manifestations

- **General:** anaphylaxis (exceptional)

- **Cutaneous:** pruritus, flush, cutaneous reaction with fever (serum sickness), maculopapular rash, urticaria, angioedema, fixed drug eruption, pityriasis rosea-like drug eruption.

Metronidazole in combination with spiramycine: acute generalized exanthematous pustulosis, more frequent than with metronidazole alone

- **Respiratory:** bronchospam.

■ Diagnostic methods

Skin tests

One positive skin prick test

Patch tests may be used in patients with acute generalized exanthematous pustulosis (with careful).

Topical provocation testing in patients with fixed drug eruption.

Challenge test:

This may demonstrate the responsibility of metronidazole. It may also induce early and delayed cutaneous exanthemas. They are not indicated in cases of anaphylaxis and acute generalized exanthematous pustulosis.

■ Mechanisms

IgE-mediated hypersensitivity is likely in some cases.

■ Management

Cross-reactivity between metronidazole and tinidazole (fixed drug eruption) and between metronidazole and isothiazolonone.

Desensitization.

Two different protocols have been published:

- 0.0025 mg to 1,000 mg in 8 steps (orally)
- 5 µg to 125 mg intravenously (3h40), then 250 mg, 500 mg, 2 g orally (3 h).

References

Helms DJ, Mosure DJ, Secor WE, et al. Management of *Trichomonas vaginalis* in women with suspected metronidazole hypersensitivity. *Am J Obstet Gynecol* 2008;198:370.

Garcia-Rubio I, Martinez-Cocera C, Santos Magadan S, et al. Hypersensitivity reactions to metronidazole. *Allergol Immunopathol* 2006;34:70-2.

Wolf R, Orion E, Matz H. Co-existing sensitivity to metronidazole and isothiazolinone. *Clin Exp Dermatol* 2003; 28:506-7.

Vila JB, Bernier MA, Gutierrez JV, al. Fixed drug eruption caused by metronidazole. *Contact Dermatitis* 2002;46:122.

Pearlman MD, Yashar C, Ernst S, et al. An incremental dosing protocol for women with severe vaginal trichomoniasis and adverse reactions to metronidazole. *Am J Obstet Gynecol* 1996;174:934-6.

NON-NUCLEOSIDE Reverse Transcriptase Inhibitors (NNRTIs)

1) Nevirapine

■ Incidence

13% of patients develop mild rashes.

Stevens-Johnson syndrome occurs in 0.3% of patients on nevirapine but rarely with the other NNRTIs.

■ Risk factors

AIDS: 1000-fold higher risk of developing severe cutaneous reactions

Higher pre-treatment CD4+T count(>250cells/mm³ for women and > 400cells/mm³ for men)

Plasma RNA copies > 10,000 copies/ml

Chinese ethnicity

Female sex

■ Clinical manifestations

• *Cutaneous:*

Most frequently within the first 6 weeks of therapy.

Urticaria, angioedema, anaphylactoid reactions

Maculopapular exanthemas with or without pruritus (occurred in median 15 days after the initiation of treatment; frequent: 20%)

Stevens-Johnson syndrome, toxic epidermal necrolysis (fatal cases)

Hypersensitivity syndrome (fatal cases)

• *Others:* Hepatotoxicity: transaminases increased in 7% of patients with 1% of hepatitis

■ Mechanisms

No clear mechanistic understanding exists.

A CD4+T-cell-dependent immune response to nevirapine hypersensitivity has been postulated because a predisposition to nevirapine hypersensitivity is associated with HLA-DRB1*0101.

■ Diagnostic methods

No *in vitro* or *in vivo* tests are available.

Challenge test: contraindicated.

■ Management

Avoidance.

Corticosteroids and antihistamines are not effective in reducing the incidence of rash.

Slow introduction of nevirapine reduces the risk of rash.

Approximately half of patients with mild or moderate rash can continue nevirapine therapy under close supervision (desensitization).

References

- Pitche P, Drobacheff – Thiebaut C, Gavignet B, et al. Cutaneous drug-reactions to nevirapine: study of risk factors in 101 HIV-infected patients (Article in French). *Ann Dermatol Venereol* 2005;132:970-974.
- Knobel H, Miro JM, Mahillo B, et al. Failure of cetirizine to prevent nevirapine-associated rash: a double-blind placebo-controlled trial for the GESIDA 26/01 Study. *J Acquir Immune Defic Syndr* 2004;37:1276-1281
- Rotunda A, Hirsch RJ, Scheinfeld N, et al. Severe cutaneous reactions associated with the use of human immunodeficiency virus medications. *Acta Derm Venereol* 2003;83:1-9
- Fagot JP, Mochenhaupt M, Bouwes - Bavinck JN, et al. Nevirapine and the risk of Stevens - Johnson syndrome or toxic epidermal necrolysis. *AIDS* 2001;15:1843-1848
- Knobel H, Miro JM, Domingo P, et al. GESIDA 09/99 Study group. Failure of a short-term prednisone regimen to prevent nevirapine-associated rash: a double-blind placebo-controlled trial. *J Acquir Immune Defic Syndr* 2001;28:14-18
- Metry DW, Lahart CJ, Farmer KL, et al. Stevens-Johnson syndrome caused by a antiretroviral drug nevirapine. *J Am Acad Dermatol* 2001;44(suppl):354-357
- Max B, Sherer R: Management of the adverse effects of antiretroviral therapy and medication adherence. *Clin Infect Dis* 2000;30(suppl2):S96-S116
- Ganger M, Arias G, O'Brien Jg, et al. Frequency of cutaneous reactions on rechallenge with nevirapine and delavirdine. *Ann Pharmacother* 2000;34:839-842

2) Efavirenz

I Incidence

Hypersensitivity ranges between 10% and 34%.
6% to 8.5% of rashes.

I Clinical manifestations

Maculopapular rash: frequent (20 %); occurred in median 15 days after the initiation of treatment; may disappeared despite the continuation of the therapy

Pruritus, urticaria

Photosensitivity

Erythema multiforme, Stevens-Johnson syndrome

- **Others:** internal organ involvement. Hepatotoxicity.

I Diagnostic methods

No *in vitro* or *in vivo* tests are available.

Photosensitive drug eruption diagnosed by patch test with light exposure have been reported

I Management

Avoidance in severe rash or systemic reaction. More than 90% of HIV-infected patients with CD4 counts <200cells/mm³ who had previously rash tolerate efavirenz well.

Efavirenz may be used in patients who had a previously nevirapine associated rash.
Desensitization: 14-days protocol

References

Manosuthi W, Thongyen S, Chumpathat K, et al. Incidence and risk factors of rash associated with efavirenz in HIV infested patients with preceding nevirapine associated rash. HIV Med 2006; 7:378-382

Yoshimoto E, Konishi M, Takahashi K, et al. The first case of efavirenz-induced photosensitivity in a Japanese patient with HIV infection. Intern Med 2004;43:630-631

Phillips EJ, Kuriakose B, Knowles SR. Efavirenz-induced skin eruption and successful desensitization. Ann Pharmacother 2002;36:430-432

NUCLEOSIDE reverse transcriptase inhibitors

1) Abacavir

A HIV-1 reverse transcriptase inhibitor

■ Incidence

Life-threatening reaction occurs in both adults and children in 5% to 8% of HIV-infected treated patients.

Mortality rate is 0.03%.

■ Risk factors

Dominant risk factor: presence of a specific HLA-B*5701 represents the dominant risk factor among Caucasian and Hispanic populations.

■ Clinical manifestations

• *Cutaneous:*

Rash without systemic reaction, occurs in 15% of patients. This benign cutaneous reaction needs to be distinguished from hypersensitivity syndrome.

Hypersensitivity syndrome:

Adverse effects occurs after a mean of 11 days (less than 6 weeks after exposure) and resolving within 72 hours of withdrawal of the drug.

They are characterized by fever, rash, gastrointestinal (nausea, vomiting, diarrhoea), mouth/throat, respiratory and musculoskeletal symptoms (myalgia, arthralgia), as well as malaise, lymphadenopathy, paresthesia and fatigue.

Others cutaneous reactions: anaphylactoid reaction, Sweet syndrome, Stevens - Johnson syndrome, toxic epidermal necrolysis.

■ Diagnostic methods

Skin tests

Patch test: no standardization and with extreme care in hypersensitivity syndrome.

■ Mechanisms

A putative metabolite has been suspected, but whether this is involved in the immune reaction is unclear. In a prospective study of abacavir naive patients, genotyping for HLA-B*5701 was able to prevent hypersensitivity reaction.

■ Management

Avoidance because death is possible with accidental reintroduction.

References

- Mallal S, Phillips E, Carosi G, et al. HLA-B*5701 screening for hypersensitivity to Abacavir. *New Engl J Med* 2008;358:568-579
- Rauch A, Nolan D, Martin A, et al. Prospective genetic screening decreases the incidence of abacavir hypersensitivity in the Western Australian HIV cohort study. *Clin Infect Dis* 2006;43:99-102
- Montero M, Garcia-Gibert L, Gimenez-Arnau AM, et al. Toxic epidermal necrolysis associated with abacavir (Article in Spanish). *Enferm Infect Microbiol Clin* 2005;23:247.
- Phillips EJ, Wong GA, Kaul R, et al. Clinical and immunogenetic correlates of abacavir hypersensitivity. *AIDS* 2005;10:979-981
- Del Giudice P, Vandenbos F, Perrin C, et al. Sweet's syndrome following abacavir therapy. *J Am Acad Dermatol* 2004;51:474-475
- Mallal S, Nolan D, Witt V, et al. Association between presence of HLA-B*5701, HLA-DR7, and HLA-DQ3 and hypersensitivity to HIV-1 reverse-transcriptase inhibitor abacavir. *Lancet* 2002;359:727-732
- Walsh JS, Reese MJ, Thurmond LM: The metabolic activation of abacavir by human liver cytosol and expressed human alcohol dehydrogenase isozymes. *Chem Biol Interact* 2002;142:135-154
- Bossi P, Roujeau JC, Bricaire F, et al. Stevens - Johnson syndrome associated with abacavir therapy. *Clin Infect Dis* 2002;35:902
- Hetherington S, McGuirk S, Powell G, et al. Hypersensitivity reactions during therapy with the nucleoside reverse transcriptase inhibitor abacavir. *Clin Ther* 2001;23:1603-1614
- Frissen PH, de Vries J, Weigel HM, et al. Severe anaphylactic shock after rechallenge with abacavir without preceding hypersensitivity. *AIDS* 2001;5:289

2) Zidovudine

Dideoxynucleoside analog of thymidine, acting as a virostatic drug against HIV by interfering with viral reverse transcriptase.

■ Incidence

Few cases of zidovudine allergy have been published.

■ Risk factors

Unknown.

In few cases zidovudine hypersensitivity had a previously documented drug allergy to TMP-SMX or other antibiotics.

■ Clinical manifestations

• *Cutaneous:*

Acute generalized exanthematous pustulosis (with lamivudine)
Maculopapular rash
Pruritus, urticaria, edema of lip

Erythema multiforme, Stevens - Johnson syndrome, toxic epidermal necrolysis
Cutaneous pigmentation, nails pigmentation, oral and tongue pigmentation
Oral lichenoid eruption
Leukocytoclastic vasculitis

• **Others:**

Bronchospasm
Fever
Hepatitis
Renal abnormalities

▮ **Diagnostic methods**

No *in vitro* or *in vivo* tests are available.

▮ **Mechanisms**

Unknown.
Possible production of toxic metabolites (like sulfonamides).

▮ **Management**

Avoidance.
The protective effect of corticosteroids is controversial.
Desensitization possible: 0.008mg to 1200mg in one month or 10mg to 500mg I 10 days.

References

- Aquilina C, Viraben R, Roueire A. Acute generalized exanthematous pustulosis: a cutaneous adverse effect due to prophylactic antiviral therapy with protease inhibitor. *Arch Intern Med* 1998;158:2160-2161
- Duque D, de la Puente J, Rodriguez F, et al. Zidovudine-related erythroderma and successful desensitization: a case report. *J. Allergy. Clin. Immunol.*, 1996;98:234-5
- Wassef M, Keiser P. Hypersensitivity of zidovudine: report of a case of anaphylaxis and a review of the literature. *Clin Infect Dis* 1995;20(5):1387-1389
- Carr A, Penny R, Cooper D.A. Allergy and desensitization to zidovudine in patients with acquired immunodeficiency syndrome (AIDS). *J. Allergy. Clin. Immunol.*, 1993;91(2):683-85
- Mc Kinley G.F, Mazza D.S, Grieco M.H. Urticarial reaction to zidovudine, *Lancet.*, 1990;336:384

3) Didanosine

▮ **Incidence**

Rare

▮ **Clinical manifestations**

• **Cutaneous:**

Pruritus, urticaria
Rash
Erythema multiforme, Stevens - Johnson syndrome, toxic epidermal necrolysis

Purpura, vasculitis

I Mechanisms

Non-IgE-mediated reaction

I Management

Avoidance.

References

Rotunda A, Hirsch RJ, Scheinfeld N, et al. Severe cutaneous reactions associated with the use of human immunodeficiency virus medications. *Acta Derm Venereol* 2003;83:1-9

Herranz P, Fernandez-Diaz ML, de Lucas R, et al. Cutaneous vasculitis associated with didanosine. *Lancet* 1994; 344:680

Parneix-Spake A, Bastuji-Garin S, Levy Y, et al. Didanosine as a probable cause of Stevens Johnson Syndrome. *Lancet* 1992;340:857-858

4) Lamivudine

I Incidence

Rare

I Clinical manifestations

• **General:** Anaphylactoid reactions

• **Cutaneous:**

Acute generalized exanthematous pustulosis (with zidovudine)

Pruritus, rash, angioedema, urticaria

Allergic contact dermatitis

Ichthyosiform eruption

I Diagnostic methods

No *in vitro* or *in vivo* tests are available.

References

Kaptanoglu AF, Kutluay L. Ichthyosiform eruption associated with lamivudine in a patient with chronic hepatitis-B infection. *Int J Clin Pract* 2005;59:1237-1238

Smith K, Buckley R, Skelton H. Lamivudine (3TC)-induced contact dermatitis. *Cutis* 2000;65:227-229

Aquilina C, Viraben R, Roueire A. Acute generalized exanthematous pustulosis: a cutaneous adverse effect due to prophylactic antiviral therapy with protease inhibitor. *Arch Intern Med* 1998;158:2160-2161

Kainer M, Mijch A. Anaphylactoid reaction, angioedema and urticaria associated with lamivudine. *Lancet* 1996;348:1519

PROTEASE INHIBITORS

1) Atazanavir

Azapeptide protease inhibitor

■ Incidence

Rash reported in 20% of patients.

■ Clinical manifestations

• *Cutaneous:*

Skin rash

Others and rare: pruritus, urticaria, vesiculobullous eruption, eczema, peripheral edema, purpura, photosensitivity

■ Diagnostic methods

No *in vitro* or *in vivo* tests are available.

■ Mechanisms

Unknown.

■ Management

In some cases, medication was continued and there was resolution of the rash. Lopinavir-ritonavir can be tolerated.

References

Ouagari Z, Tubiana R, Mohand HA et al. Skin rash associated with atazanavir : report of three cases. *AIDS* 2006; 20: 1207-8

Bonfanti P, Capetti A, Riva P, et al. Hypersensitivity reactions during antiretroviral regimens with protease inhibitors. *AIDS* 1997;11:1301-1302

2) Amprenavir or fosamprenavir

■ Incidence

3% of patients

I Clinical manifestations

• Cutaneous:

Maculopapular rash frequent (25 %)

Erythematous, maculopapular rash, pruritus (occurring two weeks after initiation of therapy; resolution of the rash is possible despite the continuation of the molecule; association with efavirenz increases the risk of cutaneous rash)

Stevens - Johnson syndrome

I Diagnostic methods

No *in vitro* or *in vivo* tests are available.

References

Rotunda A, Hirsch RJ, Scheinfeld N, et al. Severe cutaneous reactions associated with the use of human immunodeficiency virus medications. *Acta Derm Venereol* 2003;83:1-9

3) Indinavir, Ritonavir, Lopinavir

I Incidence

Hypersensitivity reactions rarely reported.

I Risk factors

Female sex

I Clinical manifestations

• Cutaneous:

Pruritus (frequent), urticaria

Maculopapular rash (apparition delayed or several hours after introduction of the molecule; clinical improvement is possible despite continuation of the therapy), frequent (20 %)

Acute generalized exanthematous pustulosis (lopinavir - ritonavir)

Leucocytoclastic vasculitis

Erythema multiforme, Stevens - Johnson syndrome

Others cutaneous effects such as cheilitis, diffuse cutaneous dryness (frequent), asteototic dermatitis, scalp defluvium, pyogenic granulomas, peripheral lipodystrophy, pigmentation

I Diagnostic methods

No *in vitro* or *in vivo* tests are available.

References

Ghosn J, Duvivier C, Tubiana R, et al. Acute generalized exanthematous pustulosis induced by HIV postexposure prophylaxis with lopinavir - ritonavir. *Clin Infect Dis* 2005;41:1360-1361

Rotunda A, Hirsch RJ, Scheinfeld N, et al. Severe cutaneous reactions associated with the use of human immunodeficiency virus medications. *Acta Derm Venereol* 2003;83:1-9

Rachline A, Lariven S, Descamps V, et al. Leucocytoclastic vasculitis and indinavir. *Br J Dermatol* 2000; 143:1112-1113

Calista D, Boschini A. Cutaneous side effects induced by indinavir. *Eur J Dermatol* 2000;10:292-296

Fung HB, Pecini RA, Brown ST, et al. Indinavir - associated maculopapular eruption. *Pharmacotherapy* 1999;19:1328-1330

Bachmeyer C, Blum L, Cordier F, et al. Early ritonavir - induced maculopapular eruption. *Dermatology* 1997;139:301-302

4) Nelfinavir

■ Incidence

Low.

Rash reported to be <5%

■ Clinical manifestations

• *Cutaneous:*

Maculopapular rash: 5 days to 6 weeks

Urticaria, pruritus

■ Diagnostic methods

No *in vitro* or *in vivo* tests are available

■ Management

Cross reactivity reported between nelfinavir and indinavir in some cases.

Desensitization possible: One day desensitization with dose escalation from 25µg or 500µg to 750 to 1000mg. A 3-week protocol with a initial dose of 250mg with escalation in dosing by 250mg every 3 days until a dose of 750 mg 3 times daily was achieved.

References

Woolley I., Tapley N., Korman TM. Sequential cutaneous drug reactions to protease inhibitors in the context of occupational post-exposure prophylaxis. *AIDS* 2003;17:1709-1715

Abraham PE, Sorensen SJ, Baker WH, et al. Nelfinavir desensitization. *Ann Pharmacother* 2001;35:553-556

Demoly P, Messaad D, Trylesinski A, et al. Nelfinavir-induced urticaria and successful desensitization. *J Allergy Clin Immunol* 1998;102:875-876

5) Saquinavir

■ Clinical manifestations

• *Cutaneous:*

Adverse skin reactions: rare

Pruritus, urticaria, rash, papulovesicular eruption, photosensitivity, pigmentation

Fixed drug eruption

Erythema multiforme

Oral ulceration

References

Smith KJ, Yeager J, Skelton H. Fixed drug eruption to human immunodeficiency virus - 1 protease inhibitor. *Cutis* 2000;66:29-32

Garat H, el Sayed F, Obadia M, et al. Erythema multiforme caused by saquinavir (Article in French). *Ann Dermatol Venereol* 1998;125:42-43.

Terbinafine

A class of allylamine antifungal agents which is used extensively to treat onychomycoses and other dermatomycoses. This fungicide blocks squalene oxydase and thus acts on sterol chains, leading to a deficit in ergosterol, an essential fungal membrane component.

I Incidence

Adverse reactions may occur in about 10% of the patients.
Severe cutaneous side-effects: 1/10,0000.

I Clinical manifestations

• **Cutaneous:** pruritus, fixed drug eruption, cutaneous rash, exacerbation of eczema, erythroderma, pityriasis rosea Gibert, exacerbation of psoriasis, acral pustular psoriasis, severe psoriasis. The most serious reactions include erythema multiforme, Stevens-Johnson syndrome, toxic epidermal necrosis, drug hypersensitivity syndrome, and acute generalized exanthematous pustulosis. Finally, cases of induced subacute lupus or exacerbation of pre-existing lupus have been reported as well as undesirable sensory symptoms.

I Diagnostic methods

Skin tests

Patch tests: not standardized

In cases with acute generalized exanthematous pustulosis, patch test positive at 6 days confirmed the diagnosis.

I Mechanisms

Unknown.

I Management

Avoidance.

References

- Beltraminelli HS, Lerch M, Arnold A, et al. Acute generalized exanthematous pustulosis induced by the antifungal terbinafine: case report and review of the literature. *Br J Dermatol* 2005;152:780-3.
- Gupta AK, Lynde CW, Lauzon GJ, et al. Cutaneous adverse effects associated with terbinafine therapy: 10 cases reports and a review of the literature. *Br J Dermatol* 1998;138:529-32.
- Kempinaire A, De Raeve L, Merckx M, et al. Terbinafine-induced acute generalized exanthematous pustulosis confirmed by a positive patch result. *J Am Acad Dermatol* 1997;37:653-5.

Voriconazole

Voriconazole, a selective inhibitor of fungal cytochrome p-450, is a relatively new second-generation triazole antifungal agent, with a broad-spectrum activity against yeasts and moulds, including *Aspergillus* species.

I Clinical manifestations

- **Cutaneous:** facial erythema, cheilitis, erythema multiforme, Stevens-Johnson syndrome and toxic epidermal necrolysis, photosensitivity reactions, discoid lupus erythematosus-like lesions, fixed drug eruption, exfoliative dermatitis eczema urticaria.

Photosensitivity reactions are an original cutaneous secondary effect that has been reported with this second generation triazole. Their onset occurs from after 5 weeks up to 14 months after the beginning of treatment, owing to exposure to even a small amount of sunlight. These reactions can be severe. The lesions disappear rapidly after treatment has been stopped. Pseudoporphyric-type photosensitivity reactions (simulating porphyria cutanea tarda) have been reported.

- **Others:** hepatotoxicity, retinal flashes, neurological symptoms (parasthesias).

I Diagnostic methods

No methods available.

I Mechanisms

Elevated serum retinoid levels have been reported in subjects presenting with cheilitis and facial erythema-type adverse effects, similar to reactions that have been observed in patients treated with retinoids over a long period.

I Management

Patients should be informed of the risk of photosensitivity and induction of cancer. External photo-protection is indispensable.

References

Kwong WT, Hsu S. Pseudoporphyria associated with voriconazole. *J Drugs Dermatol* 2007;6: 1042-4.

Curigliano G, Formica V, De Pas T, et al. Life-threatening toxic epidermal necrolysis during voriconazole therapy for invasive aspergillosis after chemotherapy. *Ann Oncol* 2006;17:1174-5.

Jain LR, Denning DW. The efficacy and tolerability of voriconazole in the treatment of chronic cavitary pulmonary aspergillosis. *J Infect* 2006;52:133-7.

Auffret N, Janssen F, Chevalier P, et al. Voriconazole photosensitivity: 7 cases (Article in French). *Ann Dermatol Venerol* 2006;133:330-2.

Denning DW, Griffiths CE. Muco-cutaneous retinoid effects and facial erythema related to the novel triazole antifungal agent voriconazole. *Clin Exp Dermatol* 2001;26:648-53.

IV CHEMOTHERAPY DRUGS AND IMMUNO-SUPPRESSORS

Aminoglutethimide

Estrogen biosynthesis inhibitor, producing a "medical adrenalectomy" in patients with breast cancer.

■ Incidence

Common (>20%).

■ Risk factors

Associated radiotherapy.

■ Clinical manifestations

- **General:** anaphylactic shock, fever.
- **Cutaneous:** maculopapular rash, pruritus, oral ulcerations.

■ Diagnostic methods

No *in vivo* or *in vitro* method is currently available for diagnosis, other than challenge by re-introduction.

■ Mechanisms

Unknown.

■ Management

Avoidance.

Corticosteroid therapy may be useful.

References

Vanek N, Hortobagyi GN, Buzdar AU. Radiotherapy enhances the toxicity of aminoglutethimide. *Med Pediatr Oncol* 1990; 8:162-4.

Zambetti M, Brambilla C, Tancini G, et al. Aminoglutethimide in postmenopausal breast cancer refractory to multiple hormonal and cytostatic treatments. *Tumori* 1987;73:369-73.

Leloire O, Forzy G, Derreumaux LL, et al. Severe anaphylactic reaction to aminoglutethimide (Article in French). *Presse Med* 1986;15:34.

Azathioprine

Azathioprine is an immunosuppressant drug, an imidazole analogue of 6-mercaptopurine. It has been used in the last 20 years to prevent organ transplant rejection and in the treatment of some autoimmune and inflammatory bowel diseases.

■ Incidence

Hypersensitivity reactions to azathioprine: more than 50 patients reported (up to 1998) in the English-language medical literature.

■ Risk factors

Presence of fever, gastrointestinal symptoms, or exacerbation of the underlying disease upon initiation of the drug are risk factors for an hypersensitivity reaction.

Concomitant use of corticosteroids (hypotension).

■ Clinical manifestations

(within 4 weeks of initiation of the treatment)

- **General:** fever, hypotension, tachycardia.
- **Cutaneous:** urticaria, maculopapular rash, pruritus, erythema nodosum-like eruption, sterile pustular eruption, vasculitis, erythema multiforme, Stevens-Johnson syndrome, acute generalized exanthematous pustulosis, erythema gyratum repens.
- **Respiratory:** dyspnea, pneumonitis, cough.
- **Gastrointestinal:** nausea, vomiting, diarrhea, jaundice, pancreatitis, hepatitis.
- **Musculoskeletal:** arthralgia, myalgia, rhabdomyolysis.
- **Neurological:** headache, meningismus, peripheral neuropathy, seizure.
- **Renal:** oliguria, acute interstitial nephritis.

■ Diagnostic methods

No antibodies to azathioprine or its metabolites have been found.

Recurrence of symptoms with drug re-challenge (to be performed with extreme caution).

■ Mechanisms

Unknown.

Role of the imidazole side-chain?

I Management

As azathioprine is metabolized to 6-mercaptopurine re-challenge to both should be avoided in patients who have experienced an azathioprine hypersensitivity reaction. Avoidance, especially if the initial dose of the medication elicits a febrile or systemic response.

Desensitization: from 5 mg increasing each day to reach 125 mg daily.

References

- De Fonclare AL, Khosrotehrani K, Aractingi S, et al. Erythema nodosum-like eruption as a manifestation of azathioprine hypersensitivity in patients with inflammatory bowel disease. *Arch Dermatol* 2007;143:744-8.
- Elston GE, Johnston GA, Mortimer NJ, et al. Acute generalized exanthematous pustulosis associated with azathioprine hypersensitivity. *Clin Exp Dermatol* 2007;32:52-3.
- Demirtas-Ertan G, Rowshani AT, ten Berge IJ. Azathioprine-induced shock in a patient suffering from undifferentiated erosive oligoarthritis. *Neth J Med* 2006;64:124-6.
- Dominguez Ortega J, Robledo T, Martinez-Cocera C, et al. Desensitization to azathioprine. *J Investig Allergol Clin Immunol* 1999;9:337-8.
- Fields CL, Robinson JW, Roy TM, et al. Hypersensitivity reaction to azathioprine. *South Med J* 1998;91:471-4.
- Knowles SR, Gupta AK, Shear NH, et al. Azathioprine hypersensitivity-like reaction: a case report and a review of the literature. *Clin Exp Dermatol* 1995;20:353-6.

Bleomycin

Cytostatic agent produced by a strain of *Streptomyces verticillus*. Bleomycin inhibits cell cleavage by blocking the uptake of thymidine by DNA and leading to weakening and break-up of DNA chains.

■ Incidence

Fever: 20 to 25% of patients.

Fulminant reactions: 1 to 8% of patients.

Deaths reported.

■ Risk factors

Lymphoma (for fulminant reactions).

Intravenous administration.

■ Clinical manifestations

• **General:** fever, hypotension.

• **Cutaneous:** pruritus, rash, angioedema. Flagellate erythema and pigmentation (frequent). Stomatitis, alopecia. Raynaud's syndrome. Scleroderma-like changes, Stevens-Johnson syndrome (rare).

• **Respiratory:** interstitial pneumonitis, fibrosis.

■ Diagnostic methods

No *in vivo* or *in vitro* method is currently available for diagnosis.

■ Mechanisms

Non immunological mechanisms are likely.

■ Management

Antihistamines and corticosteroids are sometimes effective.

Desensitization: one case.

References

Yamamoto T. *Bleomycin and the skin*. *Br J Dermatol* 2006;155:869-75.

Robinson JB, Singh D, Bodurka-Bevers DC, et al. *Hypersensitivity reactions and the utility of oral and intravenous desensitization in patients with gynecologic malignancies*. *Gynecol Oncol* 2001;82:550-8.

Haerslev T, Avnstorp C, Joergensen M. *Sudden onset of adverse effects due to low-dosage bleomycin indicates an idiosyncratic reaction* *Cutis* 1993;52:45-6.

Yousem SA, Lifson JD, Colby TV. *Chemotherapy-induced eosinophilic pneumonia. Relation to bleomycin*. *Chest* 1985;88:103-6.

Khansur T, Little B, Tavassoli M. *Fulminant and fatal angioedema caused by bleomycin treatment*. *Arch Intern Med* 1984;144:2267.

Bortezomib

Proteasome inhibitor which is highly efficient in the treatment of relapsed multiple myeloma and non-Hodgkin's lymphoma.

■ Incidence

Rash: 8 to 18%.

■ Clinical manifestations

- **Cutaneous:** erythematous, edematous plaques or nodules (delayed reaction occurring after 30 days treatment, resolving in a few days), morbilliform rash, folliculitis-like rash, neutrophilic dermatitis, vasculitis (cutaneous and visceral), toxic epidermal necrolysis.

■ Mechanisms

The development of an isolated cutaneous vasculitis may predict a good therapeutic response in non-Hodgkin's lymphoma.

■ Management

Premedication with corticosteroids.

References

Sanchez-Politta S, Favet L, Kerl K, et al. Bortezomib-induced skin eruption. *Dermatology* 2008;216:156-8.

Fang B, Song Y, Ma J, et al. Severe epidermal necrolysis after bortezomib treatment for multiple myeloma. *Acta Haematol* 2007;118:65-7.

Wu KL, Heule F, Lam K, et al. Pleomorphic presentation of cutaneous lesions associated with the proteasome inhibitor bortezomib in patients with multiple myeloma. *J Am Acad Dermatol* 2006;55:897-900.

Busulfan

An alkylating agent, able to act selectively against the myeloid cell line, used in the treatment of chronic leukemia, polycythemia vera, and thrombocytopenia.

■ Incidence

Uncommon.

■ Clinical manifestations

- **Cutaneous (main manifestations):** macular erythematous rash, urticaria, pigmentation, alopecia.
- **Respiratory:** interstitial pneumonia (often severe), pulmonary fibrosis.

■ Diagnostic methods

No *in vivo* or *in vitro* method is currently available for diagnosis.

■ Mechanisms

Unknown.

■ Management

Avoidance.

References

Simonart T, Decaus G, Gourdin JM, et al. Hyperpigmentation induced by busulfan: a case with ultrastructure examination (Article in French). *Ann Dermatol Venereol* 1999;126:439-40.

Akoun G, Milleron B, Mayaud C. Pulmonary changes caused by cytostatic drugs (Article in French). *Ann Med Interne* 1985;136:671-6.

Leyden M.J, Manoharan A. "Allopurinol-type" rash due to busulphan. *Lancet* 1978; 2 (8093):797.

Capecitabine

An antipyrimidic agent (prodrug of 5-FU) used in the treatment of metastatic colic and breast cancer.

■ Clinical manifestations

• **Cutaneous:** hand-foot syndrome +++ (near 50%): erythema and swelling of the extremities with moderate to severe discomfort, desquamation (lesions appearing soon after the onset of treatment; recurrence with each cycle; dosage reductions may be necessary), acquired palmo plantar keratoderma, hyperpigmentation (sometimes only acral, more frequent in non white patients), exfoliative dermatitis, re-pigmentation of vitiligo, edema, photosensitivity and photo-recall (rare), stomatitis ++, nail changes, pyogenic granulomas.

■ Diagnostic methods

None.

■ Mechanisms

Unknown.

■ Management

5-FU has been successfully used in a capecitabine-allergic patient.

References

Heidary N, Naik H, Burgin S. Chemotherapeutic agents and the skin: an update. *J Am Acad Dermatol* 2008;58:545-70

Do JE, Kim YC. Capecitabine-induced diffuse palmoplantar keratoderma: is it a sequential event hand-foot syndrome? *Clin Exp Dermatol* 2007;32:519-21.

Liu CY. Fluorouracil for allergic reactions to capecitabine. *Ann Pharmacother* 2002;36:1897-9.

Carboplatin

Mainstay therapy in ovarian and testicular carcinoma but also in brain tumors in children, lung and breast cancer.

■ Incidence

12%.

Deaths reported.

1% in patients receiving less than 6 courses of the drug, 27% in patients receiving more than 7 courses of the drug.

42% in pediatric patients with glioma.

■ Risk factors

Prior carboplatin hypersensitivity.

Occupational exposure to platinum salts (?)

Female sex (children with low-grade glioma).

■ Clinical manifestations

- **General:** anaphylactic shock, hyperthermia.
- **Cutaneous:** rash, pruritus, urticaria, angioedema, diffuse erythema, edema.
- **Respiratory:** dyspnea, bronchospasm, cyanosis.
- **Digestive:** vomiting.

■ Diagnostic methods

Skin tests

Prick tests: positive in some cases.

Intradermal tests (0.1 mg/ml, 1 mg/ml): positive in patients with immediate reaction. Good negative predictive value.

No specific IgE found.

■ Mechanisms

IgE-mediated hypersensitivity in some cases (platinum is a tetravalent inorganic molecule that readily complexes with proteins to form antigens).

Direct histamine release.

■ Management

Switch to cisplatin (if skin test is negative).

Pre-treatment with corticosteroids and antihistamines (sometimes ineffective in preventing IgE-mediated reactions).

Desensitization.

Usually successful > 70% of patients.

Many protocols have been reported:

In children:

“Rush” protocol:

Premedication with prednisolone 12 h and 1 h before, diphenhydramine 30 minute before and ranitidine 30 minute before.

Then: 1 - 2.5 - 5 - 10 - 25 and 50 mg of carboplatin infused at 1 mg/min every 15 minutes. The remainder of the dose at 200 mg/hr.

“Slow” protocol:

0.1 - 0.2 - 0.5 - 1 - 2 - 3 - 4 - 5 - 7.5 - 10 and 15 mg at 1 mg/min every 15 minutes.

Then: 100 mg/ hr for one hour then remainder of the dose at 200 mg/ hr.

In adults:

“Rush” protocol (6 hours):

After premedication with dexamethasone 8-12 mg IV.

1/1,000 of the total dose in 150 ml D5W over 1.5 hours. If tolerated:

1/100 of the total dose in 150 ml D5W over 1.5 hours. If tolerated:

1/10 of the total dose in 150 ml D5W over 1.5 hours. If tolerated:

The remainder of the dose in 150 ml D5W over 1.5 hours.

«Slow» protocol (81 hours):

0.4 mg carboplatin/150 ml over 1.5 hour.

4 mg carboplatin/150 ml over 15 hours.

40 mg carboplatin/150 ml over 15 hours.

355 mg carboplatin/500 ml over 50 hours.

References

Enrique E, Malek T, Castello JV, et al. Usefulness of skin testing with platinum salts to demonstrate lack of cross-reactivity between carboplatin and cisplatin. *Ann Allergy Asthma Immunol* 2008;100:86.

Lafay-Cousin L, Sung L, Carret AS, et al. Carboplatin hypersensitivity reaction in pediatric patients with low-grade glioma: a Canadian Pediatric Brain Tumor Consortium experience. *Cancer* 2008;112:982-9.

Leguy-Seguín V, Jolimoy G, Coudert B, et al. Diagnostic and predictive value of skin testing in platinum salts hypersensitivity. *J Allergy Clin Immunol* 2007;119:726-30.

Confino-Cohen R, Fishman A, Altaras M, et al. Successful carboplatin desensitization in patients with proven carboplatin allergy. *Cancer* 2005;104:640-3.

Broome C.B, Schiff R.I, Friedman H.S. Successful desensitization to carboplatin in patients with systemic hypersensitivity reactions. *Med Pediatr Oncol* 1996;26:105-10.

Goldberg A, Confino-Cohen R, Fishman A, et al. A modified prolonged desensitization protocol in carboplatin allergy. *J Allergy Clin Immunol* 1996;98:841-3.

Chlorambucil

Chlorambucil is an alkylating agent widely used in the treatment of lymphoproliferative diseases.

■ Incidence

Uncommon.

■ Clinical manifestations

- **General:** fever, stomatitis, pharyngitis, conjunctivitis.
- **Cutaneous:** erythema multiforme, toxic epidermal necrolysis, exanthems, urticaria, oral ulcerations, neutrophilic eccrine hidradenitis, contact dermatitis.
- **Pulmonary:** interstitial pneumonitis (14 cases reported up to 1994).
- **Hematologic:** immune hemolytic anemia (antibody able to bind complement to erythrocytes only in the presence of chlorambucil).

■ Diagnostic methods

Cutaneous biopsy (toxic epidermal necrolysis).

Lymphocyte stimulation test: one positive case.

Re-challenge test is often positive but harmful.

■ Mechanisms

Unproven, but type III allergic reaction is likely (immune complex deposition).

■ Management

Avoidance.

Cross-reactivity between alkylating agents is exceptional.

References

Levin M, Libster D. Allergic reaction to chlorambucil in chronic lymphocytic leukemia presenting with fever and lymphadenopathy. *Leuk Lymphoma* 2005;46:1195-7.

Goon AT, McFadden JP, McCann M, et al. Allergic contact dermatitis from melphalan and chlorambucil : cross-sensitivity or cosensitization ? *Contact Dermatitis* 2002;47:309-14.

Aydogdu I, Ozcan C, Harputluoglu M, et al. Severe adverse skin reaction to chlorambucil in a patient with chronic lymphocytic leukaemia. *Anticancer. Drugs* 1997;8:468-9.

Torricelli R, Kurer SB, Kroner T, et al. Delayed allergic reaction to Chlorambucil (Leukeran). Case report and literature review. *Schweitz Med Wochenschr* 1995;125:1870-3.

Crestani B, Jaccard A, Israel-Biet D, et al. Chlorambucil-associated pneumonitis. *Chest* 1994;105:634-6.

Cisplatin

A cytostatic agent able to inhibit DNA synthesis selectively and specifically. The most active agent in germ-cell tumors and osteogenic carcinoma.

■ Incidence

Common in studies published in the 1970's: 6 to 14% (with six or more doses of cisplatin). Far less frequent in the 1980's: only 3 or 4 cisplatin courses in testicular carcinoma; and common use of diphenhydramine and dexamethasone in emesis prevention.

■ Risk factors

Concurrent use of other drugs (bleomycin, actinomycin, vinblastine, cyclophosphamide).

Intravesical use: incidence 10 to 25% (especially if > 8 courses).

Intraperitoneal use: if large doses and high infusion time ratio (>2.2).

Occupational exposure to platinum salts.

■ Clinical manifestations

- **General:** anaphylactic shock (deaths reported).
- **Cutaneous (most common):** pruritus, urticaria, rash, flush.
- **Respiratory:** dyspnea, bronchospasm.
- **Digestive:** vomiting.
- **Hematological:** hemolytic anemia (or false positive direct antiglobulin test).

■ Diagnostic methods

Skin tests

Prick-test: 0.1 to 0.25 mg/ml

Intradermal test: 0.001 mg/ml; 0.01 mg/ml; 0.1 mg/ml.

Few patients positive to I.D. 0.01 mg/ml to 0.1 mg/ml. Good negative predictive value.

Histamine release.

One case with positive histamine release test.

Flow cytometry (CD63/MIFlgE)

Positive in two patients.

■ Mechanisms

IgE-mediated hypersensitivity in some cases (cisplatin acts as a hapten when bound to serum proteins).

Direct release of vasoactive substances.

I Management

Pretreatment with corticosteroids and antihistamines (sometimes ineffective in preventing IgE-mediated reactions).

Desensitization: a few cases reported.

After premedication with hydroxyzine and methylprednisolone, gradual increase of doses from 1 mg to 80 mg at 30 min intervals.

Switch to another platinum salt (skin negative).

References

Touraine F, Sainte Laudy J, Boumediene A, et al. Investigation of allergic reactions to platinum salts (Article in French). Rev Mal Respir 2006;23:458-62.

Hebert ME, Blivin JL, Kessler J, et al. Anaphylactoid reactions with intraperitoneal cisplatin. Ann Pharmacother 1995;29:260-3.

Goldberg A, Altaras MM, Mekori YA, et al. Anaphylaxis to cisplatin: diagnosis and value of pretreatment in prevention of recurrent allergic reactions. Ann Allergy 1994;73:271-2.

Ter - Schiphorst C, Bousquet J, Menardo JL, et al. Specific desensitization to cis-dichlorodiamino platinum in an allergic patient (Article in French). Presse Med 1986;15:1242.

Cladribine

2-chlorodeoxyadenosine (2-CdA) is considered as first line therapy for hairy cell leukaemia and is being used increasingly to treat chronic lymphoproliferative syndromes and paediatric acute myeloid leukaemia.

■ Risk factors

Concomittant use of allopurinol.

■ Clinical manifestations

• **Cutaneous:** exanthems (frequent), generalized skin eruption with a histological examination showing eosinophil-rich infiltrate with flame figures (like in eosinophilic cellulitis), toxic epidermal necrolysis (associations with allopurinol or sulfonamides are frequent in case reports), edema, injection-site reactions.

■ Diagnostic methods

Skin biopsy: eosinophil-rich infiltrate with flame figures.

■ Mechanisms

Drug-induced change in T-cell imbalance in severely immunosuppressed patients.

■ Management

Corticosteroids are effective to control the eruptions.

References

- Rossini MS, de Souza EM, Cintra ML, et al. Cutaneous adverse reaction to 2-chlorodeoxyadenosine with histological flame figures in patients with chronic lymphocytic leukaemia. *J Eur Acad Dermatol Venereol* 2004;18:538-42.
- Chubar Y, Bennet M. Cutaneous reactions in hairy cell leukaemia treated with 2-chlorodeoxyadenosine and allopurinol. *Br J Haematol* 2003;122:768-70.
- Meunier P, Castaigne S, Bastie JN, et al. Cutaneous reactions after treatment with 2-chlorodeoxyadenosine. *Acta Derm Venereol* 1996;76:385-6.

Cyclophosphamide

A nitrogen mustard derivative widely used in the treatment of various malignancies and auto-immune disorders (vasculitis, SLE).

■ Incidence

Low. Less than 30 cases reported.

■ Clinical manifestations

(higher with intravenous than oral route)

- **General:** anaphylactic shock.
- **Cutaneous:** acral erythema, urticaria, angioedema, rash, pigmentation (cutaneous, gingival and nails), stomatitis and oral ulcerations (+++), erythema multiforme, Stevens-Johnson syndrome, toxic epidermal necrolysis (rare), vasculitis.
- **Respiratory:** bronchospasm.

■ Diagnostic methods

Skin tests with cyclophosphamide, ifosfamide, and cyclophosphamide metabolites: 4 hydroperoxy-cyclophosphamide and phosphoramidate mustard.

Prick tests and intradermal tests: cyclophosphamide and ifosfamide 1 mg/ml and 10 mg/ml; cyclophosphamide metabolites 1 µg/ml to 10 mg/ml.

A few cases with positive skin tests to cyclophosphamide, ifosfamide or metabolites.

No specific IgE.

■ Mechanisms

IgE-mediated hypersensitivity in some cases. Cyclophosphamide is a low molecular weight compound able to form an immunogenic complex with a carrier protein.

Phosphoramidate mustard contains the bischloroethylamine group common to the nitrogen mustards leading to potential cross-reactivity with other nitrogen mustards (melphalan, chlorambucil, ifosfamide).

■ Management

Avoidance.

Use of another nitrogen mustard (ifosfamide) is sometimes possible under strict medical supervision.

References

- Thong BY, Leong KP, Thumboo J, et al. Cyclophosphamide type I hypersensitivity in systemic lupus erythematosus. *Lupus* 2002;11:127-9.
- Stratton J, Warwicker P, Farrington K. Allergic reactions to oral cyclophosphamide therapy in immunologically-mediated renal disease. *Nephrol Dial Transplant* 2001;16:1724-5.
- Assier-Bonnet H, Aractingi S, Cadranel J, et al. Stevens-Johnson syndrome induced by cyclophosphamide : report of two cases. *Br J Dermatol* 1996;135:864-6.
- Popescu NA, Sheehan MG, Kouides PA, et al. Allergic reactions to cyclophosphamide: delayed clinical expression associated with positive immediate skin-tests to drug metabolites in five patients. *J Allergy Clin Immunol* 1996;97:26-33.
- Komamura H, Higashiyama M, Hashimoto K, et al. Three cases of chemotherapy-induced acral erythema. *J Dermatol* 1995;22:116-21.
- Cromar BW, Colvin M, Casale TB. Validity of skin tests to cyclophosphamide and metabolites. *J Allergy Clin Immunol* 1991; 88:965-7.

Cyclosporine

Cyclosporine is a potent immunosuppressive agent used to prevent rejection of transplanted organs.

■ Incidence

Rare.

Deaths reported.

■ Clinical manifestations

- **General:** anaphylactic shock.

- **Cutaneous:** pruritus, urticaria, rash, flush, alterations of the pilosebaceous follicle (frequent), hypertrichosis (frequent), follicular keratosis, acne (sometimes keloidalis and macrocystic), folliculitis, sebaceous hyperplasia, gingival hyperplasia (frequent), vasculitis, immunosuppressive induced carcinoma, lymphoma or lymphocytic infiltration (pseudo lymphoma), Kaposi's sarcoma, periungueal granulation tissue.

- **Respiratory:** dyspnea, bronchospasm, hypersensitivity pneumonitis.

- **E.N.T.:** laryngospasm.

■ Diagnostic methods

Skin tests are seldom performed: 2/17 patients had positive skin-tests. One cyclosporine allergic patient with positive intradermal test to cremophor EL.

Basophil activation up regulation of CD 63 expression.

Provocation challenge: oral or intravenous.

■ Mechanisms

The organic solvent (cremophor E.L : polyoxyethylated castor oil) contained in the intravenous solution (and in some oral forms) has been implicated.

IgE-mediated hypersensitivity (positive skin-tests, no specific IgE found).

Complement activation.

Direct histamine release.

■ Management

Use alternative formulations of cyclosporine:

There are two forms of oral cyclosporine :

- oral solution + soft gelatin capsules (diluent : polyoxyethylated oleic or glucosed glucerides) : treatment of choice of intravenous cyclosporine allergic patients.

- oral solution microemulsion + soft gelatin capsules microemulsion (diluent : polyoxyl 40 hydrogenated castor oil)

If high-dose intravenous cyclosporine is used:

- cyclosporine solutions are incompatible with polyvinyl chloride (PVC) plastics and must be prepared in non-PVC plastic bags, glass bottles or polypropylene syringes. Tubing used for the infusion must not contain PVC.
- cyclosporine should be diluted to 0.5 to 2.5 mg/ ml with 5% dextrose or 0.9% sodium chloride. After adding cyclosporine to the carrier fluid, the infusion must be mixed thoroughly by shaking or swirling the bottle. The infusion fluid must appear homogenous.
- the tubing system must be primed with 0.9% saline or 5% dextrose.
- high-dose cyclosporine should not be administered to the patient unless the patient has received appropriate corticosteroid and antihistamine premedication.
- During the first ten minutes of the first and second cyclosporine infusions, supervision by medical personnel with proper resuscitation skills is advisable.

Desensitization is possible.

References

Doutre MS. *Ciclosporin (Article in French)*. *Ann Dermatol Venereol* 2002;129:392-404.

Riegert-Johnson DL, Kumar S, Volcheck GW, A patient with anaphylactoid hypersensitivity to intravenous cyclosporine and subcutaneous phytonadione (vitamin K(1)), *Bone Marrow Transplant*. 2001;28(12):1176-7

Takamatsu Y, Ishizu M, Ichinose I, et al, Intravenous cyclosporine and tacrolimus caused anaphylaxis but oral cyclosporine capsules were tolerated in an allogeneic bone marrow transplant recipient. *Bone Marrow Transplant* 2001;28(4):421-3

Ebo DG, Piel GC, Conraads V, et al, IgE-mediated anaphylaxis after first intravenous infusion of cyclosporine, *Ann. Allergy. Asthma. Immunol.* 2001;87(3):243-5

Volcheck G.W, Van Delenn R.G, *Anaphylaxis to intravenous cyclosporine and tolerance to oral cyclosporine: case report and review*. *Ann. Allergy. Asthma. Immunol.*, 1998;80(2):159-63

Liau-Chu M, Theis J.G.W, Koren G, *Mechanism of anaphylactoid reactions: improper preparation of high-dose intravenous cyclosporine leads to bolus infusion of cremophor EL and cyclosporine*, *Ann. Pharmacother.*, 1997;31:1287-91

Cytarabine

An antimitotic antimetabolite agent. This hydrosoluble pyrimidic nucleoside-resembling cytidin inhibits desoxycytidin synthesis by a competitive mechanism. It is used in the treatment of acute leukemia and some solid tumors.

■ Incidence

Type I reactions: uncommon.

Cytarabine syndrome: frequent, up to 72.7% of patients receiving total doses of 30 g/m² have cutaneous reactions (rashes)

Toxic conjunctivitis: uncommon.

Neutrophilic eccrine hidradenitis: uncommon.

Palmar-plantar syndrome: rare.

■ Clinical manifestations

• **General:** type I reactions include dyspnea, chest pain, fever, angioedema, urticaria, hypotension. Cytarabine syndrome: fever, rigors, diaphoresis, myalgia, arthralgia, maculopapular rash, hypotension, conjunctivitis.

• **Cutaneous:** hand-foot syndrome, acral erythema, palmar-plantar erythrodysesthesia (sometimes with recurrent and increasingly severe bullous reactions), neutrophilic eccrine hidradenitis, maculopapular morbilliform rash (frequent), pruritus, urticaria, vasculitis, toxic epidermal necrolysis, acute generalized exanthematous pustulosis, oral and perianal ulcerations.

■ Diagnostic methods

Type I reactions.

Skin tests

Prick tests are negative.

A few cases of positive intradermal skin tests at a concentration of 4 µg/ml.

Presence of specific IgE antibodies: in some patients with anaphylactic shock.

Specific histamine release.

■ Mechanisms

Type I reactions: IgE-mediated hypersensitivity is suggested by immediately positive intradermal skin tests, detection of IgE antibodies and passive cutaneous anaphylaxis.

Cytarabine syndrome, toxic conjunctivitis, neutrophilic eccrine hidradenitis: direct toxicity is likely.

I Management

Type I reactions.

Desensitization.

Adults (1 case): starting with 10 ml of 0.002% cytarabine up to 200 mg of cytarabine in 500 cc of saline.

Children (1 case): 200 µg to 45 mg in 13 hours.

Other reactions.

Pretreatment with corticosteroids is sometimes helpful.

References

Cetkovska P, Pizinger K, Cetkovsky P. High-dose cytosine arabinoside-induced cutaneous reactions. *J Eur Acad Dermatol Venereol* 2002;16:481-5.

Chiu A, Kohler S, McGuire J, et al. Cytarabine-induced generalized exanthematous pustulosis. *J Am Acad Dermatol* 2002;47:633-5.

Crawford JH, Eikelboom JW, McQuillan A. Recurrent palmar-plantar erythrodysesthesia following high-dose cytarabine treatment for acute lymphoblastic leukaemia. *Eur J Haematol* 2002;69:315-7.

Blanca M, Torres MT, Giron M, et al. Successful administration of cytarabine after a previous anaphylactic reaction. *Allergy* 1997;52:1009-11.

Dacarbazine

Dacarbazine (DTIC) is an imidazole carboxamide used in the treatment of malignant melanoma, sarcomas, Hodgkin's disease and neuroblastoma.

■ Incidence

Anaphylactic shock: one case.

Hypersensitivity: 20% in patients with metastatic malignant melanoma.

Photosensitivity and hepatitis are more frequent.

■ Clinical manifestations

- **General:** anaphylactic shock (one case), hypersensitivity reactions after the first or second course; fever, hypereosinophilia with or without liver dysfunction, with or without delayed medullar aplasia.

- **Cutaneous:** photosensitivity, rash, urticaria, injection-site reaction.

- **Hepatic:** allergic hepatitis (allergic hepatic veno-occlusive disorder: Budd-Chiari syndrome).

■ Diagnostic methods

None.

■ Mechanisms

Unknown.

■ Management

Avoidance.

In case of fever and hypereosinophilia without liver dysfunction dacarbazine may be continued.

References

Levy A, Guitera P, Kerob D, et al. Hypersensitivity to dacarbazine in patients with metastatic malignant melanoma (Article in French). *Ann Dermatol Venereol* 2006;133:157-60.

Treudler R, Georgieva J, Geilen CC, et al. Dacarbazine but not temozolomide induces phototoxic dermatitis in patients with malignant melanoma. *J Am Acad Dermatol* 2004;50:783-5.

Serrano G, Aliaga A, Febrer I. Dacarbazine induced photosensitivity. *Photodermatology* 1989; 6:140-1.

Abhyankar S, Rao S.P, Pollio L, et al. Anaphylactic shock due to dacarbazine. *Am J Dis Child* 1988;142:918.

Mc Clay E, Lusch CJ, Mastrangelo MJ. Allergy-induced hepatic toxicity associated with dacarbazine. *Cancer Treat Rep* 1987;71:219-20.

Daunorubicin

Antimitotic antibiotic used to treat hematological disorders.

■ Incidence

Uncommon (1 to 2%).
No deaths reported.

■ Clinical manifestations

- **General:** fever, anaphylactic shock.
- **Cutaneous:** rash, urticaria, angioedema.

■ Diagnostic methods

No *in vivo* or *in vitro* method is currently available for diagnosis.

■ Mechanisms

Unknown.

■ Management

Avoidance.

Possible cross reactivity with doxorubicin.

References

Ma D, Isbister JP. Cytotoxic-induced fulminant hyperpyrexia. *Cancer* 1980;45:2249–51.

Crowther D, Powles RL, Bateman CJT, et al. Management of adult acute myelogenous leukaemia. *Br Med J* 1973;1:131–7.

Freeman AI. Clinical note: allergic reaction to daunomycin (NSC-82151). *Cancer Chemother Rep* 1970;54:475-6.

Docetaxel

Docetaxel is a semisynthetic compound produced from 10-deacetylbaccatin-III (found in the needles of the european yew tree, *taxus baccata*). It is used in the treatment of breast, non-small cell lung, prostatic and gastric cancer.

■ Incidence

Less frequent than paclitaxel.

■ Clinical manifestations

- **General:** hypotension, fever, chills (hypersensitivity syndrome).
- **Cutaneous:** acral erythema of hand-foot syndrome, i.e., erythematous and violaceous patches or edematous plaques on the palms and soles and progression to the dorsal face; resolution within three weeks with desquamation, acral erythrodysesthesia syndrome (direct toxic damage), fixed erythrodysesthesia plaque (solitary erythematous to edematous plaque proximal to the infusion site, resolution with pigmentation), scleroderma-like lesions, subacute cutaneous lupus erythematosus, radiation recall dermatitis, injection-site reaction, nail abnormalities, stomatitis, toxic epidermal necrolysis (rare).
- **Respiratory:** dyspnea, bronchospasm, hypersensitivity pneumonitis.

■ Diagnostic methods

Skin biopsy (erythrodysesthesia): epidermal dysmaturation with necrotic keratinocytes or sparse superficial perivascular lymphocytic infiltration with eosinophils, focal vacuolar interface alteration.

■ Mechanisms

The vehicle polysorbate 80 has been implicated in some reactions.
Release of vasoactive molecules.

■ Management

The usefulness of premedication with antihistamines and corticosteroids is controversial.

Oral pretreatment 12 hours and 3 hours before infusion of docetaxel with 32 mg of methylprednisolone, 10 mg of cetirizine and 1 mg of ketotifen limits the development of acute hypersensitivity reactions (28% → 7.7%).

Classical prophylactic medication: dexamethasone 8 mg 13 hours, 7 hours, 1 hour before the administration of docetaxel; clemastine 1 mg 13 hours, 7 hours, 1 hour, before the administration of docetaxel; followed by dexamethasone 8 mg p.o. twice daily for 3 days.

Development of a polysorbate 80-free docetaxel formulation (pegylated liposomal docetaxel, docetaxel-fibrinogene-coated olive oil droplets, docetaxel encapsulated nanoparticle-aptane bioconjugates, submicronic dispersion formulation).

Desensitization: usually successful in 6 to 7 hours.

Cross-sensitivity between paclitaxel and docetaxel is frequent.

References

- Heidary N, Naik H, Burgin S. Chemotherapeutic agents and the skin: an update. *J Am Acad Dermatol* 2008;58:545-70.
- Engels FK, Mathot RA, Verweij J. Alternative drug formulations of docetaxel: a review. *Anticancer Drugs* 2007;18:95-103.
- Hennenfent KL, Govindan R. Novel formulations of taxanes: a review. Old wine in a new bottle ? *Ann Oncol* 2006;17:735-49.
- Messaad D, Sablayrolles P, Pujol JL, et al. Successful docetaxel tolerance induction. *Allergy* 2003;58:1320-1.
- Eich D, Scharffetter-Kochanek K, Eich T, et al. Acral erythrodysesthesia syndrome caused by intravenous infusion of docetaxel in breast cancer. *Am J Clin Oncol* 2002;25:599-602.

Doxorubicin

Doxorubicin is an anthracycline antibiotic isolated from cultures of *Streptomyces peucetius*. It is used in the treatment of hematological malignancies and solid and soft tissue tumors, but is limited by substantial toxicity (myelosuppression and myocardial damage).

Doxil* (liposomal formulation of doxorubicin coated with polyethylene glycol) is less myelo- and cardio-toxic but is characterized by dominant and dose-limiting mucocutaneous reactions. Doxil* is used in Kaposi's sarcoma and metastatic ovarian cancer.

■ Incidence

Uncommon: urticaria 0.6 to 3%.

Hypersensitivity reactions (Doxil*): 8%.

One death reported.

■ Risk factors

Clindamycin allergy?

Intravenous route.

■ Clinical manifestations

- **General:** anaphylactic shock, hypersensitivity infusion reactions (facial flushing, dyspnea, tachypnea, facial swelling, headache, chills, hypo or hypertension, chest and back pain): first exposure.

- **Cutaneous:** pruritus, urticaria, angioedema. Hand-foot syndrome or palmo-plantar erythrodysesthesia (frequent, sometimes severe with necrosis). Rash (follicular, morbilliform, maculopapular, vesicular). Intertrigo-like eruptions. Injection site reactions sometimes with necrosis (non liposomal doxorubicin). Pigmentation (blue-gray). Neoformation of melanotic macules. Radiation recall dermatitis. neutrophilic eccrine hidradenitis. Alopecia, stomatitis, nail pigmentation.

- **Respiratory:** bronchospasm.

- **E.N.T.:** nasal congestion.

■ Diagnostic methods

Drug re-challenge.

■ Mechanisms

Complement activation (Doxil*) by parenteral liposomes.

Direct degranulation of mast cells or circulating basophils without antibody mediation.

■ Management

The use of pegylated liposomal doxorubicin (PLD) increases the frequency (7 to 9%) of hypersensitivity reactions in the first cycles of treatment.

Premedication (glucocorticoids and antihistamines) and initial slow infusion rate (0.1-0.2 mg/mn).

Concerning use of intravesical doxorubicin:

- if the reaction is severe; give an other effective intravesical agent
- if the reaction is mild and self-limiting; prophylactic administration of antihistamines may be useful.

References

Lorusso D, Di Stefano A, Carone V, et al. Pegylated liposomal doxorubicin-related palmo-plantar erythrodysesthesia (hand-foot syndrome). *Ann Oncol* 2007;18:1159-64.

Chan A, Chih V, Tham Chee Kian. Liposomal doxorubicin-associated hypersensitivity despite preventive measures. *J Oncol Pharm Pract* 2007;13:105-7.

Chanan-Khan A, Szebeni J, Savay S, et al. Complement activation following first exposure to pegylated liposomal doxorubicin (Doxil*): possible role in hypersensitivity reactions. *Ann Oncol* 2003;14:1430-7.

Alberts DS, Garcia DJ. Safety aspects of pegylated liposomal doxorubicin in patients with cancer. *Drugs* 1997;54:30-5.

Arena FP, Sherlock S. Doxorubicin hypersensitivity and clindamycin (letter). *Ann Intern Med* 1990;112:150.

Lee M, Sharifi R. Generalized hypersensitivity reaction to intravesical thiotepa and doxorubicin. *J Urol* 1987;138:143-4.

Epirubicin

Anthracyclenic antibiotic used in the treatment of breast and ovarian cancer.

■ Clinical manifestations

Cutaneous: urticaria, pruritus, rash, allergic contact dermatitis, injection-site reactions, alopecia, stomatitis.

■ Diagnostic methods

None.

■ Mechanisms

Unknown.

■ Management

Avoidance.

References

Oltmans R, van der Veegt SGL. Serious allergic reaction to administration of epirubicin. *The Netherlands J Med* 2003;61:226-7.

Ventura MT, Dagnello M, Di Corato R, et al. Allergic contact dermatitis due to epirubicin. *Contact Dermatitis* 1999;40:339.

Cassidy J, Rankin EM. Hypersensitivity reaction to epirubicin. *Med Oncol Tumor Pharmacother* 1989;6:297-8.

Epoetin

Recombinant human erythropoietin (EPO) is used for correction of renal and non-renal anemias.

■ Incidence

More than 250 cases of pure red cell aplasia have been reported.

■ Risk factors

Subcutaneous route.

Male sex.

Chronic kidney disease.

■ Clinical manifestations

• **General:** anaphylaxis.

• **Cutaneous:** rash, urticaria, angioedema, injection-site reaction.

• **Haematological:** pure red cell aplasia.

■ Diagnostic methods

Skin tests: one case positive to polysorbate 80.

Anti-EPO antibodies: radioimmunoprecipitation assay (RIPA).

■ Mechanisms

One case of anaphylaxis to gelatin included in erythropoietin products.

Polysorbate 80 allergy (2 cases).

High concentration of polysorbate 80 in the formulation of epoetin alfa leads to micelle formation. Epoetin molecules are integrated into the surface of these micelles, so several epoetin molecules are presented to the immune system in a regular spacial configuration which can trigger the immune system (pure red cell aplasia).

■ Management

Discontinue epoetin.

Corticosteroids +/- cyclophosphamide; cyclosporine, kidney transplant (pure red cell aplasia).

References

Steele RH, Limaye S, Cleland B, et al. Hypersensitivity reactions to the polysorbate contained in recombinant erythropoietin and darbepoietin. *Nephrology* 2005;10:317-20.

Schellekens H. Factors influencing the immunogenicity of therapeutic proteins. *Nephrol Dial Transplant* 2005;20:vi3-9.

Rossert J, Casadevall N, Ekardt KU. Anti-erythropoietin antibodies and pure red cell aplasia. *J Am Soc Nephrol* 2004;15:398-406.

Limaye S, Steele RH, Quin J, et al. An allergic reaction to erythropoietin secondary to polysorbate hypersensitivity. *J Allergy Clin Immunol* 2002;110:530.

Etoposide

A semi-synthetic derivative of podophyllotoxin, active against a number of tumors: germ cell neoplasms, small cell lung carcinoma and malignant lymphoma.

■ Incidence

1% (93 cases reported up to 1996, 3 deaths)
High incidence in children with Hodgkin's disease.

■ Risk factors

Intravenous route.

■ Clinical manifestations

- **General:** hypotension, hypertension (rare), fever, chills, tachycardia.
- **Cutaneous:** facial flushing, exanthema, urticaria is uncommon.
- **Respiratory:** bronchospasm, chest tightness, dyspnea.

■ Diagnostic methods

No *in vivo* or *in vitro* method is currently available for diagnosis.

■ Mechanisms

Non-specific histamine release.

The role of polysorbate 80 (Tween 80) used as an excipient in the parenteral formulation is doubtful.

■ Management

Use etoposide phosphate (water soluble prodrug of etoposide).

Use oral etoposide when possible (no hypersensitivity reaction).

Lower the infusion rate.

Continuous administration without modification (65% successful)

Premedication with antihistamines and/or corticosteroids.

References

Collier K, Schink C, Young AM, et al. Successful treatment with etoposide phosphate in patients with etoposide hypersensitivity. *J Oncol Pharm Pract* 2008;14:51-5.

Siderov J, Prasad P, De Boer R, et al. Safe administration of etoposide phosphate after hypersensitivity to intravenous etoposide *Br J Cancer* 2002;86:12-3.

Bernstein BJ, Troner MB. Successful rechallenge with etoposide phosphate after an acute hypersensitivity reaction to etoposide. *Pharmacotherapy* 1999;19:989-91.

Hoetelmans RM., Schornagel JH, ten Bokkel Huinink WW, Beijnen JH. Hypersensitivity reactions to etoposide. *Ann Pharmacother* 1996;30:367-71.

Hudson MM, Weinstein HJ, Donaldson SS, et al. Acute hypersensitivity reactions to etoposide in a VEPA regimen for Hodgkin's disease. *J Clin Oncol* 1993;11:1080-4.

Kellie SJ, Crist WM, Pui CH, et al. Hypersensitivity reactions to epidophyllotoxins in children with acute lymphoblastic leukemia. *Cancer* 1991;67:1070-5.

Fludarabine

A purine analogue used in the treatment of lymphoproliferative disorders.

■ Clinical manifestations

- **Cutaneous:** maculopapular rash, edema, acral erythema, paraneoplastic pemphigus, stomatitis, alopecia, psoriasis exacerbation.
- **Others:** renal failure.

■ Diagnostic methods

None.

■ Mechanisms

Unknown.

■ Management

Avoidance.

References

Jordan J, Mey U, Bieber T, et al. Paradoxical exacerbation of psoriasis during therapy with fludarabine. *Eur J Dermatol* 2008;18:365-6.

Yildiz O, Ozguroglu M, Yanmaz MT, et al. Paraneoplastic pemphigus associated with fludarabine. *Med Oncol* 2007;24:115-8.

5-fluorouracil

A pyrimidine analogue used for the treatment of several types of malignancies. Topical 5-FU is widely used for the treatment of actinic keratosis and warts in some countries.

■ Incidence

Unknown.

■ Risk factors

Seborrheic dermatitis (palmar-plantar dermatitis).

Iterative long-term topical applications.

Anti-Ssa/Ro antibodies (acral erythema, discoid-lupus-erythematosus-like lesion).

■ Clinical manifestations

• **General:** anaphylactic shock (4 cases reported).

• **Cutaneous:** hand-foot syndrome, acral erythema, maculopapular eruption, pigmentation (sometimes serpentine hyperpigmentation streaks; nails), lupus erythematosus-like lesions, photosensitivity, injection site reactions, xerosis. With topical use: contact dermatitis and irritant dermatitis, photosensitivity. Stomatitis, alopecia.

■ Diagnostic methods

Skin tests

One case with intradermal test positive (anaphylactic shock).

Patch tests and photopatch tests with 0.5-1% 5-FU in pet (with caution).

No specific IgE found.

■ Mechanisms

IgE-mediated hypersensitivity (one case of anaphylactic shock).

Probable direct cytotoxic effect of 5-FU (palmar-plantar dermatitis).

■ Management

Avoidance.

Desensitization (continuous intravenous protocol): one case.

References

Adachi A, Nagai H, Horikawa T. Anti-Ssa/Ro antibody as a risk factor for fluorouracil-induced drug eruption showing acral erythema and discoid-lupus-erythematosus-like lesions. *Dermatology* 2007;214:85-8.

Jain V, Bhandary S, Prasad GN, et al. Serpentine supravenuous streaks induced by 5-fluorouracil. *J Am Acad Dermatol* 2005;53:529-30.

Eppinger T, Sperber K. Desensitization to 5-fluorouracil. *Allergy Asthma Proc* 1999;20:189-91.

Nadal C, Pujol R.M, Randazzo L, et al. Systemic contact dermatitis from 5-Fluorouracil. *Contact Dermatitis* 1996;35:124-5.

Milla Santos A, Sanchiz Medina F. Anaphylactic reaction following i.v administration of 5-fluorouracil (letter). *Cancer Treat Rep* 1986;70:1346.

Gemcitabine

2'-2'- difluorodeoxycytidine is a recently developed pyrimidine antagonist structurally related to cytarabine. Used in the treatment of non-small-cell lung cancer.

■ Clinical manifestations

- **Cutaneous:** macular or maculopapular rash (30%), pruritus, hand-foot syndrome, fixed erythrodermia plaque, recall dermatitis, bullous dermatitis, linear IgA bullous dermatitis, scleroderma-like reaction; acute lipodermatosclerosis-like reaction, pseudo-lymphoma, erysipeloid skin toxicity, Stevens-Johnson syndrome, toxic epidermal necrolysis, vasculitis, stomatitis, alopecia.

- **Respiratory:** hypersensitivity pneumonitis.

■ Diagnostic methods

None.

■ Mechanisms

Unknown.

■ Management

Avoidance.

References

Zustovich F, Pavei P, Cartei G. Erysipeloid skin toxicity induced by gemcitabine. *J Eur Acad Dermatol Venereol* 2006;20:757-8.

Sommers KR, Kong KM, Bui DT, et al. Stevens-Johnson syndrome/toxic epidermal necrolysis in a patient receiving concurrent radiation and gemcitabine. *Anticancer Drugs* 2003;14:659-62.

Jeters MD, Jänne PA, Brooks S, et al. Gemcitabine-induced radiation recall. *Int J Radiat Oncol Bio Phys* 2002;53:394-400.

Kudrik FJ, Rivera MP, Molina PL, et al. Hypersensitivity pneumonitis in advanced non-small-cell lung cancer patients receiving gemcitabine and paclitaxel; report of two cases and a review of the literature. *Clin Lung Cancer* 2002;4:52-6.

Hydroxyurea

An antimetabolite acting primarily on cells in S phase. It is used in patients with myeloproliferative disorders.

I Incidence

Cutaneous manifestations: 10 to 35% of patients.

Fever: 15 cases published (up to 1997).

I Clinical manifestations

- **General:** fever, appearing within the first few weeks after first exposure; disappearing rapidly after discontinuation.
- **Cutaneous:** xerosis (frequent), cutaneo-mucous ulcerations (frequent): leg ulcers and oral ulcerations, dermatomyositis-like eruption (classic), lichen planus-like eruption (sometimes ulcerative), lupus erythematosus (rare), cutaneous diffuse hyperpigmentation, nails and oral pigmentation, acral manifestations: erythema, keratoderma, desquamation, livedoid manifestations, stomatitis, cutaneous atrophy, alopecia, actinic keratosis, induced carcinoma, nails alterations.
- **Respiratory:** hypersensitivity pneumonitis (rare).

I Diagnostic methods

Skin biopsy: epidermal thickening, flattening of the dermoepidermal junction, basal layer degeneration, colloid body formation.

Lung biopsy: alveolar and interstitial inflammation.

I Mechanisms

Cutaneous reactions: Lichenoid hypersensitivity reaction?
Hydroxyurea toxicity on the basal layer of the epidermis?

I Management

Hydroxyurea can be continued if necessary with no worsening of cutaneous lesions.

References

- Dacey MJ, Callen JP. Hydroxyurea-induced dermatomyositis-like eruption. *J Am Acad Dermatol* 2003;48:439-41.
- Sandhu HS, Barnes PJ, Hernandez P. Hydroxyurea-induced hypersensitivity pneumonitis: a case report and literature review. *Can Respir J* 2000;7:491-5.
- Sirieix ME, Debure C, Baudot N, et al. Leg ulcers and hydroxyurea: forty-one cases. *Arch Dermatol* 1999;135:818-20.
- van der Klooster J.M, Sucec P.M, Stiegelis WF, et al. Fever caused by hydroxyurea: a report of three cases and review of the literature. *Neth J Med* 1997;51:114-8.
- Senet P, Aractingi S, Porneuf M, et al. Hydroxyurea-induced dermatomyositis-like eruption. *Br J Dermatol* 1995;133:455-9.

5 hydroxytryptamine 3 receptor antagonists (5-HT₃)

Granisetron, ondansetron, tropisetron and dolasetron are used for prevention of nausea and vomiting associated with cancer chemotherapy.

■ Incidence

Uncommon.

Ondansetron: 78 cases (FDA 1997).

Tropisetron: 11 cases.

■ Risk factors

Previous reaction with another 5-HT₃ receptor antagonist.

■ Clinical manifestations

Differentiate from non-allergic side effects (headache, gastrointestinal symptoms).

- **General:** anaphylactic shock.
- **Cutaneous:** pruritus, rash, urticaria, facial edema, fixed drug eruption.
- **Respiratory:** bronchospasm, chest pain.

■ Diagnostic methods

Skin tests

Prick tests: ondansetron: 2 mg/ml, dolasetron: 20 mg/ml, granisetron: 1 mg/ml.

Intradermal tests: ondansetron: 0.2 mg/ml positive in one patient.

Challenge test: positive

■ Mechanisms

IgE-mediated hypersensitivity in some cases.

Ondansetron and tropisetron share an indole heterocycle, ondansetron and granisetron do not, which explains the absence of cross reactivity between these two drugs.

■ Management

Switch to another 5-HT₃ receptor antagonist after cutaneous testing and intravenous challenge.

References

- Bousquet PJ, Co-Minh HB, Demoly P. Isolated urticaria to ondansetron and successful treatment with granisetron. *Allergy* 2005;60:543-4.
- Kanny G, Beaudouin E, Moneret-Vautrin DA. IgE-mediated allergy to granisetron and safe use of ondansetron. *J Allergy Clin Immunol* 2001;108-6:1059-60.
- Weiss KS. Anaphylactic reaction to ondansetron. *Arch Intern Med* 2001;161:2263.
- Frigerio C, Buchwalder PA, Spertini F. Ondansetron: reasons to be restrictive. *Lancet* 1996;347:1484-5.
- Kataja V, de Bruijn K.M. Hypersensitivity reactions associated with 5 hydroxytryptamine 3 receptor antagonists: a class effect ?. *Lancet* 1996;347:584-5.

Imatinib mesylate

A recently developed oral anticancer agent rationally designed to selectively inhibit certain protein tyrosine kinases implicated in oncogenesis. Used in the treatment of chronic myeloid leukaemia and malignant gastrointestinal stromal tumors.

■ Incidence

31-44% of cutaneous reactions.

21% of mild to moderate reactions at doses of 600 mg and higher.

Severe exfoliative rashes: 1/500.

■ Clinical manifestations

- **Cutaneous:** rash (maculopapular eruption), edema (face, eyelids +++), sometimes severe and with ocular complications), and pruritus are the most frequent reactions. Severe adverse reactions: Stevens-Johnson syndrome, acute generalized exanthematous pustulosis, DRESS syndrome. Others: cutaneous and oral lichenoid induced eruption, pityriasis-rosea-like eruption, vasculitis, cutaneous hypo- and de-pigmentation associated with photosensitivity, hyperpigmentation (skin, nails and hair), exacerbation of psoriasis or induced acral psoriasiform hyperkeratosis.

- **Respiratory:** hypersensitivity pneumonitis.

■ Mechanisms

Changes in tyrosine kinase signaling (altered c-Kit affects the development of epidermal inflammation).

■ Management

Prednisone 1 mg/kg/day tapered to 20 mg/day over several weeks and gradual reintroduction of imatinib 100mg/day initially increased by 100 mg/week as the prednisone dose is being tapered.

Desensitization (4h): starting with 10 mg, increasing doses/ 15 mn.

References

Nelson RP Jr, Cornetta K, Ward KE, et al. Desensitization to imatinib in patients with leukaemia. *Ann Allergy Asthma Immunol* 2006;97:216-22.

Le Nouail P, Viseux V, Chaby G, et al. Drug reaction with eosinophilia and systemic symptoms (DRESS) following imatinib therapy (Glivec®)- (Article in French). *Ann Dermatol Venereol* 2006;113:686-8.

Schmutz JL, Barbaud A, Trechot P. Cutaneous side effects with imatinib (Glivec®) (Article in French). *Ann Dermatol Venereol* 2004;131:517-8.

Park MA, Volcheck GW, Guarderas JC. Successful progressive challenge after a cutaneous reaction to imatinib mesylate (Gleevec®): a case report and review of the literature. *Allergy Asthma Proc* 2004;25:345-7.

Guilhot F. Indications for imatinib mesylate therapy and clinical management. *The Oncologist* 2004;9:271-81.

Imiquimod

An immune response modifier approved for the treatment of external genital warts, actinic keratosis and superficial basal cell carcinoma.

I Clinical manifestations

- **Cutaneous:** local skin reactions are frequent, mild to moderate. In some cases, the reaction may be severe. Local reactions (frequent): erythema, erosion, excoriation, edema, desquamation, pruritus, burning, pain, localized hyperpigmentation or hypopigmentation, infections. Others local reactions (less frequent): dysuria, localized pemphigus foliaceus, aphthous ulcers after treatment of actincheilitis, angioedema. Systemic reactions: erythema not strictly localized to the site of application, exacerbation of psoriasis (generalized reaction), exacerbation of eczema.

- **Respiratory:** hypersensitivity pneumonitis.

I Mechanisms

Unkown.

I Management

Avoidance.

References

Taylor CL, Maslen M, Kapembwa M. A case of severe eczema following use of imiquimod 5% cream. *Sex Transm Infect* 2006;82:227-8.

Rajan N, Langtry JA. Generalized exacerbation of psoriasis associated with imiquimod cream treatment of superficial basal cell carcinoma. *Clin Exp Dermatol* 2006;31:140-1.

Chakarabarty AK, Mraz S, Geisse JK, et al. Aphthous ulcers associated with imiquimod and the treatment of actinic cheilitis. *J Am Acad Dermatol* 2005;52:35-7.

Brown T, Zirvi M, Cotsarleris G, et al. Vitiligo-like hypopigmentation associated with imiquimod treatment of genital warts. *J Am Acad Dermatol* 2005;52:715-6.

Barton JC. Angioedema associated with imiquimod. *J Am Acad Dermatol* 2004;51:477-8.

L-asparaginase

Polypeptide of bacterial origin (*E. coli*) widely used in the treatment of acute lymphoblastic leukemia in children and adults.

■ Incidence

Highest of all antimetabolic agents.

Intravenous route: 15 to 33%.

Intramuscular route: 6 to 24%.

Deaths reported.

■ Risk factors

Intravenous use.

Hiatus of 1 month or more between two courses.

Not associated with prednisone or vincristine.

Prior exposure months or years previously.

Young age.

White race.

Standard risk acute lymphoblastic leukemia.

■ Clinical manifestations

• **General:** anaphylactic shock.

• **Cutaneous:** pruritus, rash, urticaria, angioedema, toxic epidermal necrolysis (rare), stomatitis.

• **Respiratory:** laryngospasm, bronchospasm.

■ Diagnostic methods

Skin tests

Prick tests (2000 UI/ml) and intradermal tests (2 UI).

Not effective (false positive and false negative).

Specific IgE.

Increased specific IgE antibodies found in patients in whom L-asparaginase infusions are followed by allergic reactions.

Specific IgM and IgG (microtiter solid-phase radioimmunoassay).

High titers of IgG3 or IgG4 anti L-asparaginase may predict L-asparaginase allergy.

Complement activation (C3d).

L-asparaginase-specific IgG antibodies bind and activate the complement system.

Tryptase levels: elevated at the time of reaction.

I Mechanisms

IgE-mediated hypersensitivity: a few cases have been reported.

Complement activation induced by formation of immune complexes of L-asparaginase and specific IgM and IgG class antibodies.

Leukotriene production by bone marrow-derived mast cells.

I Management

Avoidance, but hypersensitivity reactions to L-asparaginase do not impact on the remission duration in adults and childrens with acute lymphoblastic leukemia.

Use of alternative formulations:

- L-asparaginase derived from *Erwinia chrysantemum*: fewer anaphylactic reactions (22.6% cross-allergy with *Escherichia Coli* L-asparaginase).
- Pegaspargase, pegylated form of asparaginase (pegylation increases the drug hydrodynamic radius, prolongs plasma retention time decreases proteolysis and renal excretion). Pegaspargase is approved by FDA as first line treatment of children with acute lymphocytic leukemia.

Desensitization.

Children: from 1.2 U/hour over 4.2 hours to 1200 U/hour over 3.8 hours.

Adults: 50 UI to 25600 UI (9 injections) in 4.5 hour.

References

- Dinndorf PA, Gootenberg J, Cohen MH, et al. Treatment of children with acute lymphoblastic leukaemia. *Oncologist* 2007;12:991-8.
- Marin Pozo JF, Carmona Alvarez MT, Toledo Lopez A, et al. Asparaginase desensitization in two patients with previous hypersensitivity. *Farm Hosp* 2006;30:132-4.
- Bonno M, Kawasaki H, Hori H, et al. Rapid desensitization for L-asparaginase hypersensitivity. *J Allergy Clin Immunol* 1998;101:571-2.
- Larson RA, Fretzin MH, Dodge RK, et al. Hypersensitivity reactions to L-asparaginase do not impact on the remission duration of adults with acute lymphoblastic leukaemia. *Leukemia* 1998;12:660-5.
- Stone HD Jr, DiPiro C, Davis PC, et al. Hypersensitivity reactions to *Escherichia Coli* derived polyethylene glycolated-asparaginase associated with subsequent immediate skin-test reactivity to *E. coli*-derived granulocyte colony stimulating factor. *J Allergy Clin Immunol* 1998;101:429-31.
- Ettinger LJ, Kurtzberg J, Voute PA, et al. An open-label multicenter study of polyethyleneglycol-L-asparaginase for the treatment of acute lymphoblastic leukaemia. *Cancer* 1995;75:1176-81.

Lenalidomide

An oral bioavailable analogue of thalidomide with more potent immunomodulatory, antiangiogenic and antitumor activities and a better safety profile. Promising treatment for multiple myeloma and primary amyloidosis.

■ Incidence

High.

■ Risk factors

Amyloidosis.

■ Clinical manifestations (occurring in the first month of treatment)

- **Cutaneous:** pruritus, rash (morbilliform, urticarial, dermatitic, acneiform) moderate to severe in 27% of cases (occurring mainly in the first month).
- **Respiratory:** hypersensitivity pneumonitis.

■ Diagnostic methods

None.

■ Mechanisms

Unknown.

■ Management

Dexametasone does not prevent dermatologic side effects.

Desensitization (one case).

References

Phillips J, Kujawa J, Davis-Lorton M, et al. Successful desensitization in a patient with lenalidomide hypersensitivity. *Am J Hematol* 2007;82:1030.

Sviggum HP, Davis MDP, Rajkumar V, et al. Dermatologic adverse effects of lenalidomide therapy for amyloidosis and multiple myeloma. *Arch Dermatol* 2006;142:1298-1302.

Mechlorethamine

An antimitotic alkylating agent known as nitrogen mustard which is administered intravenously in the treatment of hematological disorders and applied topically in the treatment of mycosis fungoides and other cutaneous T-cell lymphomas and severe psoriasis.

■ Incidence

Frequent when applied topically.

Uncommon when administered intravenously.

■ Clinical manifestations

- **General:** anaphylactic shock.

- **Cutaneous:** pruritus, urticaria, angioedema. Local erythema and pruritus due to irritant reactions, contact delayed hypersensitivity or allergic contact dermatitis (frequent with topical use: more than 50% of treated patients in the first 3 months). Others: erythema multiforme-like dermatitis, bullous reactions, Stevens-Johnson syndrome, xerosis, hyperpigmentation, induced squamous cell carcinoma.

- **Respiratory:** dyspnea.

■ Diagnostic methods

Skin tests: prick tests and patch tests positive in patients with reactions to topical mechlorethamine.

Patch tests: aqueous mechlorethamine solution (0.02%) with 1/10, 1/100, and 1/1000 dilutions.

■ Mechanisms

Unknown for immediate reactions.

Cell-mediated hypersensitivity for contact dermatitis.

■ Management

Desensitization (IV or preferentially topical) in patients with cutaneous T-cell lymphoma treated with topical mechlorethamine.

Dilutions of the solution in water: from 10 mg/1200 ml to 10 mg/1800 ml every day for a week. If tolerated, double the dose the following week until a tolerable dilution is reached.

Other protocol: twice weekly application with topical betamethasone.

Desensitization is not always successful.

References

Quatrebarbes J, Esteve E, Bagot M, et al. Treatment of early-stage mycosis fungoides with twice-weekly applications of mechlorethamine and topical corticosteroids. *Arch Dermatol* 2005;141:1117-20.

Esteve E, Bagot M, Joly P, et al. A prospective study of cutaneous intolerance to topical mechlorethamine therapy in patients with cutaneous T-cell lymphomas. *Arch Dermatol* 1999;135:1349-53.

Ramsay DL, Halpern PS, Zeleniuch-Jacquotte A. Topical mechlorethamine therapy for early stage mycosis fungoides. *J Am Acad Dermatol* 1988;19:684-91.

Pariser DM, Childers RC, Kechjian P, et al. Intravenous desensitization to mechlorethamine in patients with psoriasis. *Arch Dermatol* 1976;112:1113-4.

Constantine VS, Fuks ZY, Farber EM. Mechlorethamine desensitization in therapy for mycosis fungoides. Topical desensitization to mechlorethamine (nitrogen mustard) contact hypersensitivity. *Arch Dermatol* 1975;111:484-8.

Melphalan

A nitrogen mustard class cytostatic alkylating agent used as a first line drug in the treatment of multiple myeloma.

■ Incidence

2.4% (intravenous route).

Uncommon when administered orally (0.3%).

No deaths reported.

■ Risk factors

IgA multiple myeloma (55% of cases).

Intravenous route.

■ **Clinical manifestations** (at least 2 prior doses, up to 28 previous doses).

• **General:** anaphylactic shock.

• **Cutaneous:** pruritus, rash, urticaria, angioedema. Stomatitis, erythema and oedema (slight or severe with blistering and pain), localized scleroderma (with isolated limb perfusion with melphalan).

• **Respiratory:** interstitial pneumonitis.

■ Diagnostic methods

Leukocyte migration inhibition test: one positive test in a case of interstitial pneumonitis.

■ Mechanisms

Alkylation reaction may occur in vivo, and altered proteins may serve as new antigens capable of stimulating antibodies to the hapten-protein complex.

■ Management

Avoidance of the intravenous route. Some reactive patients may be switched to oral melphalan with no further reaction.

Cross reactivity with other alkylating agents is exceptional (cyclophosphamide).

References

Landau M, Brenner S, Gat A, et al. Reticulate scleroderma after isolated limb perfusion with melphalan. *J Am Acad Dermatol* 1998;39:1011-2.

Weiss RB. Hypersensitivity reactions. *Semin Oncol* 1992;19:458-77.

Liote H, Gauthier JF, Prier A, et al. Acute, reversible, interstitial pneumopathy induced by melphalan (Article in French). *Rev Mal Respir* 1989;6:461-4.

Lawrence BV. Anaphylaxis due to oral melphalan. *Cancer Treat Rep* 1980;64:731-2.

Cornwell GG III, Pajak TF, Mc Intyre OR. Hypersensitivity reactions to IV melphalan during treatment of multiple myeloma: Cancer and Leukemia Group B experience. *Cancer Treat Rep* 1979;63:399-403.

Mesna

Mesna (2 -mercaptoethane sulphonate) is a thiol compound is used to prevent hemorrhagic cystitis, which is a complication of cyclophosphamide treatment.

■ Incidence

High.

■ Risk factors

Autoimmune disorders.

■ Clinical manifestations

- **General:** fever, arthralgia, myalgia, tachycardia (perimyocarditis).
- **Cutaneous:** pruritus, urticaria, angioedema, rash, fixed drug eruption, contact dermatitis.
- **Digestive:** diarrhea.

■ Diagnostic methods

Skin tests: prick tests, intradermal tests and patch tests are positive in a few cases.

No specific IgE found.

■ Mechanisms

Unknown.

■ Management

Benefits of mesna outweigh the risk of allergic reactions.
Corticosteroids may be useful.

References

- Khaw SL, Downie PA, Waters KD. Adverse hypersensitivity reactions to mesna as adjunctive therapy fo cyclophosphamide. *Pediatr Blood Cancer* 2007; 49:341-3.
- Benyoussef K, Bottlaender A, Pfister HR, et al. Allergic contact dermatitis from mesna. *Contact Dermatitis* 1996;34:228-9.
- Reinhold-Keller E, Mohr J, Christophers E, et al. Mesna side effects which imitate vasculitis. *Clin Investig* 1992;70:698-704.
- Zonzits E, Aberer W, Tappeiner G. Drug eruptions from mesna. After cyclophosphamide treatment of patients with systemic lupus erythematosus and dermatomyositis. *Arch Dermatol* 1992;128:80-2.

Methotrexate

A folic acid antagonist used in the treatment of several neoplasms and inflammatory disorders.

■ Incidence

Anaphylactic shock: about 20 cases reported.

■ Clinical manifestations (also described with intrathecal administration)

- **General:** anaphylactic shock.
- **Cutaneous:** acneiform eruption, acral erythema (sometimes bullous), pruritus, rash, papular and nodular eruption, urticaria, erythema multiforme, Stevens-Johnson syndrome, toxic epidermal necrolysis, vasculitis, erosion of psoriatic plaques, radiation recall dermatitis, photorecall, photosensitivity, pigmentation, cutaneous infections, oral ulcerations, gingivitis, stomatitis, glossitis, nail alterations (onycholysis, pigmentation), paronychia, alopecia.
- **Respiratory:** pulmonary infiltrates (the most frequent manifestation of methotrexate pulmonary toxicity), bronchospasm.
- **Hematological:** pancytopenia, agranulocytosis, hemolytic anemia.

■ Diagnostic methods

Skin tests

Prick test: with methotrexate 10 mg/ml. One positive case (anaphylactic shock).

Intradermal test: 0.1 ml of 25 mg/ml solution of methotrexate. Positive reaction in one case; complicated by syndromic reaction (anaphylactic shock).

No specific IgE found.

No specific histamine release shown.

Drug induced lymphocyte stimulation test (DLST): positive in 2 cases of pancytopenia and one case of agranulocytosis.

IgG3 antibody in a case of hemolytic anemia.

■ Mechanisms

Type I reactions: anaphylaxis, urticaria, angioedema.

Type II reactions: hemolytic anemia.

Type III reactions: acute pneumonitis, cutaneous vasculitis.

I Management

If no alternative therapy exists and there is a non life-threatening hypersensitivity reaction, re-challenge may be considered.

Most of the time (92%) there are recurrent symptoms despite premedication.

Desensitization is sometimes used (for example, from 0.1 mg up to 25 mg in 60 hours).

References

Werchmiak AE, Chaffe S, Dinulos JG. Methotrexate-induced bullous acral erythema in a child. *J Am Acad Dermatol* 2005;53:593-5.

MacGinnitie AJ, Walensky LD, Turvey SE, et al. Management of an anaphylactoid reaction to methotrexate with a stepwise graded challenge. *Pediatr Allergy Immunol* 2003;14:409-11.

Davis KA, Williams P, Walker JC. Successful desensitization to high-dose methotrexate after systemic anaphylaxis. *Ann Allergy Asthma Immunol* 2003;90:87-9.

Goerttler E, Kutzner H, Piter HH, et al. Methotrexate-induced papular eruption in patients with rheumatic disease: a distinctive adverse cutaneous reaction produced by methotrexate in patients with collagen vascular diseases. *J Am Acad Dermatol* 1999;40:702-7.

Alkins SA, Byrd JG, Morgan SK, et al. Anaphylactoid reactions to methotrexate. *Cancer* 1996;77:2123-6.

Vega A, Cabanas R, Contreras J, et al. Anaphylaxis to methotrexate: a possible IgE-mediated mechanism. *J Allergy Clin Immunol* 1994; 94:268-70.

Mitomycin

An antitumor antibiotic derived from *Streptomyces caespitosus*; widely used for treatment and prevention of superficial bladder cancer (intravesical instillation).

■ Incidence

Cutaneous side-effects: 9% of patients treated with intravesical instillations.

■ Risk factors

Association with vincristine, bleomycin or doxorubicin.

■ Clinical manifestations

- **Cutaneous:** injection-site reactions (sometimes severe with necrosis and gangrene of penis, cellulitis), irritant contact dermatitis, allergic contact dermatitis; vesicular dermatitis of the hands and feet and/or dermatitis of the genitals or more widespread eruptions.
- **Respiratory:** interstitial lung disease.
- **Others:** eosinophilic cystitis.

■ Diagnostic methods

Skin tests

Intradermal test: one immediately positive intradermal test reported in a patient with an immediate reaction.

Patch tests (concentration ranging from 0.06% to 0.6% in water or in petrolatum) positive in patients with contact allergy.

■ Mechanisms

Presence of CD I + has been shown in bladder epithelium.

Eczematous eruptions are type IV hypersensitivity reactions; mediated transvesically.

■ Management

Avoidance.

Topical corticosteroids may be useful.

References

- Kureshi F, Kalaaji AN, Halvorson L, et al. Cutaneous complications of intravesical treatments for bladder cancer: granulomatous inflammation of the penis following BCG therapy and penile gangrene following mitomycin therapy. *J Am Acad Dermatol* 2006;55:328-31.

Fidalgo A, Lobo L. Allergic contact sensitization from intravesical mitomycin C, without dermatitis. *Dermatitis* 2004;15:161-2.

Kunkeler L, Nieboer C, Bruynzeel DP. Type III and type IV hypersensitivity reactions due to mitomycin C. *Contact Dermatitis* 2000;42:74-6.

de Groot AC, Conemans J.M. Systemic allergic contact dermatitis from intravesical instillation of the antitumor antibiotic mitomycin. *Contact Dermatitis* 1991;24:201-9.

Colver GB, Inglis JA, Mc Vittie E, et al. Dermatitis due to intravesical mitomycin C: a delayed-type hypersensitivity reaction ? *Br J Dermatol* 1990;122:217-24.

Mitoxantrone

Mitoxantrone (DHAD) has been synthesized by systematic substitution on the basic anthraquinone nucleus. It is used in the treatment of refractory cancers (advanced breast cancer).

■ Incidence

Less than 1%.

■ Clinical manifestations

General: anaphylactic shock.

Cutaneous: injection-site reactions: pain, burning, pigmentation (bluish), necrosis (rare), rash, edema, purpura (with thrombocytopenia), discoloration of the nails, stomatitis, alopecia.

Respiratory: one case of occupational asthma.

■ Diagnostic methods

Skin biopsy: leukocytoclastic vasculitis in a case of erythematous vesicular rash.

■ Mechanisms

Unknown.

■ Management

Avoidance.

References

Walusiak J, Wittezak T, Ruta U, et al. Occupational asthma due to mitoxantrone. *Allergy* 2002;57:461.

Taylor WB, Cantwell BM, Roberts JT, et al. Allergic reactions to mitoxantrone. *Lancet* 1986;1(8495):1439.

Anderson KC, Cohen GI, Garnick MB. Phase II trial of mitoxantrone. *Cancer Treat Rep* 1982;66:1929-31.

Mycophenolate mofetil

Potent immunosuppressive agent blocking purine synthesis and inhibiting T and B lymphocyte proliferation, used in the treatment of refractory myasthenia gravis and lupus erythematosus. Also used in association with cyclosporine for graft reject prevention.

■ Clinical manifestations

- **General:** anaphylatic shock and angioedema (rare).
- **Cutaneous (frequent and various):** rash, sometimes severe, maculopapular or psoriasiform; acneiform eruption, edema (peripheral), gingival hypertrophy, stomatitis, oral ulcerations. Others: carcinoma, cutaneous and mucosal infections (viral and mycotic), alopecia.
- **Respiratory:** cough, pulmonary fibrosis, acute permeability edema with or without ARDS.

■ Diagnostic methods

None.

■ Mechanisms

Unknown.

■ Management

Desensitization.

References

Szyper-Kravitz M, Sheinberg P, Sidi Y, et al. Hypersensitivity to mycophenolate mofetil in systemic lupus erythematosus: diagnostic measures and successful desensitization. *Int Arch Allergy Immunol* 2005;138:334-6.

Levin N, Mali A, Karussis D. Severe skin reaction related to mycophenolate mofetil for myasthenia gravis. *Clin Neuropharmacol* 2005;28:152-3.

Oxaliplatin

Third generation organoplatinum complex used as an antineoplastic agent in combination with fluorouracil and leucovorin for colorectal carcinoma.

■ Incidence

12 to 16%.

■ Clinical manifestations

Generally after 7 to 9 cycles, within minutes following infusion initiation.

- **General:** anaphylactic shock, fever.
- **Cutaneous:** pruritus, urticaria, erythema, flushing, angioedema, rash, hand-foot syndrome, radiation recall dermatitis.
- **Respiratory:** wheezing, dyspnea.
- **Digestive:** nausea, abdominal cramping.

■ Diagnostic methods

Skin tests

Prick tests: 0.1 mg/ml to 10 mg/ml

Intradermal tests: 0.001 mg/ml to 1 mg/ml

■ Mechanisms

IgE-mediated hypersensitivity.

Cytokine release.

■ Management

Pretreatment with intravenous calcium gluconate and magnesium sulfate.

Pretreatment with dexamethasone or methylprednisolone, diphenhydramine, cimetidine 30 minutes before oxaliplatin infusion.

Desensitization in 4 to 8 h, starting at 1/10,000 to a cumulative goal dose of 175 mg (0.003 mg/mn with increasing doses every 30 to 60 minutes until 0.75 mg/mn).

References

- Syrigou E, Syrigos K, Saif MW. Hypersensitivity reactions to oxaliplatin and other antineoplastic agents. *Curr Allergy Asthma Rep* 2008;8:56-62.
- Pagani M, Bonadonna P, Senna GE, et al. Standardization of skin tests for diagnosis and prevention of hypersensitivity reactions to oxaliplatin *Int Arch Allergy Immunol* 2008;145:54-7.
- Rosique-Robles D, Vicent Verge JM, Borrás-Blasco J, et al. Successful desensitization protocol for hypersensitivity reactions caused by oxaliplatin. *Int J Clin Pharmacol Ther* 2007;45:606-10.
- Edmondson DA, Gruling BJ, Urmanski Am, et al. Oxaliplatin hypersensitivity: case report and successful repeat desensitization. *Am J Ther* 2007;14:116-8.
- Herrero T, Tornero P, Infante S, et al. Diagnosis and management of hypersensitivity reactions caused by oxaliplatin. *J Investig Allergol Clin Immunol* 2006;16:327-30.
- Siu SW, Chan RT, Au GK. Hypersensitivity reactions to oxaliplatin: experience in a single institute. *Ann Oncol* 2006;17:259-61.
- Maindrault-Goebel F, Andre T, Tournigand C, et al. Allergic-type reactions to oxaliplatin: retrospective analysis of 42 patients. *Eur J Cancer* 2005;41:2262-7.

Paclitaxel

A taxane anti-neoplastic agent causing irreversible microtubule aggregation with activity against breast, ovarian, lung, head and neck, bladder, testicular, oesophageal, endometrial and other less common tumors; derived from the bark of the Pacific yew tree (*Taxus brevifolia*).

■ Incidence

10 to 16% without premedication.

1.3% severe hypersensitivity reactions (with oral premedication).

Deaths reported.

■ Risk factors

Atopy.

Bee sting allergy.

Ovarian cancer: mild cutaneous reactions in previous courses, respiratory dysfunction, obesity, post-menopausal.

■ Clinical manifestations (usually first or second dose)

• **General:** hypotension, hypertension.

• **Cutaneous:** acral erythema, injection site reaction, generalized pustular eruption (AGEP-like), fixed drug eruption, radiation recall dermatitis, photosensitivity, scleroderma-like lesions, subacute cutaneous lupus erythematosus, erythema multiforme, Stevens-Johnson syndrome (very rare), mucosal reactions (frequent), onycholysis.

• **Respiratory:** bronchospasm, chest pain, dyspnea, hypersensitivity pneumonitis.

Systemic and intra-stent (paclitaxel-eluting coronary stents) hypersensitivity reactions have been described, leading to thrombosis and death.

■ Diagnostic methods

Basophil histamine release: non IgE-mediated response.

■ Mechanisms

Cremophor EL, a diluent made up of polyoxyethylated castor oil is believed to be the primary cause of paclitaxel-related hypersensitivity reactions by complement activation.

Substance P is involved in paclitaxel hypersensitivity.

Generation of reactive metabolites leading to complement activation or direct action on mast cells and basophils.

■ Management

Premedication.

Oral dexamethasone: 20 mg, 12 and 6 hour before infusion.

Intravenous premedication: dexamethasone 10 or 20 mg, diphenhydramine 50 mg, cimetidine 300

mg or ranitidine 50 mg, 30 minutes before paclitaxel infusion.

Test dose.

1 mg to 12 mg paclitaxel/10 ml normal saline: negative predictive value 98.4%.

Desensitization.

3 solutions/12 step protocol: 3.8 H outpatient administration, 5.8 H inpatient administration.

Other possibilities.

Switch to Docetaxel (diluted and solubilized with tween 80); cross-sensitivity has been shown to be high, up to 90%.

Use Abraxane: a solvent-free taxane.

References

- Castells M. *Drug desensitization in oncology: chemotherapy agents and monoclonal antibodies*. Pichler WJ (ed): *Drug Hypersensitivity*. Basel, Karger, 2007, pp 413-5.
- Adachi A, Horikawa T. Paclitaxel-induced cutaneous lupus erythematosus in patients with serum anti-Ssa/Ro antibody. *J Dermatol* 2007;34:473-6.
- Henry A, Charpiat B, Perol M, et al. Paclitaxel hypersensitivity reactions : assessment of the utility of a test dose program. *Cancer J* 2006;12:237-45.
- Nebeker JR, Virmani R, Bennett CL, et al. Hypersensitivity cases associated with drug-eluting coronary stents: a review of available cases from the Research on Adverse Drug Events and Reports (RADAR) project. *J Am Coll Cardiol* 2006;47:175-81.
- Lee CW, Matulonis UA, Castells MC. Rapid inpatient / outpatient desensitization for chemotherapy hypersensitivity: standard protocol effective in 57 patients for 255 courses. *Gynecol Oncol* 2005;99:393-9.
- Sendo T, Sakai N, Itoh Y, et al. Incidence and risk factors for paclitaxel hypersensitivity during ovarian cancer chemotherapy. *Cancer Chemother Pharmacol* 2005;56:91-6.
- Hiraki A, Aoe K, Murakami T, et al. Stevens-Johnson syndrome induced by paclitaxel in a patient with squamous cell carcinoma of the lung: a case report. *Anticancer Res* 2004;24:1135-7.
- Kupfer I, Balguerie X, Curville P, et al. Scleroderma-like cutaneous lesions induced by paclitaxel: a case study. *J Am Acad Dermatol* 2003;48:279-81.
- Szebeni J, Muggia FM, Alving CR. Complement activation by cremophor EL as a possible contributor to hypersensitivity to paclitaxel: an in vitro study. *J Natl Cancer Inst* 1998;90:300-6.
- Meerum-Terwogt JM, Nuijen B, Ten Bokkel Huinink WW, et al. Alternative formulations of paclitaxel. *Cancer Treat Rev* 1997;23:87-95.

Pemetrexed

A structurally novel anti-folate agent approved for the treatment of malignant pleural mesothelioma and non-small-cell lung cancer.

I Incidence

Cutaneous toxicity: 14% (grade 3 to 4: 0.8-1.3%).

I Clinical manifestations

• **Cutaneous:** rash (frequent), pruritus, toxic epidermal necrolysis, radiation recall dermatitis, urticarial vasculitis, mucositis, stomatitis, alopecia.

I Management

Premedication with dexamethasone (rash).

References

Tummino C, Barlesi F, Tchouhadjian C, et al. Severe cutaneous toxicity after Pemetrexed as second line treatment for a refractory non small cell lung cancer (Article in French). *Rev Mal Resp* 2007;24:635-8.

Lopes G, Vincek V, Raez LE. Pemetrexed-associated urticarial vasculitis. *Lung Cancer* 2006;51:247-9.

Pentostatin

Pentostatin (2'-deoxycoformycin) is an antibiotic produced by culture broths of *Streptomyces antibioticus*. It is widely used as an antineoplastic agent (lymphoid malignancies, mycosis fungoides, chronic lymphocytic leukemia).

■ Incidence

0.5 to 1%.

■ Risk factors

Concomitant use of allopurinol.

■ Clinical manifestations

- **General:** anaphylactic shock, fever.
- **Cutaneous:** rash (maculopapular), pruritus, dryness of the skin, flushing, cutaneous infections (viral), purpura (with thrombocytopenia), stomatitis, oral ulcerations, photosensitivity, peripheral edema, facial edema. Others: acne, alopecia, vesiculo-bullous dermatitis, depigmentation, hypersudation
- **Respiratory:** cough, pulmonary infiltrates.
- **Hematological:** eosinophilia.

■ Diagnostic methods

Hypersensitivity vasculitis involving arteries and veins in the heart, spleen, cerebral cortex (seen at autopsy).

Recurrence of reactions with drug re-challenge.

■ Mechanisms

Concomitant administration of allopurinol to prevent hyperuricemia secondary to tumor lysis could enhance pentostatin toxicity.

Pentostatin is formulated using mannitol and sodium hydroxide.

■ Management

Avoidance of systematic use of allopurinol.

References

O'Dwyer PJ, King SA, Eisenhauer E, et al. Hypersensitivity reactions to deoxycoformycin. *Cancer Chemother Pharmacol* 1989;23:173-5.

Steinmetz JC, DeConti R, Ginsburg R. Hypersensitivity vasculitis associated with 2-deoxycoformycin and allopurinol therapy. *Am J Med* 1989;86:498-9.

Procarbazine

A cytostatic agent derived from methylhydralazine. Mainly used in the treatment of lymphoma and brain tumors.

I Incidence

Severe allergic reactions: 2%, severe toxic effects; 2%, life-threatening allergic reactions; 1% in Hodgkin's disease.

Much higher (25%) in patients with brain tumors.

I Risk factors

Brain tumors, especially when anticonvulsant therapy is used.

I Clinical manifestations

• **General:** fever.

• **Cutaneous:** pruritus, rash, urticaria, fixed drug eruption, toxic epidermal necrolysis, pigmentation. Others: stomatitis, alopecia.

• **Respiratory:** cough, dyspnea, acute pulmonary infiltrates, pleural effusion.

I Diagnostic methods

No *in vivo* or *in vitro* method is currently available for diagnosis other than re-challenge, which is hazardous due to life-threatening pneumonitis (published).

I Mechanisms

Classical complement pathway activation is possible.

Procarbazine oxidation to a reactive intermediate is enhanced by phenobarbital.

I Management

Avoidance.

Use non enzyme-inducing anticonvulsants.

Corticosteroids are useful in the management of respiratory manifestations.

References

Lehmann DF, Hurteau TE, Newman N, et al. Anticonvulsant usage is associated with an increased risk of procarbazine hypersensitivity reactions in patients with brain tumors. *Clin Pharmacol Ther* 1997;62:225-9.

Coyle T, Bushnow P, Winfield J, et al. Hypersensitivity reactions to procarbazine with mechlorethamine, vincristine, and procarbazine chemotherapy in the treatment of glioma. *Cancer* 1992;69:2532-40.

Brooks BJ Jr, Hendler MB, Alvarez S, et al. Delayed life-threatening pneumonitis secondary to procarbazine. *Am J Clin Oncol* 1990;13:244-6.

Glovsky MN, Braunwald J, Opelz G, et al. Hypersensitivity to procarbazine associated with angioedema, urticaria and low serum complement activity. *J Allergy Clin Immunol* 1976;57:134-40.

Raltitrexed

A thymine synthetase inhibitor used for first line treatment of metastatic colorectal cancer.

■ Incidence

Rare.

■ Clinical manifestations

- **Cutaneous:** pruritus, rash, pseudocellulitic skin reactions (in 2 patients occurring 5 and 7 days after onset of treatment).
- **Others:** diarrhoea, neutropenia, hepatotoxicity (risk factors: elevated baseline transaminase levels, number of chemotherapy cycles, raltitrexed cumulative dose and TOMOX regimens (raltitrexed + oxaliplatin)).

■ Diagnostic methods

None.

■ Mechanisms

Unknown.

■ Management

Avoidance.

Glutathione and ademethionine are hepatoprotective.

References

- Massacesi C, Santini D, Rocchi MB, et al. Raltitrexed-induced hepatotoxicity analysis of predictive factors. *Anticancer Drugs* 2003;14:533-41.
- Cunningham D, Zalberg J, Maroun J, et al. Efficacy, tolerability and management of raltitrexed (Tomudex) monotherapy in patients with advanced colorectal cancer. A review of phase II/III trials. *Eur J Cancer* 2002;38:478-86.
- Topard D, Hellier I, Ychou M, et al. Raltitrexed-induced skin reaction (Article in French). *Ann Dermatol Venereol* 2000;127:1080-2.

Human granulocyte colony-stimulating factor (rhG-CSF) and human granulocyte macrophage colony-stimulating factor (rhuGM-CSF)

rhG-CSF: filgrastim (non glycosylated form from *E. coli*)
lenograstim (glycosylated natural form from mammalian cells)
Used for mitigation of post-chemotherapy neutropenia.

rhuGM-CSF: sargramostim.
Used to accelerate myeloid recovery following bone marrow transplantation or cytotoxic chemotherapy.

■ Clinical manifestations

- **General:** anaphylactic shock, throat tightness.
- **Cutaneous:** maculopapular rash, vasculitis, Sweet's syndrome, psoriasiform dermatitis, injection-site reactions, linear IgA bullous dermatitis.

■ Diagnostic methods

Skin tests

Prick tests

Sargramostim: 100/250 µg/ml

Filgrastim: 300 µg/ml

Intradermal test

0.02 ml of the therapeutic concentration of filgrastim and lenograstim.

No specific IgE found

Lymphocyte stimulation test negative in 2 patients.

■ Mechanisms

IgE-mediated hypersensitivity in some cases.

Neutrophil accumulation (neutrophilic dermatosis).

■ Management

Avoidance.

Switch to another rhG-CSF (filgrastim/lenograstim if skin tests are negative).

Switch from rhuGM-CSF to rhG-CSF (sargramostim/filgrastim if skin tests are negative).

References

Hanna GG, Edgar F, Clarke JE. A case of prolonged type 1 hypersensitivity reaction to pegfilgrastim. *Clin Oncol* 2008;20:315-6.

White JM, Mufti GJ, Salisbury JR, et al. Cutaneous manifestations of granulocyte colony-stimulating factor. *Clin Exp Dermatol* 2006;31:206-7.

Alvarez-Ruiz S, Penas PF, Fernandez-Herrera J, et al. Maculopapular eruption with enlarged macrophages in eight patients receiving G-CSF or GM-CSF. *J Eur Acad Venereol* 2004;18:310-3.

Engler RJ, Weiss RB. Immediate hypersensitivity to human recombinant granulocyte-macrophage colony-stimulating factor associated with a positive prick skin test reaction. *Am Allergy Asthma Immunol* 1996;76:531-4.

Sasaki O, Yokoyama A, Uemura S, et al. Drug eruption caused by recombinant human G-CSF. *Intern Med* 1994;33:641-3.

Sirolimus

A macrocyclic lactone isolated from *S. hygroscopicus* with potent anti-fungal effect as well as immunosuppressive and proliferative effects. Used in renal graft reject prevention.

I Clinical manifestations

- **General:** anaphylactic shock, reports of systemic (serum sickness) and intrastent hypersensitivity reactions leading in some cases to late thrombosis and death with sirolimus-containing drug eluting coronary stent (CYPHER*).
- **Cutaneous:** acneiform eruption (20 to 30%), scalp folliculitis, hidradenitis suppurativa (frequent), edema (peripheral, facial frequent), rash (6 to 20%), angioedema (15%; association with angiotensin-converting enzyme inhibitors is a risk factor), oral ulcerations, gingival hypertrophy, aphthous stomatitis, gingivitis, fissure of the lips, vasculitis, purpura (with thrombocytopenia). Others: epis-taxis, carcinoma, cutaneous and mucosal infections (viral and mycotic), nail alterations (onychopa-thy and periungual infections).
- **Respiratory:** bronchospasm, hypersensitivity pneumonitis (CD4 – T cell infiltrates).

I Diagnostic methods

None.

I Mechanisms

Unknown.

I Management

Avoidance.

References

- Gupte GL, Mahadevan S, Clarke JR, et al. Sirolimus-related pulmonary toxicity mimicking 'asthma like' symptoms. *World J Gastroenterol* 2007;13:5151-3.
- Mahe E, Morelon E, Lechaton S, et al. Angioedema in renal transplant recipients on sirolimus. *Dermatology* 2007;214:205-9.
- Rana JS, Sheikh J. Serum sickness-like reactions after placement of sirolimus-eluting stents. *Ann Allergy Asthma Immunol* 2007;98:201-2.
- Howard L, Gopalan D, Griffiths M, et al. Sirolimus-induced pulmonary hypersensitivity associated with a CD4 T-cell infiltrate. *Chest* 2006;129:1718-21.
- Warino L, Libecco J. Cutaneous effects of sirolimus in renal transplant recipients. *J Drugs Dermatol* 2006;5:273-4.
- Kunzle N, Venetz JP, Pascual M, et al. Sirolimus-induced acneiform eruption. *Dermatology* 2005;211:366-8.
- Mahe E, Morelon E, Lechaton S, et al. Cutaneous adverse events in renal transplants recipients receiving siroli-mus-based therapy. *Transplantation* 2005;79:476-82.
- Wadei H, Gruber SA, El-Amm JM, et al. Sirolimus-induced angioedema. *Am J Transplant* 2004;4:1002-5.

Sorafenib and Sunitinib

Oral multikinase inhibitors with clinical activity against solid tumors (renal cell carcinoma).

■ Incidence

Hand-foot skin reaction: sorafenib 33.8% (24.5-44.7).

High grade hand-foot skin reaction: sorafenib 8.9% (3.7-11.7).

■ Risk factors

Renal cell carcinoma (RR: 1.52).

■ Clinical manifestations

• **Cutaneous:** rash/desquamation and hand-foot skin reaction are the most frequent adverse cutaneous effects.

Hand-foot syndrome (30 to 60% with sorafenib and 15 to 20% with sunitinib), preceded or accompanied by dysesthesias, arising 2 to 4 weeks after the initiation of treatment. Lesions are localized, symmetrical, painful, hyperkeratotic and in peripheral erythematous, edematous and sometimes bullous.

Subungual splinter hemorrhage: multiple, painless, more frequent with sorafenib (60% to 70%), than sunitinib (30%). Periorbital edema (5 to 10% with sunitinib), facial eruption (seborrheic dermatitis like, with periorbital aspect), 50% with sorafenib; 1 to 2 weeks after beginning treatment; may be associated to scalp erythema, scalp dysesthesia (sorafenib), frequent in the first three weeks; disappears spontaneously, flushing (sorafenib), bullous dermatitis (sunitinib), stomatitis (sorafenib, sunitinib), yellow skin discoloration (sunitinib), hair depigmentation (sunitinib), hair modification and alopecia (sorafenib), kystic, hyperkeratotic papules, keratoacanthoma (sorafenib).

Reference

Chu D, Lacouture ME, Fillos T, et al. Risk of hand-foot skin reaction with sorafenib: a systemic review and meta-analysis. *Acta Oncol* 2008;47:176-86.

Yang CH, Lin WC, Chuang CK, et al. Hand-foot skin reaction in patients treated with sorafenib: a clinicopathological study of cutaneous manifestations due to multitargeted kinase inhibitor therapy. *Br J Dermatol* 2008;158:592-6.

Suwattee P, Chow S, Berg BC. Sunitinib: a cause of bullous palmoplantar erythrodysesthesia, periungual erythema, and mucositis. *Arch Dermatol* 2008;144:123-5.

Autier J, Mateus C, Weschler J, et al. Cutaneous side effects of sorafenib and sunitinid (Article in French). *Ann Dermatol Venereol* 2008;135:148-53.

Tacrolimus

Calcineurin inhibitor used systematically to prevent liver or renal transplant rejection and locally to treat severe atopic dermatitis.

I Incidence

Pruritus / burning : 1.5 to 25% (topical use).

Systemic administration (transplantation): pruritus (7 to 36%), rash (10 to 24%), dyspnea (5 to 29%), cough (15 to 18%), pleural effusion (liver transplantation : 30 to 36%), atelectasis (5 to 25%), bronchitis (heart transplantation : 17 to 18%).

I Clinical manifestations

• **General:** anaphylactic shock.

• **Cutaneous:** irritant dermatitis, erythema, burning, paresthesia, rosaceiform eruption, demodicidosis, cutaneous infections (herpes - simplex virus), rash, peripheral edema, photosensitivity, Stevens-Johnson syndrome and epidermal toxic necrolysis (rare), alopecia or hirsutism (rare), gingival hypertrophy (low prevalence and severity).

• **Respiratory:** cough, dyspnea, pleural effusion, atelectasis, bronchitis, asthma (rare).

• **Others:** eosinophilic gastroenterocolitis (in children), asymptomatic eosinophilia and elevated total and specific IgE levels, angioedema related to drug allergy.

I Diagnostic methods

None.

I Mechanisms

Cremophor EL is the vehicle contained in IV tacrolimus preparation and could be responsible of reactions.

I Management

When possible, switch to non calcineurin inhibitor everolimus (mammalian target of rapamycin).

References

Schmutz JL, Barbaud A, Trechot P. Contact allergy with tacrolimus then pimecrolimus (Article in French). *Ann Dermatol Venerol* 2008;135(1):89.

Rustin MH, The safety of tacrolimus ointment for the treatment of atopic dermatitis: a review, *Br. J. Dermatol.* 2007;157(5):861-73

Saeed SA, Integlia MJ, Pleskow MG, et al, Tacrolimus-associated eosinophilic gastroenterocolitis in pediatric liver transplant recipients : role of potential food allergies in pathogenesis, *Pediatr. Transplant.* 2006;10(6):730-5

Shaw DW, Eichenfield LF, Shainhouse T, et al, Allergic contact dermatitis from tacrolimus, *J. Am. Acad. Dermatol.* 2004;50(6):962-5

Lykavieris P, Fraugel E, Habes D, et al, Angioedema in pediatric liver transplant recipients under tacrolimus immunosuppression: *Transplantation.* 2003;75(1):152-5

Fujisawa. *Prograf**. Package insert. Deerfield IL : april 1994.

Tegafur

Combination of tegafur and uracil contains tegafur as prodrug of 5 FU and uracil, which slows the breakdown of FU (higher tumoral concentration). Mainly used in the treatment of uterine carcinoma.

■ Clinical manifestations

- **Cutaneous:** palmo-plantar erythrodysesthesia; acral erythema, acral hyperpigmentation, Mucha-Habermann disease-like eruption, scleroderma-like reaction, discoid lupus erythematosus-like lesion, prurigo reaction, photosensitivity.
- **Others:** allergic liver injury.

■ Diagnostic methods

One case with a positive lymphocyte stimulation test and challenge test in allergic liver injury.

■ Mechanisms

Unknown.

■ Management

Avoidance.

References

Yoshimasu T, Horoi A, Uede K, et al. Discoid lupus erythematosus (DLE)-like lesion induced by uracil-tegafur (UFT). *Eur J Dermatol* 2001;11:54-7.

Kono T, Ishii M, Negoro N, et al. Scleroderma-like reaction induced by uracil-tegafur (UFT) a second generation anticancer agent. *J Am Acad Dermatol* 2000;42:519-20.

Baba M, Shima T, Tanaka T, et al. A case of allergic liver injury induced by tegafur. *J Gastroenterol* 1994;29:88-92.

Temozolomide

An oral alkylating agent used in the treatment of metastatic melanoma.

■ Clinical manifestations

- **General:** fever.

- **Cutaneous:** rash, dryness of the skin, pruritus, peripheral edema, photosensitivity, pigmentation (with concomitant radiotherapy), hand-foot syndrome, alopecia.

■ Diagnostic methods

None.

■ Mechanisms

Unknown.

■ Management

Topical and systemic corticosteroids.

References

Pick AM, Neff WJ, Nystrom KK. Temozolomide-induced desquamative skin rash in a patient with metastatic melanoma. *Pharmacotherapy* 2008;28:406-9.

Karnat O, Baskan BE, Kurt E, et al. Successful treatment of palmo-plantar erythrodysesthesia possibly due to temozolomide with dexamethasone. *J Postgrad Med* 2007;53:146.

Teniposide

Semisynthetic derivative of podophyllotoxin which interacts with type II topoisomerase to induce DNA cross-links and double-strand breaks.

■ Incidence

2 to 11%.

41% of children with acute lymphoblastic leukemia treated with intensive multiagent chemotherapy.

■ Risk factors

Children with neuroblastoma or brain tumors.

High doses (children): 1500 to 2000 mg/m².

■ Clinical manifestations

(often on the first or second dose)

- **General:** hypotension, oliguria, intravascular hemolysis, sweating, pallor, fever.
- **Cutaneous:** rash, urticaria, facial edema.
- **Respiratory:** chest pain, wheezing.

■ Diagnostic methods

Non-specific histamine release.

One case with IgG1 antibody to teniposide.

■ Mechanisms

Cremophor EL is thought to be the culprit (see cremophor EL).

■ Management

Premedication with diphenhydramine corticosteroids is useful.

Etoposide does not usually cross-react.

References

Hudson MM, Weinstein HJ, Donaldson SS, et al. Acute hypersensitivity reactions to etoposide in a VEPA regimen for Hodgkin's disease. *J Clin Oncol* 1993;11:1080-4.

Kellie SJ, Crist WM, Pui CH, et al. Hypersensitivity reactions to epipodophyllotoxins in children with acute lymphoblastic leukaemia. *Cancer* 1991;67:1070-5.

Siddall SJ, Martin J, Nunn AJ. Anaphylactic reactions to teniposide. *Lancet* 1989;1(8634):394.

Nolte H, Carstensen H, Hertz H. VM-26 (teniposide)-induced hypersensitivity and degranulation of basophils in children. *Am J Pediatr Hematol Oncol* 1988;10:308-12.

O'Dwyer PJ, King SA, Fortner CL, et al. Hypersensitivity reactions to teniposide (VM-26): an analysis. *J Clin Oncol* 1986;4:1262-9.

Thiotepa

Alkylating agent acting upon synthesis of desoxyribo-nucleoproteins. Used in the treatment of ovarian, breast cancer and bladder tumors (intravesical instillation).

■ Incidence

3% of intravesical infusions.

■ Risk factors

Bladder instillation.

■ Clinical manifestations

- **General:** fever.
- **Cutaneous:** pruritus, rash, urticaria, angioedema, injection-site pain, alopecia, pigmentation.

■ Diagnostic methods

No *in vivo* or *in vitro* method is currently available for diagnosis.

■ Management

Avoid use.

References

Lee M, Sharifi R. Generalized hypersensitivity reaction to intravesical thiotepa and doxorubicin. *J Urol* 1987;138:143–4.

Hu K.N, Kim A, Khan AS, et al. Combined thiotepa and mitomycin C instillation therapy for low-grade superficial bladder tumor. *Cancer* 1985; 55:1654-8.

Topotecan

Topoisomerase-1 inhibitor used in the treatment of recurrent ovarian cancer.

■ Clinical manifestations

- **Cutaneous:** pruritus (frequent), alopecia (frequent), maculopapular rash, stomatitis, cellulitis-like fixed drug eruption (rare), neutrophilic eccrine hidradenitis.
- **Respiratory:** BOOP, diffuse alveolar damage.

■ Diagnostic methods

None.

■ Mechanisms

Unknown.

■ Management

Avoidance.

References

Denschlag D, Watermann D, Hörig K, et al. Topotecan as a continuous infusion over 14 days in recurrent ovarian cancer patients. *Anticancer Res* 2004;24:1267-9.

Senturk N, Yanik F, Yildiz L, et al. Topotecan-induced cellulitis-like fixed drug eruption. *Eur Acad Dermatol Venereol* 2002;16:414-6.

Vinblastine - Vincristine - Vindesine - Vinorelbine

Plant alkaloids frequently used in current chemotherapy protocols the last one; vinorelbine is used in the treatment of non-small-cell lung carcinoma and metastatic breast cancer.

I Incidence

Exceptional for anaphylaxis.
More common for bronchospasm.
Deaths reported.

I Risk factors

Associated treatment with mitomycin (respiratory manifestations).

I Clinical manifestations

- **General:** anaphylactic shock (vincristine, vinorelbine), fever (vincristine).
- **Cutaneous:** rash (5 to 10%); hand-foot syndrome (with vinorelbine and most often with high doses regimens), Raynaud's phenomenon (vinblastine +++), localized epidermal necrolysis, local reactions: skin necrosis after extravasation, phlebitis, cellulitis, stomatitis, nails lesions and alopecia.
- **Respiratory:** acute respiratory failure (vinblastine), bronchospasm, pleural effusion, lung nodules (vinblastine), subacute cellular interstitial pneumonitis (vindesine), acute pulmonary edema (vinorelbine).

I Diagnostic methods

One case of positive leukocyte migration test to vincristine.
Pulmonary function tests show obstructive patterns in some patients.

I Mechanisms

Undetermined.

I Management

Avoidance.

Premedication with corticosteroids may be useful.

References

- Imai C, Uno K, Kakihara T, et al. Vincristine-induced fever in a child with rhabdomyosarcoma: cellular hypersensitivity to vincristine demonstrated by leukocyte migration test. *J Pediatr Hematol Oncol* 2001;23:73-4.
- Laack E, Mende T, Knuffmann C, et al. Hand-foot syndrome associated with short infusions of combination chemotherapy with gemcitabine and vinorelbine. *Ann Oncol* 2001;12:1761-3.
- Rivera MP, Kris MG, Gralla RJ, et al. Incidence and syndrome of acute shortness of breath following vinca alkaloids in patients receiving mitomycin. *Proc Ann Meet Am Soc Clin Oncol* 1990; 9:A1246.
- Ballen KK, Weiss ST. Fatal acute respiratory failure following vinblastine and mitomycin administration for breast cancer. *Am J Med Sci* 1988;295:558-60.
- Dyke RW. Acute bronchospasm after vinca alkaloids in patients previously treated with mitomycin. *New Eng J Med* 1984; 310:389.

V

DRUGS USED IN CARDIOLOGY AND VASCULAR DISORDERS

Angiotensin converting enzyme (ACE) inhibitors

Drugs widely used in the management of hypertension and congestive heart failure: benazepril, captopril, cilazapril, enalapril, fosinopril, imidapril, lisinopril, moexipril, perindopril, quinapril, ramipril, trandolapril, zofenopril.

■ Incidence

Cough in 1 to 20% (mean 15%).

Rash: 1.3 to 6%.

Angioedema: 1 to 7/1,000 (enalapril 0.68%).

■ Risk factors

Women, Black Americans, Hong-Kong Chinese (cough).

Idiopathic angioedema (angioedema).

■ Clinical manifestations

• **Cutaneous:** pruritus, urticaria, angioedema involving lips, face neck, tongue, eyelids, pharynx, larynx, sometimes visceral (stomach, intestine); occurring after the first dose or within the first weeks of treatment; asphyxic deaths have been reported. Maculopapular rash, occurring within the first weeks of treatment, often transitory, rarely a cause of discontinuation of treatment; pityriasis-rosea like rash, toxic erythema, exfoliative dermatitis, purpuric rash.

Others: erythroderma, linear IgA bullous disease, erythema multiforme, Stevens-Johnson syndrome, toxic epidermal necrolysis (rare), lichen planus eruption (sometimes with photosensitive distribution), lichen planus pemphigoides, psoriasis (induction, exacerbation), palmo plantaris pustulosis, lupus erythematosus, photosensitive eruption, pemphigus, bullous pemphigoid, lymphomatoid drug eruption, vasculitis, Henoch-Schonlein purpura

• **Respiratory:** dry, non-productive tickling cough. Worse in supine position and at night. Pre-existing cough may be exacerbated. Average time of onset: one week, disappearing 3-6 days after withdrawal. Hypersensitivity pneumonitis.

■ Diagnostic methods

Skin tests (anaphylactic or cutaneous reactions)

Intradermal: 0.05 ml of pure captopril. Check results after 15 minutes. Positive in 60% of patients with cutaneous manifestations.

Patch tests: 1%, 5%, 10% in pet (standardized captopril 5% in pet in France). Check results after 48 and 72 hours.

Skin biopsy: vasculitis with leukocyte infiltration in patients with cutaneous lesions.

Respiratory function tests: bronchial hyperresponsiveness to histamine or metacholine is sometimes found in patients who develop cough with ACE inhibitors.

Challenge test.

I Mechanisms

Cough.

Captopril increases plasma levels of prostaglandins. PGE directly stimulates unmyelinated afferent vagal C fibers, the initial chemical mediator of the cough reflex in the lung.

Accumulation of bradykinin which stimulates the release of tachykinins including substance P and neurokinin A.

Tachykinin stimulates the C fibers whose activation causes cough.

Thromboxane A₂ is implicated in ACE induced cough.

The mechanism of ACE inhibitor-induced coughing may involve substance P-mediated airway priming but the final triggering of the ACE inhibitor-induced cough is unlikely to be due to this peptide.

Substance P is metabolized by ACE in tissues, and ACE inhibitors have previously been shown to decrease its metabolism. Substance P is important in neurogenic inflammation and has a functional relationship via C fibers with mast cells in various tissues, including lung and skin.

Pulmonary accumulation of bradykinin may be a mediator of ACE inhibitor-induced coughing.

Bradykinin is known to activate afferent sensory C fibers via type J receptors which cause coughing. Conversely, bradykinin could increase the formation of prostaglandins and leukotrienes.

Angioedema.

Inhibition of ACE and/or related enzymes in the kinin-kallikrein system blocks bradykinin metabolism. In addition, a decrease in bradykinin degradation increases the synthesis of bradykinin and/or related kinins.

Increase of plasma fibrinogen level, vasodilatory activity in human intrathoracic artery and potentiation of bradykinin-induced vasodilatation suggest that fibrinogen might contribute to the pathophysiology of ACE induced angioedema.

I Management

Switch to another antihypertensive treatment.

References

Bas M, Kirchhartz N, Hochefeld J, et al. Potential role of vasomotor effects of fibrinogen in bradykinin-induced angioedema. *J Allergy Clin Immunol* 2008;121:969-75.

Karagiannis A, Tziomalos K, Athyros VG. Is angioedema a class effect of the angiotensin-converting enzyme inhibitors? *Ann Allergy Asthma Immunol* 2007;98:502.

Malde B, Regalado J, Greenberger PA. Investigation of angioedema associated with the use of angiotensin-conver-

ting enzyme inhibitors and angiotensin receptor blockers. *Ann Allergy Asthma Immunol* 2007;98:57-63.

Nikpoor B, Duan OL, Rouleau GA. Acute adverse reactions associated with angiotensin-converting enzyme inhibitors: genetic factors and therapeutic implications. *Expert Opin Pharmacother* 2005;6:1851-6.

Kostis JB, Kim HJ, Rusnak J, et al. Incidence and characteristics of angioedema associated with enalapril. *Arch Intern Med* 2005;165:1637-42.

Sicardi M, Zingale LC, Bergamaschini L, et al. Angioedema associated with angiotensin-converting enzyme inhibitor use: outcome after switching to a different treatment. *Arch Intern Med* 2004;164:910-3.

Gaiag P, San Miguel-Moncin MM, Bartra J, et al. Usefulness of patch tests for diagnosing selective allergy to captopril. *J Investig Allergol Clin Immunol* 2001;11:204-6.

Bircher AJ. Drug-induced urticaria-angioedema (Article in French). *Gerda* 1999. John Libbey Eurotext, pp 289-301.

Alteplase

A recombinant tissue plasminogen activator (rt-PA) used intravenously for systemic thrombolysis (acute stroke, myocardial infarction).

■ Incidence

1.9% (acute stroke).

0.02% (myocardial infarction).

Deaths reported.

■ Risk factors

ACE inhibitor use (OR:13,6 to 37).

Acute stroke.

■ Clinical manifestations

• **General:** hypotension, tachycardia.

• **Cutaneous:** urticaria, orolingual angioedema (sometimes asymmetric), rash, purpura.

■ Diagnostic methods

Specific IgE: one case (ELISA).

■ Mechanisms

IgE-mediated hypersensitivity in some cases.

Direct complement activation.

Plasmin-mediated release of bradykinin (angioedema).

■ Management

Avoidance.

References

Engelter ST, Fluri F, Buitrago-Tellez C, et al. Life-threatening orolingual angioedema during thrombolysis in acute ischemic stroke. *J Neurol* 2005;252:1167-70.

Hill MD, Lye T, Moss H, et al. Hemi-orolingual angioedema and ACE inhibition after alteplase treatment of stroke. *Neurology* 2003;60:1525-7.

Molinario G, Gervais N, Adam A. Biochemical basis of angioedema associated with recombinant tissue plasminogen activator treatment: an in vitro experimental approach. *Stroke* 2002;33:1712-6.

Amiodarone

A Class III antiarrhythmic agent frequently used in the management of ventricular and supraventricular arrhythmias (iodine content is 75 mg in a 200 mg amiodarone tablet).

■ Incidence

Photosensitivity is frequent.

■ Clinical manifestations

• **General:** anaphylactic shock.

• **Cutaneous:** photosensitivity (sometimes severe and persistent) and pigmentation (frequently +++; blue-grey pigmentation on sun-exposed skin due to storage and deposits of amiodarone), pruritus, urticaria, angioedema (rare), vasculitis (lymphocytic, leukocytoclastic), thrombophlebitis (complication with peripheral amiodarone infusion), lupus erythematosus, linear IgA disease, pseudoporphyria, iododerma, toxic epidermal necrolysis (rare), skin necrosis.

• **Respiratory:** asthma (infrequent), hypersensitivity pneumonitis (2-17% of patients).

• **Others:** steatosis/steatohepatitis (high aminotransferase and alkaline phosphate levels) in 4-25% of patients, thrombocytopenia.

■ Diagnostic methods

Skin tests

Positive in one patient with anaphylaxis.

Tryptase levels.

Elevated at the time of reaction.

■ Mechanisms

Pulmonary toxicity: direct toxicity or indirect/ inflammatory/ or immune process.

■ Management

Discontinuation of the drug.

References

Ammoury A, Michaud S, Paul C, et al. Photodistribution of blue-gray hyperpigmentation after amiodarone treatment: molecular characterization of amiodarone in the skin. *Arch Dermatol* 2008;144:92-6.

Slim AM, Roth JE, Duffy B, et al. The incidence of phlebitis with intravenous amiodarone at guideline dose recommendations. *Mil Med* 2007;172:1279-83.

Yones SS, O'Donoghue NB, Palmer RA, et al. Persistent severe amiodarone-induced photosensitivity. *Clin Exp Dermatol* 2005;30:500-2.

Fransi S, Briedis J. Anaphylaxis to intravenous amiodarone. *Anaesth Intensive Care* 2004;32:578-9.

Yung A, Agnew K, Snow J, et al. Two unusual cases of toxic epidermal necrolysis. *Australas J Dermatol* 2002;43:35-8.

Burches E, Garcia-Verdegay F, Ferrer M, et al. Amiodarone-induced angioedema. *Allergy* 2000;55:1199-200.

Dootson G, Byatt C. Amiodarone-induced vasculitis and a review of the cutaneous side effects of amiodarone. *Clin Exp Dermatol* 1994;19:422-4.

ANTICOAGULANTS

Clopidogrel

A selective irreversible inhibitor of adenosine diphosphate (ADP)-induced platelet aggregation for oral use.

The combination of clopidogrel and aspirin is considered essential in reducing the risk of stent thrombosis in patients undergoing coronary stenting.

■ Incidence

Low.

■ Clinical manifestations

- **General:** severe hypersensitivity syndrome (fever, neutropenia, pancytopenia).
- **Cutaneous:** pruritus, rash, urticaria, angioedema, purpura, pustular psoriasis eruption, lichenoid eruption (with photosensitivity): rare.

■ Diagnostic methods

Skin tests

Prick-tests: 7.5 mg/ml (1/10).

Intradermal tests: 7.5 mg/ml (1/10).

Oral challenge tests.

12.5 mg, 18.75 mg, 37.5 mg at 30 minute intervals.

■ Mechanisms

IgE-mediated hypersensitivity in some cases.

■ Management

Switch to ticlopidine but serious side effects may occur (diarrhea, neutropenia, thrombocytopenic purpura); cross-reactivity has been documented rarely between these two thienopyridines.

Switch to cilostazol (bare metal stents).

Desensitization.

Different protocols have been published: for example, from 0.005 mg to 75 mg in 7 hours.

References

- Oppedijk B, Odekerken DA, van der Wildt JJ, et al. Rapid oral desensitisation procedure in clopidogrel hypersensitivity. *Neth Heart J* 2008;16:21-3.
- Owen P, Garner J, Hergott L, et al. Clopidogrel desensitization: case report and review of published protocols. *Pharmacotherapy* 2008;28:259-70.
- von Tiehl KF, Price MJ, Valencia R, et al. Clopidogrel desensitization after drug-eluting stent placement. *J Am Coll Cardiol* 2007;50:2039-43.
- Gutierrez-Fernandez D, Fuentes-Vallejo MS, Rueda-Ygueravides MD, et al. Immediate hypersensitivity and delayed hypersensitivity to clopidogrel. *Allergol Immunopathol* 2007;35:213-5.
- Camara MG, Almeda FQ. Clopidogrel (Plavix*) desensitization: a case series. *Catheter Cardiovasc Interv* 2005;65:525-7.
- Comert A, Akgun S, Civelek A, et al. Clopidogrel-induced hypersensitivity syndrome associated with febrile pancytopenia. *Int J Dermatol* 1995;44:882-4.

Coumarin derivatives: warfarin, phenprocoumon, acenocoumarol

The drugs are the therapeutic of choice for maintenance anticoagulation therapy.

■ Incidence

Skin necrosis: prevalence of 0.01-0.1%.

Maculopapular exanthemas are very rare.

Urticaria, bullous lesions are exceptional.

■ Risk factors

Skin necrosis: Obese women older than 50 years-old. Patients with primary proteins C and S deficiency or those with anticardiolipin syndrome are at greater risk for developing necrosis.

■ Clinical manifestations

• Cutaneous reactions:

Rash (maculopapular, vesicular, urticarial), pruritus, urticaria, angioedema (rare)

Cutaneous necrosis (frequent when deficient in proteins C and S, factor V Leiden)

Purple digit syndrome (fingers and toes, pain, burning sensation, discoloration, gangrene, ulceration; occur early after the onset of treatment; persistent for months after interruption of treatment)

Cutaneous symptoms of bleeding: purpura, ecchymoses, haemorrhagic necrosis

Vasculitis (with leucocytoclastic phenomenon)

Alopecia (frequent)

■ Diagnosis methods

Proteins C and S determination in case of cutaneous necrosis. Skin tests and re-exposure contraindicated

Skin tests: not available

Specific IgE assay: assay not available

I Mechanism

In the pathogenesis of cutaneous necrosis, recent hypotheses favour the combined role of local factors and a transient imbalance of coagulation mechanisms leading to a hypercoagulable state. A genetic factor is responsible for decreased levels of proteins C and S.

I Management

Replacement therapy with recombinant protein C concentrate appears to block progression of the lesion and enhances healing.

Alternatively, longer overlapping periods with heparins during initiation of coumarin administration ensure a complication and necrosis-free treatment.

References

Kurt M, Shorbagi A, Aksu S, et al. Warfarin-induced skin necrosis and leucocytoclastic vasculitis in a patient with acquired protein C and protein S deficiency. *Blood Coagul Fibrinolysis*. 2007;18:805-6.

Bircher AJ, Harr T, Hohenstein L, et al. Hypersensitivity reactions to anticoagulant drugs: diagnosis and management options. *Allergy* 2006;61:1432-40.

Egred M, Rodrigues E. Purple digit syndrome and warfarin-induced necrosis. *Eur J Intern Med* 2005;16:294-5.

Srinivasan AF, Rice L, Bartholomew JR, et al. Warfarin-induced skin necrosis and venous limb gangrene in the setting of heparin-induced thrombopenia. *Arch Intern Med* 2004;164:66-70.

Valdivielso M, Longo I, Lecona M, et al. Cutaneous necrosis induced by acenocoumarol. *J Eur Acad Dermatol Venereol* 2004;18:211-5.

Fluindione

Fluindione is an oral anti-vitamin K anticoagulant. Contrary to phenindione, which is also an indanedione derivative, very few cases of immunologic reactions have been described.

I Clinical manifestations

• Cutaneous reactions:

Pruritus, macular or maculopapular rash (but rash may be the first manifestation of DRESS syndrome)

Vasculitis, cutaneous necrosis (when deficiency in proteins C and S)

Acute generalized exanthematous pustulosis

DRESS syndrome, sometimes with UVB photoaggravation

Alopecia

• Others: interstitial nephritis

I Diagnostic methods

Skin tests: patch tests with fluindione (5% and 30% in pet), doubtful in aq for some investigations. Photopatch tests (with various concentrations: 1%, 5% in aq and pet and with UVB irradiation)

Specific IgE assay: assay not available.

References

Chtoui M, Cousin-Testard F, Zimmermann U, et al. Fluindione-induced acute generalised exanthematous pustulosis confirmed by patch testing (Article in French). *Ann Dermatol Venereol* 2008;135:295-8.

Grimaldi D, Daugas E, Mougenot B, et al. Immuno-allergic interstitial nephritis related to fluindione: first biopsy proven cases. *Nephrol Dial Transplant* 2006;21:237.

Frouin E, Roth B, Grange A, et al. Hypersensitivity to fluindione (Previscan). Positive skin patch tests (Article in French). *Ann Dermatol Venereol* 2005;132:1000-2.

Thurot C, Reymond JL, Bourrain JL, et al. Fluindione-induced acute exanthematous pustulosis with renal involvement (Article in French). *Ann Dermatol Venereol* 2003;130:1146-9.

Heparin

Heparins are important anticoagulants, used in the prophylaxis and treatment of thromboembolic disorders. Chemically, they are sulfated carbohydrates of different molecular weights. This group includes a vast spectrum of agents going from unfractionated heparin (UFH; heparin calcium, heparin sodium), low-molecular weight heparins (LMWH; dalteparine sodium, nadroparine calcium, certoparin sodium, tinzaparine sodium, enoxaparine sodium, reviparine), synthetic heparinoids (danaparoid sodium) to synthetic pentasaccharides (fondaparinux sodium).

I- Unfractionated Heparin (UFH) and low-molecular weight heparins (LMWHs)

I Incidence

0.2% for all reactions included; probably under estimated.

Heparin-induced thrombocytopenia I: 20% of patients receiving UFH

Heparin-induced thrombocytopenia II: 3% of patients receiving UFH. Lower risk during treatment with LMWH (1%) as well in pediatric patients. High morbidity and mortality.

Skin-necrosis: uncommon.

Anaphylaxis is relatively rare.

I Risk Factors

Delayed allergic skin reactions: Female gender, obesity, and repetitive or long-lasting treatment.

Hormonal factors, longer persistence of heparins in subcutaneous adipose tissue or a relationship to the lipase activity of heparins have been proposed to explain the gender difference.

I Clinical manifestations

I Heparin-induced thrombocytopenia (HIT).

- **Type I:** moderate and transient decline in platelet count, occurring 2 to 4 days after heparin administration (platelet sequestration?).
- **Type II:** Platelet count $<100,000/\text{mm}^3$ or a 50% decrease from baseline values, occurring 6-10 days after initiation of heparin therapy in the absence of other etiology. Insufficient to cause bleeding symptoms.
- **Type II, severe:** Platelet count $< 50,000$ platelets/ mm^3 , developing 6 to 12 days after start of heparin therapy. Often complicated by disseminated thrombosis of vessels in the skin and in other organs. Clinically hemorrhagic, sometimes bullous lesions and plaques with rapid evolution toward necrosis are present.

II Immediate hypersensitivity reactions.

- Anaphylactic shock
- Bronchospasm
- Urticaria, pruritus (palmoplantar pruritus possibly represents an early sign of immediate type hypersensitivity)
- Rhinitis, conjunctivitis

III Skin necrosis.

After a sensitization or induction period of at least 7-10 days, but more often after weeks to months, patients develop pruritic erythematous lesions at the injection sites. These are sometimes followed by formation of vesicles and bullae. Pruritus may be severe and hemorrhage can occur due to the anticoagulant action of the drug. The main differential diagnosis is the cutaneous manifestation of the initial phase of HIT II

IV Delayed allergic skin-reactions.

UFH:

Localized reactions, sometimes followed by a generalized eruption

LMWH:

Local reaction: erythema, papules, pruritus

Generalized maculopapular rash

The same patient may developed type I and type IV reactions.

Injection-site reaction (pain, plaques, erythema, hematoma, nodules, induration, ecchymoses; sometimes severe skin necrosis with fatal outcome)

DRESS, Lyell syndrome, Baboon Syndrome (exceptional)

V Eosinophilia

Isolated reactive peripheral hyper eosinophilia after subcutaneous heparin application has been reported.

I Diagnostic methods

I- HIT

Heparin-induced platelet aggregation test: low sensitivity

Serotonin release test

Heparin-induced platelet activation test (HIPA)

Detection of PF4-specific antibodies

Histology may help to differentiate cell-mediated plaques from skin necrosis. Skin tests are contraindicated because they may exacerbate thrombocytopenia.

II- Immediate reactions

Skin tests:

Prick tests: undiluted commercial heparin

Intradermal skin tests: starting at a 1:1000 dilution up to a 1:10 dilution. Undiluted intradermal heparin causes irritant reaction

Sometimes positive in immediate cutaneous reactions (urticaria).

Tested compounds should include UFHs, LMWH, danaparoid, pentasaccharide, fondaparinux, and hirudins. Preservatives (chlorocresol, sulfites...) should be tested if they are present in the trade products.

One case with immediate hypersensitivity to dalteparine, positive skin tests to dalteparine and other LMWH preparations. UFH, fondaparinux, lepirudin were skin test-negative and tolerated upon re-exposure.

III Delayed reactions

Skin tests:

Prick tests: undiluted commercial heparin

Intradermal skin tests: 1:10 dilution or undiluted

Late reading: 20-30 min and at 24, 48, 72 or 96 h or even later as very late reaction may be observed.

Patch tests:

- pure and 10 % in aq with application at 48 h (reading at 48 h, 96 h and Day 7);
- pure, with 24 h application and readings at 24h , 48h and 72h

Enoxoparin: pure

Heparin derivatives: non-specific results due to sensitization to excipients (benzyl alcohol)

Patch tests are less sensitive.

Skin biopsies:

Presence of a dense lympho-histiocytic infiltrate with spongiosis of the epidermis, representing a contact dermatitis-type reaction. Immune histochemistry reveals predominant CD4- and a few CD8-positive T-cells, indicating a cell-mediated hypersensitivity reaction.

IV Others tests

In vitro tests:

- TTL: rarely positive in patients with plaque reactions
- Sulfidoleukotriene release test detecting immediate hypersensitivity does not give reproducible results and has low sensitivity.

Challenge test:

Performed with increasing doses up to one daily defined dose and should be followed from day 1 up to day 5-7, as a positive reaction may occur only after several days.

Two examples: 1) one dose of 0.1ml of undiluted heparin subcutaneous, reading at 96h, then 0.3ml per day during 3 days; 2) one single dose of 0.30 or 0.40 ml subcutaneous

Intravenous provocation tests may also be necessary to prove tolerance in emergency situations.

I Mechanisms

Heparin may cause all types of allergic reactions:

- **Type I immediate hypersensitivity reactions occur very rarely:** urticaria. These reactions were attributed to preservatives and contaminants such as proteins of animal origin. Presence of IgEs against heparin seems to be very rare.
- **Antibody-mediated type II reactions (IgG):** thrombocytopenia. Almost all individuals with HIT II have antibodies to heparin-platelet factor 4 (PF4) complexes in their plasma at the time the disease develops.
- **Cell-mediated type IV reactions:** erythematous plaques, sometimes maculopapular exanthemas.

Heparin is a sulfated proteoglycan (mucopolysaccharide) with strong protein-binding capacity because of its highly negative charge.

Its action can also be inhibited by protamine, a derivative of salmon sperm.

In allergic reaction, this negative charge seems to play an important pathogenic role, as the heparin molecule adheres to human proteins.

However, the allergenic epitopes causing the different hypersensitivity reactions are still unknown.

I Management

Cross-reactivity between UFHs and the different LMWHs and heparinoids has been observed

HIT II

Immediate discontinuation of heparin.

Cross reactivity among the heparins.

Huridins, danaparoid and fondaparinux can be used as valid alternatives.

Use warfarin or coumadin therapy.

Vena cava filters are sometimes useful (pulmonary embolism).

Cell-mediated reactions

UFH and LMWH cross-reactivity may be extensive. Danaparoid and pentosanpolysulfate, both low-sulfated mucopolysaccharides, may show cross-reactivity to some extent.

In one study, 81% of patients with delayed heparin allergy showed cross-reactivity to danaparoid and 45% showed cross-reactivity to pentosanpolysulfate.

Recently, several cases with erythematous plaques to heparins and also fondaparinux were reported.

Patients with cell-mediated delayed hypersensitivity to LMWH may tolerate UFH or the same product intravenously. This tolerance may be due to the failure of a particular protein to form an allergen, different antigen-presenting cells or a “compartment” effect because of T-cell homing.

In a life-threatening emergency situation, such patients could receive UFH intravenously.

Heparin allergy.

Immediate discontinuation of heparin.

Use low molecular weight heparin or heparinoids (beware of cross-reactivity)

Use hirudin.

Desensitization is possible, with two possible routes, IV and SC:

Intravenous desensitization:

Day1: 100 IU/1000 ml saline/24 hours.

Day2: 1000 IU/1000 ml saline/24 hours.

Day3: 5000 IU/1000 ml saline/24 hours.
Then 5000 IU subcutaneously twice daily until surgery.

Subcutaneous and intravenous desensitization:

Day1: 50 IU SC

After 40 minutes: 250 IU SC

After 40 minutes: 500 IU SC

Day2: 500 IU SC

After 40 minutes: 1500 IU SC

After 40 minutes: 3000 IU SC

Day3: 500 IU IV

After 40 minutes: 1500 IU I.V

After 40 minutes: 3000 IU IV

Day4: 5000 IU IV

References

- Singh S, Verma M, Bahekar A, et al. Enoxaparin-induced skin necrosis: a fatal outcome. *Am J Ther* 2007;14:408-10.
- Bircher AJ, Harr T, Hohenstein L, et al. Hypersensitivity reactions to anticoagulant drugs: diagnosis and management options. *Allergy* 2006;61:1432-40.
- White JM, Munn SE, Seet JE, et al. Eczema-like plaques secondary to enoxaparin. *Contact Dermatitis* 2006;54:18-20.
- Gaigl Z, Pfeuffer P, Raith P, et al. Tolerance to intravenous heparin in patients with delayed-type hypersensitivity to heparins: a prospective study. *Br J Haematol* 2005;128:389-92.
- Berkun Y, Haviv YS, Schwartz LB, et al. Heparin-induced recurrent anaphylaxis. *Clin Exp Allergy* 2004;34:1916-18.
- Hohenstein E, Tsakiris D, Bircher AJ. Delayed-type hypersensitivity to the ultra-low-molecular weight heparin fondaparinux. *Contact Dermatitis* 2004;51:149-51.
- Hallai N, Hughes M, Stone N. Type I and type IV allergy to unfractionated heparin and low molecular weight heparin with no reaction to recombinant hirudin. *Contact Dermatitis* 2004;51:153-4.
- Koch P. Delayed-type hypersensitivity skin reactions due to heparins and heparinoids. Tolerance of recombinant hirudins and of the new synthetic anticoagulant fondaparinux. *Contact Dermatitis* 2003;49:276-80.
- MacLaughlin EJ, Fitzpatrick KT, Sbar E, et al. Anaphylactoid reaction to enoxaparin in a patient with deep venous thrombosis. *Pharmacotherapy* 2002;22:1511-15.
- Koch P, Munssinger T, Rupp-John C, et al. Delayed-type hypersensitivity skin reactions caused by subcutaneous unfractionated and low-molecular-weight heparins: tolerance of a new recombinant hirudin. *J Am Acad Dermatol* 2000;42:612-19.
- al-Eryani AY, al-Momen AK, Fayed DF, et al. Successful heparin desensitization after heparin-induced anaphylactic shock. *Thromb Res* 1995;79:523-6.
- Patriarca G, Rossi M, Schiavino D, et al. Rush desensitization in heparin hypersensitivity: a case report. *Allergy* 1994;49:292-4.

II- Heparinoids (danaparoid sodium)

I Clinical manifestations

• *Cutaneous reactions:*

Pruritus, rash

Injection site reactions

Delayed skin reactions at the injection site

I Diagnosis methods

Skin tests

Prick tests: undiluted commercial drug

Intradermal skin tests: starting at a 1:1000 dilution up to a 1:10 dilution

Patch tests:

- pure and 10 % in aq with application at 48 h (readings at 48 h , 96 h and Day 7);
- pure with application at 24 h and readings 24 h, 48 h and 72 h.

References

Figarella I, Barbaud A, Lecompte T, et al. Delayed cutaneous hypersensitivity reactions with polysensitivity to heparins and heparinoids (Article in French). *Ann Dermatol Vénéréol* 2001;128:25-30.

Szolar-Platzer C, Aberer W, Kranke B. Delayed-type skin reaction to the heparin-alternative danaparoid. *J Am Acad Dermatol* 2000;43:920-2.

Koch P, Munssinger T, Rupp-John C, et al. Delayed-type hypersensitivity skin reactions caused by subcutaneous unfractionated and low-molecular-weight heparins: tolerance of a new recombinant hirudin. *J Am Acad Dermatol* 2000;42:612-19.

III- Pentasaccharides (fondaparinux sodium)

Fondaparinux is a new anticoagulant drug with anti-factor-Xa properties. It is a pentasaccharide mimicking the site where heparin binds to anti-thrombin III. It is used in prophylaxis of venous thrombosis after orthopaedic surgery.

Fondaparinux is an alternative therapy in patients with heparin-induced delayed-type hypersensitivity skin lesions, in cases of heparin intolerance during pregnancy

I Clinical manifestations

• *Cutaneous reactions:*

Pruritus, rash (rare)

Injection site reactions (pain, bleeding, pruritus)

Delayed-type hypersensitivity reactions at the injection site, with possible disseminated reaction

I Diagnostic methods

Skin tests

Prick tests: undiluted commercial drug

Intradermal skin tests: starting at a 1:1000 dilution up to a 1:10 dilution

Patch tests

Prick tests, intradermal tests, and subcutaneous tests are preferred to patch tests (as in delayed hypersensitivity reactions).

References

Schindeworff M, Ludwig RJ, Wolter M, et al. Tolerance of Fondaparinux in patients with generalized contact dermatitis to heparin. *J Eur Acad Dermatol Venerol* 2008;22:378-80.

Mazzolai L, Hohlfeld P, Spertini F, et al. Fondaparinux is a safe alternative in case of heparin intolerance during pregnancy. *Blood* 2006;108:569-70.

Maetzke J, Hinrichs R, Schneider LA, et al. Unexpected delayed-type hypersensitivity skin reactions to the ultra-low-molecular-weight heparin fondaparinux. *Allergy* 2005;60:413-16.

Hohenstein E, Tsakiris D, Bircher AJ. Delayed-type hypersensitivity to the ultra-low-molecular-weight heparin fondaparinux. *Contact Dermatitis* 2004;51:149-51.

Jappe U, Juschka U, Kuner N, et al. Fondaparinux: a suitable alternative in cases of delayed-type allergy to heparins and semisynthetic heparinoids? A study of 7 cases. *Contact Dermatitis* 2004;51:67-72.

Hirudins

Hirudins, proteins derived from the leech *Hirudo medicinalis*, specifically inhibit thrombin. Two recombinant hirudins are available: desirudin (approved for thrombosis prophylaxis) and lepirudin (approved for anticoagulation in patients with HIT II and thromboembolic complications).

The compounds differ from each other only in their N-termini. Because of their completely different chemical structure compared with heparins, there is no cross-reactivity with heparins. Successfully used in patients with HIT II and in patients with cell-mediated reactions to heparins.

Incidence

Anaphylaxis: 0.015% on first exposure and 0.16% in re-exposed patients.

Clinical manifestations

• General reactions:

Urticaria, angioedema

Anaphylaxis: anaphylactic shock (sometimes fatal)

• Cutaneous reactions:

Urticaria, angioedema (with facial, lingual and larynx oedema)

Flush reaction

Delayed hypersensitivity reaction: eczematous plaques, granulomatous reaction.

Injections site reaction, sometimes local site Arthus-like reaction

I Diagnostic methods

Skin tests

Prick test: undiluted

Intradermal test: 1:100

Patch tests:

- pure and 10 % in aq with 48 h application and readings at 48 h, 96 h and Day 7;
- pure with 24 h application and readings at 24 h, 48h and 72 h

Specific IgE assay: assay not available.

Hirudin-specific IgG antibodies can be assayed. They are consumed during the reaction and peak 48 h later.

I Management

Alternative therapy: Argatroban, a synthetic thrombin inhibitor, was successfully used in patients with intolerance to heparin and hirudin.

References

Veach SA, Franks AM, Allan MC. Severe anaphylactic reaction after repeated intermittent exposure to lepirudin. *Pharmacotherapy* 2007;27:760-5.

Kemkes-Matthes B, Walenga JM, Harenberg J, et al. Argatroban treatment for patients with intolerance to heparin and hirudin. *Clin Appl Thromb Hemost* 2005;11:99-103.

Greinacher A, Lubenow N, Eichler P. Anaphylactic and anaphylactoid reaction associated with lepirudin in patients with heparin-induced thrombocytopenia. *Circulation* 2003;108:2062-5.

Siths KJ, Rosario-Collazo J, Skelton H. Delayed cutaneous hypersensitivity reactions to hirudin. *Arch Pathol Lab Med* 2001;125:1585-7.

Koch P, Munssinger T, Rupp-John C, et al. Delayed-type hypersensitivity skin reactions caused by subcutaneous unfractionated and low-molecular-weight heparins: tolerance of a new recombinant hirudin. *J Am Acad Dermatol* 2000;42:612-9.

Ticlopidine

A thienopyridine, platelet aggregation inhibitor.

I Incidence

Cutaneous manifestations: 1 to 14%.

Haematological manifestations: 1 to 2.4%.

I Clinical manifestations

- **Cutaneous:** (2 to 21 days after beginning of ticlopidine): pruritus, urticaria, maculopapular eruption

tion, fixed drug eruption, angioedema (rare), erythromelalgia-like eruption, erythema multiforme like eruption, lichen planus-like eruption, acute generalized exanthematous pustulosis (rare), lupus erythematosus.

- **Others:** aplastic anemia, neutropenia, agranulocytosis, thrombopenia, thrombotic thrombocytopenic purpura, abdominal pain, nausea.

I Diagnostic methods

Skin tests

Patch tests: 1% and 5% in pet on affected and unaffected skin (in fixed drug reaction) with positivity on affected skin.

I Mechanisms

Unknown.

I Management

Clopidogrel is nowadays the first-line platelet aggregation inhibitor.

Cross-reactivity between ticlopidine and clopidogrel (2 thienopyridine drugs) is rare: switch to cilostazol, aspirin, enoxaparin or warfarin.

Rapid clearing of the skin eruption in most cases, even when the drug is not withdrawn.

References

Makkar K, Wilensky RL, Julien MB, et al. Rash with both clopidogrel and ticlopidine in two patients following percutaneous coronary intervention with drug-eluting stents. *Ann Pharmacother* 2006;40:1204-7.

Borras-Blasco J, Navarro-Ruiz A, Gutierrez-Casbas A, et al. Multiple fixed-drug eruption and diarrhea with ticlopidine. *Ann Pharmacother* 2002;36:344-5.

Spiera RF, Berman RS, Werner AJ, et al. Ticlopidine-induced lupus: a report of 4 cases. *Arch Intern Med* 2002;162:2240-3.

Garcia CM, Carmena R, Garcia R, et al. Fixed drug eruption from ticlopidine, with positive lesional patch test. *Contact Dermatitis* 2001;44:40-1.

Cannavo SP, Borgia F, Guarnari F, et al. Acute generalized exanthematous pustulosis following use of ticlopidine. *Br J Dermatol* 2000;142:577-8.

Yosipovitch G, Rechavia E, Feinmesser M, et al. Adverse cutaneous reactions to ticlopidine in patients with coronary stents. *J Am Acad Dermatol* 1999;41:473-6.

Warfarin

A widely used oral anticoagulant.

I Incidence

Unknown.

I Risk factors

Protein C and protein S deficiencies, heparin-induced thrombocytopenia, factor V Leiden deficiency for skin necrosis.

I Clinical manifestations

- **Cutaneous:** rash (maculopapular, vesicular, urticarial), pruritus, urticaria, angioedema (rare), skin necrosis (frequent when deficiency in protein C and S, factor V Leiden), purple digit syndrome (fingers and toes, pain, burning sensation, discoloration, gangrene, ulceration), occur early after the onset of treatment; persistent for months after interruption of treatment). Cutaneous symptoms of bleeding: purpura, ecchymoses, haemorrhagic necrosis, vasculitis (with leucocytoclastic phenomenon), alopecia (frequent).

- **Others:** interstitial nephritis.

I Diagnostic methods

None.

I Mechanisms

Unknown.

I Management

Switch to an indanedione (anisindione for example).

References

Kapoor KG, Bekaii-Saab T. Warfarin-induced allergic interstitial nephritis and leucocytoclastic vasculitis. *Intern Med J* 2008;38:281-3.

Kurt M, Shorbagi A, Aksu S, et al. Warfarin-induced skin necrosis and leukocytoclastic vasculitis in a patient with acquired protein C and protein S deficiency. *Blood Coagul Fibrinolysis* 2007;18:805-6.

Rafiei N, Tabandeh H, Hirschbein M. Warfarin-induced skin necrosis of the eyelids. *Arch Ophthalmol* 2007;125:421.

Egred M, Rodrigues E. Purple digit syndrome and warfarin-induced necrosis. *Eur J Intern Med* 2005;16:294-5.

Atropine

Atropine is a premedication drug widely used for the prevention of vagal bradycardia, especially in strabismus surgery, and for the treatment of organophosphoric intoxication.

■ Incidence

Uncommon for anaphylactic shock.
3% for eyedrops containing atropine.

■ Clinical manifestations

- **General:** anaphylactic shock.
- **Cutaneous:** rashes (face, neck, chest), periocular contact dermatitis.

■ Diagnostic methods

Skin tests

Prick tests (atropine sulfate 1/1000).

Intradermal tests: atropine 0.01/1000 to 1/100 is sometimes positive.

Patch tests: atropine sulfate 1% in aq

No **Specific IgE** found.

■ Mechanisms

IgE-mediated hypersensitivity.

■ Management

Avoidance.

Strabismus surgery may be performed with hyoscine or glycopyrronium after skin tests.

In the treatment of organophosphoric intoxication, use glycopyrrolate/diazepam or midazolam or scopolamine.

References

Coelho D, Fernandes T, Branga P, et al. Intraoperative anaphylaxis after intravenous atropine. *Eur J Anaesthesiol* 2007; 24:289-90.

Ventura MT, Di Corato R, Di Leo E, et al. Eyedrop-induced allergy: clinical evaluation and diagnostic protocol. *Immunopharmacol Immunotoxicol* 2003;25:529-38.

de Misa RF, Suarez J, Feliciano L, et al. Allergic periocular contact dermatitis due to atropine. *Clin Exp Dermatol* 2003;28:97-8.

Robenshtok E, Luria S, Tashma Z, et al. Adverse reaction to atropine and the treatment of organophosphate intoxication. Isr Med Assoc J 2002;4:535-9.

Decraene T, Goossens A. Contact allergy to atropine and other mydriatic agents in eye drops. Contact Dermatitis 2001;45:309-10.

Aguilera L, Martinez-Bourio R, Cid C, et al. Anaphylactic reaction after atropine. Anaesthesia 1988;43:955-7.

Beta-blockers

A family of drugs widely used to treat arterial hypertension and angina, as well as for local treatment of glaucoma.

Three important problems:

- ▶ Beta-blockers and asthma
- ▶ Beta-blockers and anaphylactic shock
- ▶ Beta-blockers and local allergic effect

■ Incidence

One 40 or 80 mg tablet of propranolol can induce bronchoconstriction in 50% of asthmatics, but the rate is probably much lower with cardioselective beta-blockers.

Bronchoconstriction also occasionally occurs in patients with chronic bronchitis. Thirteen deaths and 200 major reactions to timolol maleate eye drops have been reported in asthmatics in the USA.

Beta-blockers and anaphylactic shock: unknown.

Beta-blockers in eye-drops are widely used for the treatment of glaucoma; the local allergic effect has recently been recognized.

■ Clinical manifestations

- **General:** anaphylactic shock occurring in patients under beta-blocker treatment is characterized by bradycardia despite collapse and a poor response to epinephrine.
- **Cutaneous:** pruritus, eczematous chronic rash, urticaria, cholinergic urticaria (may become apparent), psoriasis and psoriasiform eruption (sometimes atypical), lichenoid drug eruption, fixed drug eruption, lupus erythematosus, Raynaud's phenomenon (frequent), bullous pemphigoid, pemphigus (rare), erythema multiforme, Stevens-Johnson syndrome, toxic epidermal necrolysis, pseudolymphoma, alopecia, nail alterations.

Topical use: contact dermatitis with beta-blocker-containing eye-drops (eyelid eczema and conjunctivitis) and possibly systemic manifestations with oral beta-blockers.

- **Respiratory:** asthma, bronchospasm, dyspnea, apnea in children, respiratory arrest, hypersensitivity pneumonitis, diffuse interstitial pneumonitis with or without pleural effusion, BOOP (acebutolol, sotalol).

■ Diagnostic methods

- Beta-blockers and asthma: clinical signs and spirometric data.
- Beta-blockers and anaphylactic shock: clinical signs.
- Beta-blockers and eczema: patch tests with eye-drops (pure).

I Mechanisms

Beta-blockers and anaphylactic shock: beta-blockers inhibit the production of cyclic AMP (thereby reducing intracellular levels) and lower the threshold of mediator release by mastocytes and basophils. Beta-blockers decrease endogenous adrenaline secretion by blocking beta-2-receptors at synapses, and inhibit beta 1 effects of exogenous and endogenous adrenaline on the heart.

In contact allergy, beta-blockers, having a very similar structure, are cross-reacting. This may be due to a common aldehyde group after primary metabolism.

I Management

Beta-blockers and asthma:

- If a beta-blocker must be administered to an asthmatic patient, use a selective beta 1 agent. When necessary, tolerance can be determined by quantitative measurement of cardioselectivity.

Clinical surveillance and spirometry at the time of administration.

Administration in hospital:

Day 1: 1/10th of the dose.

Day 2: 1/5th of the dose.

Day 3: 1/2 of the dose.

Day 4: full dose.

- If beta-blocker eye drops must be administered to an asthmatic patient, first test tolerance, e.g., to timolol: instillation of one drop of timolol collyrium at 0.50% in each eye followed by a second instillation 20 minutes later; clinical surveillance (chest auscultation, pulse and arterial blood pressure) at start, then at 15, 30, 60 and 120 minutes; perform spirometry at the same time.

- The best agent available at the present time is a beta 1-selective product: betaxolol.

Beta-blockers and anaphylactic shock:

Curative treatment:

- refractory to adrenaline;
- use of isoprenaline, dopamine, or glucagon;
- blood volume expansion necessary (6 to 7 l).

Preventive treatment:

- Skin tests and desensitization under beta-blockers is contra-indicated
- For anesthesia, either discontinue beta-blockers 48 hours before surgery, or perform an isoprenaline test during surgery (seldom done).

Beta-blockers and contact eczema with eye-drops:

Avoidance. The risk of recurrence is high if another local beta-blocker is used. Switch to another drug.

References

- Brauchi YB, Jick SS, Curtin F, et al. Association between beta-blockers, other antihypertensive drugs and psoriasis: population-based case-control study. Br J Dermatol 2008;158:1299-1307.*
- Bodmer M, Egger SS, Hohenstein E, et al. Lichenoid eruption associated with the use of nebivolol. Ann Pharmacother 2006;40:1688-90.*
- Fenniche S, Dhaoui A, Ammar FB, et al. Acebutolol-induced subacute cutaneous lupus erythematosus. Skin Pharmacol Physiol 2005;18:230-3.*
- Florez A, Roson E, Conde A, et al. Epidermal necrolysis secondary to timolol, dorzolamide and latanoprost eye-drops. J Am Acad Dermatol 2005;53:909-11.*
- Tattersfield AE. Beta adrenoreceptor antagonists and respiratory disease. J Cardiovasc Pharmacol 1986;8,35-9.*
- Dunn TL, Gerber MJ, Shen AS, et al. The effect of topical ophthalmic instillation of timolol and betaxolol on lung function in asthmatic subjects. Am Rev Respir Dis 1986;133:264-8.*

Bosentan

An endothelin receptor antagonist approved for the treatment of pulmonary arterial hypertension.

■ Incidence

Rare.

■ Clinical manifestations

- **General:** fever.
- **Cutaneous:** flushing, peripheral edema, pruritus, rash, vasculitis (leukocytoclastic).

■ Diagnostic methods

None.

■ Mechanisms

Unknown.

■ Management

Avoidance.

References

Nagai Y, Yamanaka M, Nishimura S, et al. Drug eruption due to bosentan in a patient with systemic sclerosis. *Mod Rheumatol* 2006;16:188-90.

Gasser S, Kuhn M, Speich R. Severe necrotising leukocytoclastic vasculitis in a patient taking bosentan. *BMJ* 2004;329:430.

Bovine Thrombin

Topical bovine thrombin is a heterologous plasma thrombin of bovine origin that is used as a topical haemostatic agent: surgical procedures, control haemostasis after vascular surgery or access (haemodialysis).

■ Risk factors

Multiple exposures.

■ Clinical manifestations

- **General:** anaphylactic shock.
- **Respiratory:** occupational rhinitis and asthma.

■ Diagnostic methods

Skin tests

Prick tests: with a saturated solution of topical bovine thrombin in normal saline (positive in one patient).

Specific IgE/IgG (ELISA): positive in one patient.

■ Mechanisms

IgE-mediated hypersensitivity.

■ Management

Avoidance.

References

- Wai Y, Tsui V, Peng Z, et al. Anaphylaxis from topical bovine thrombin (Thrombostat*) during haemodialysis and evaluation of sensitization among a dialysis population. *Clin Exp Allergy* 2003;33:1730-4.
- Rotenberg DM, Moy JN. Anaphylactic reaction to topical bovine thrombin. *Anesthesiology* 1993;78:779-82.
- Tadokoro K, Ohtoshi T, Takafuji S, et al. Topical thrombin-induced IgE-mediated anaphylaxis. RAST analysis and skin test studies. *J Allergy Clin Immunol* 1991;88:620-9.

Calcium channel blockers

Used in cardiology to manage ischemic heart disease or high blood pressure.

Calcium channel blockers are classified in 3 classes:

- ▶ **Dihydropyridines:** amlodipine, felodipine, isradipine, lacidipine, nicardipine, nifedipine, nimodipine, nitrendipine and nisoldipine.
- ▶ **Phenylalkylamines:** verapamil.
- ▶ **Benzothiazepines:** diltiazem.

Among CCB, diltiazem is the principal drug involved in adverse cutaneous drug reactions.

■ Clinical manifestations

• **Cutaneous:** pruritus, urticaria, angioedema (rare), maculo-papular rash, exfoliative dermatitis, erythroderma, peripheral edema, flush (pharmacodynamic effect), erythema multiforme (sometimes severe), Stevens -Johnson syndrome, toxic epidermal necrolysis (exceptional), photosensitivity and pigmentation (frequent), acute generalized exanthematous pustulosis (usual with diltiazem), lupus erythematosus-like lesions, hypersensitivity syndrome, psoriasiform eruption, vasculitis (rare), gingival hypertrophy, alopecia.

■ Diagnostic methods

Skin tests

Patch tests: diltiazem 10 % in pet.

Photopatch tests with UVA irradiation may be positive in cases of photosensitivity.

In case of severe cutaneous reactions such as Stevens-Johnson syndrome, Lyell's syndrome or hypersensitivity syndrome, these tests should be performed with caution, beginning with very low concentrations of the drugs (0.1%).

Lymphocyte activation tests (LAT).

Positive in some cases.

Drug re-challenge with nifedipine or verapamil in diltiazem reactor patients is rarely positive. Similarly nifedipine-reactive patients have usually tolerated diltiazem. Conversely, one patient with non-thrombocytopenic purpura due to nifedipine had a similar eruption with diltiazem; another patient with pruritic exanthema after diltiazem had a recurrence after amlodipine.

■ Mechanisms

Unknown.

■ Management

In cases of reactions to CCB belonging to the dihydropyridine class, it is possible to re-administer a non-dihydropyridine CCB drug with caution, if the patch test is negative.

References

Ramirez A, Perez-Perez L, Fernandez-Redondo V, et al. Photoallergic induced by diltiazem. *Contact Dermatitis* 2007;56:118-9.

Gonzalo Garijo MA, Perez Calderon R, de Argila Fernandez-Duran D, et al. Cutaneous reactions due to diltiazem and cross reactivity with other calcium channel blockers. *Allergologia et Immunopathologia* 2005;33:238-40.

Cholez C, Trechot P, Schmutz JL, et al. Maculopapular rash induced by diltiazem: allergological investigations in four patients and cross-reactions between calcium channel blockers. *Allergy* 2003;58:1207-9.

Knowles S, Gupta AK, Shear NH. The spectrum of cutaneous reactions associated with diltiazem: three cases and a review of the literature. *J Am Acad Dermatol* 1998;38:201-6.

Baker BA, Cacchione JG. Cross-sensitivity between diltiazem and amlodipine. *Ann Pharmacother* 1994;28:118-9.

Clonidine

An adrenergic alpha-receptor agonist used in the treatment of essential hypertension.

■ Incidence

Allergic contact dermatitis in 14-38% after transdermal clonidine patch.

■ Clinical manifestations

• **Cutaneous:** xerostomia (frequent), rash, pruritus, urticaria, angioedema (less frequent), Raynaud's phenomenon (rare), psoriasis exacerbation (rare), lupus erythematosus (rare).

Transdermal clonidine patch: local reaction, allergic contact dermatitis, pseudo lymphoma.

■ Diagnostic methods

Skin tests

Patch tests (transdermal preparation containing clonidine): positive in a patient who had reacted to transdermal, oral and intravenous clonidine.

■ Mechanisms

Delayed hypersensitivity.

■ Management

Avoidance.

Pretreatment with 0.5% hydrocortisone is associated with less skin irritation (transdermic clonidine).

References

Prisant LM. Transdermal clonidine skin reactions. *J Clin Hypertens* 2002;4:136-8.

Crivellaro MA, Bonadonna P, Dama AR. Skin reactions to clonidine: not just a local problem. *Case report. Allergol Immunopathol* 1999;27:318-9.

Fibrates

Lipid lowering drugs used preferentially in patients with high triglycerides levels and/or low HDLcholesterol.

■ Incidence

Low.

■ Clinical manifestations

- **General:** fever, myolysis, anaphylactic shock (one case with bezafibrate and with bezalip).
- **Cutaneous:** pruritus, angioedema, rash, photosensitivity (+++) with sometimes lichenoid aspect, acquired ichthyosis, alopecia, gynecomastia, polymyositis.
- **Haematological:** anemia, leukopenia, pancytopenia.
- **Others:** hepatitis, eosinophilic gastroenteritis.

■ Diagnostic methods

Skin tests

Photopatch tests (UVA, UVB, or a combination of both) with patch tests (concentration 1% to 5% of fenofibrate in pet).

Intradermal skin tests: one positive case (anaphylactic shock with bezafibrate).

■ Mechanisms

Cross-reactive photoallergy to ketoprofen and fenofibrate can be explained by the common benzoyl-ketone structure of these compounds.

■ Management

Avoidance.

An association between systemic photosensitivity to fenofibrate and photocontact sensitivity to ketoprofen, tiaprofenic acid, benzophenone and oxybenzone seems to exist.

References

Frendo M, Theuma R, Fava S. Delayed bezafibrate-induced angio-oedema in a 68-year-old man. *Br J Clin Pharmacol* 2007;64:560-1.

de Barrio M, Matheu V, Baeza ML, et al. Bezafibrate-induced anaphylactic shock : unusual clinical presentation. *J Investig Allergol Clin Immunol* 2001;11:53-5.

Rabasa-Lhoret R, Rasamisoa M, Avignon A, et al. Rare side-effects of fenofibrate (Article in French). *Diabetes Metab (Paris)* 2001;27:66-8.

Veyrac G, Paulin M, Milpied B, et al. Results of a French nationwide survey of cutaneous side effects of ketoprofen gel reported between September 1996 and August 2000 (Article in French). *Therapie* 2002;57:55-64.

Machet L, Vaillant L, Jan V, et al. Fenofibrate-induced photosensitivity: value of photopatch-testing. *J. Am. Acad. Dermatol.* 1997;37:808-9

Furosemide

Furosemide (chloro-4-furfurylamino-2-sulfamoyl-5-benzoic acid) is a widely used Henle's loop diuretic.

■ Incidence

Exceedingly rare for anaphylactic reactions.
0.5% for mild cutaneous reactions.

■ Clinical manifestations

General: anaphylactic shock.

Cutaneous: pruritus, urticaria, periorbital edema, eczematous rash, bullous pemphigoid, photosensitivity with bullous dermatitis (frequent), lichen-planus pemphigoides, pseudoporphyria cutanea tarda, vasculitis, purpura, Sweet syndrome, acute generalized exanthematic pustulosis, erythema multiforme, Stevens-Johnson's syndrome, toxic epidermal necrolysis, linear IgA bullous dermatitis, papuloerythroderma of Ofuji, hyperpigmented macules.

Respiratory: acute pulmonary edema.

Digestive: pancreatitis, hepatitis.

■ Diagnostic methods

Skin tests

Prick tests (10 mg/ml): negative.

Intradermal skin tests (1%): positive for furosemide as well as for chlorothiazide, bumetanide and sulfamethoxazole-trimethoprim (in one patient).

One case with delayed positivity (10th hour).

■ Mechanisms

IgE-mediated hypersensitivity.

Type III hypersensitivity suspected in pancreatitis and hepatitis.

■ Management

Avoidance.

No cross-reactivity between furosemide and sulfonamides.

Bumetanide may be used as replacement therapy in furosemide-induced vasculitis.

Use of ethacrynic acid.

Desensitization (few cases reported): for example 0.05 mg to 20 mg in ten days.

References

- Hemstreet BA, Page RL 2nd. Sulfonamide allergies and outcomes related to use of potentially cross-reactive drugs in hospitalized patients. *Pharmacotherapy* 2006;26:551-7.
- Lee JJ, Downham TF. Furosemide-induced bullous pemphigoid : case report and review of literature. *J Drugs Dermatol* 2006;5:562-4.
- Dominguez-Ortega J, Martinez-Alonso JC, Dominguez-Ortega C, et al. Anaphylaxis to oral furosemide (Article in Spanish). *Allergol Immuno* 2003;31:345-7.
- Earl G, Davenport J, Narula J. Furosemide challenge in patients with heart failure and adverse reactions to sulfa-containing diuretics. *Ann Intern Med* 2003;138:358-9.
- Gratadour P, Guillaume C, Bui-Xuan B, et al. Absence of cross allergy between furosemide and bumetanide. (Article in French) *Presse Med* 1990;19:1504.
- Breuil K, Patte F, Meurice J.C, et al. Delayed allergy to furosemide (Article in French). *Rev Fr Allerg* 1989;29:150-1.
- Hansbrough JR, Wedner HJ, Chaplin DD. Anaphylaxis to intravenous furosemide. *J Allergy Clin Immunol* 1987;80:538-41.
- Thestrup-Pedersen K. Adverse reactions in the skin from antihypertensive drugs. *Dan Med Bull* 1987;34:3-5.
- Tuzel IH. Comparison of adverse reactions to bumetanide and furosemide. *J Clin Pharmacol* 1981;21:615-9.

Hydralazine

A vasodilator used in cardiovascular diseases.

I Incidence

Unknown.

I Clinical manifestations

- **Cutaneous:** lupus erythematosus (+++), one-to-two years after initiation (musculo-skeletal complaints, fever, weight loss); Sweet's syndrome, rash, pruritus, angioedema, (rare), fixed drug eruption, vasculitis, contact dermatitis (occupational).
- **Respiratory:** BOOP, subacute cellular interstitial pneumonitis, alveolar hemorrhage, pleural effusion, pleural/pericardial thickening.
- **Others:** hepatitis.

I Diagnostic methods

None.

I Mechanisms

Unknown.

I Management

Avoidance.

References

Norris JH, Leeds J, Jeffrey RF. P-ANCA positive renal vasculitis in association with renal cell carcinoma and prolonged hydralazine therapy. *Ren Fail* 2003;25:311-4.

Gilmour E, Chalmers RJ, Rowlands DJ. Drug-induced Sweet's syndrome (acute febrile neutrophilic dermatosis) associated with hydralazine. *Br J Dermatol* 1995;133:490-1.

Reynolds NJ, Wallington TB, Burton TL. Hydralazine predisposes to acute cutaneous vasculitis following urography with iopamidol. *Br J Dermatol* 1993;129:82-5.

Hydrochlorothiazide

A widely used sulfonamide diuretic.

■ Incidence

50 cases of non-cardiogenic oedema and shock reported.

■ Risk factors

Female sex (90% of cases) for allergic interstitial pneumonitis.

■ Clinical manifestations

- **Cutaneous:** photosensitivity (+++), lupus erythematosus, toxic epidermal necrolysis (rare), vasculitis thrombocytopenic purpura, acute generalized exanthematous pustulosis, lichenoid eruption, angioedema, pityriasis-rosea like reaction.
- **Respiratory:** acute allergic interstitial pneumonitis or non-cardiogenic oedema: dyspnea, cough, wheezing, cyanosis and chest pain sometimes associated to shock (low blood pressure, tachycardia, faintness), general signs (fever, chills), or digestive (nausea, vomiting, abdominal cramps), occurring 10 to 150 mn after drug intake.

■ Diagnostic methods

Skin tests

Patch tests: 10% in pet.

Photopatch tests.

■ Mechanisms

Type III for non-cardiogenic pulmonary oedema and shock.

Cross-reactivity with sulfonamide antibiotics is weak.

■ Management

Avoidance.

References

Goetschalckx K, Ceuppens J, Van Mieghem W, et al. Hydrochlorothiazide-associated noncardiogenic pulmonary oedema and shock: a case report and review of the literature. *Acta Cardiol* 2007;62:215-20.

Ruscin JM, Page RL 2nd, Scott J. Hydrochlorothiazide-induced angioedema in a patient allergic to sulfonamide antibiotics: evidence from a case report and a review of the literature. *Am J Geriatr Pharmacother* 2006;4:325-9.

Pétavy-Catala C, Martin L, Fontès V, et al. Hydrochlorothiazide-induced acute generalized exanthematous pustulosis. *Acta Derm Venereol* 2001;81:209.

Biron P, Dessureault J, Napke E. Acute allergic interstitial pneumonitis induced by hydrochlorothiazide. *Can Med Assoc J* 1991;145:28-34.

Indapamide

A non-thiazide chlorobenzamide sulfonamide diuretic used to treat essential hypertension. It is prepared by condensing chloro sulfonamide acid chloride with an indole amine.

■ Incidence

Rashes are frequent.

■ Clinical manifestations

• **General:** fever.

• **Cutaneous:** pruritus, urticaria, angioedema, rash, erythema multiforme, Stevens-Johnson syndrome, toxic epidermal necrolysis, lupus erythematosus (aggravation), pemphigus, fixed drug eruption, photosensitivity (with onycholysis).

■ Diagnostic methods

Controlled oral challenge test: positive in one case.

■ Mechanisms

Unknown.

■ Management

Avoidance.

Cross-reactivity with other thiazide diuretics and sulfonamides is weak.

References

Rutherford T, Sinclair R. Photo-onycholysis due to indapamide. *Australas J Dermatol* 2007;48:35-6.

De Barrio M, Tornero P, Zubeldia JM, et al. Fixed drug reaction induced by indapamide. Cross-reactivity with sulfonamides. *J Investig Allergol Clin Immunol* 1998;8:253-5.

Partanen J, Pohjola-Sintonen S, Makijarvi M, et al. Toxic epidermal necrolysis due to indapamide. *Arch Dermatol* 1993;129:793.

Black RJ, Murphy P, Robinson TJ, et al. Toxic epidermal necrolysis associated with indapamide. *BMJ* 1990;301(6763):1280-1.

LDL apheresis

Severe hypercholesterolemia resistant to anti-lipidemic drugs can be corrected using low density lipoprotein (LDL) apheresis.

■ Incidence

Uncommon.

■ Risk factors

Concomitant use of ACE inhibitors.

■ Clinical manifestations

- **General:** hypotension, bradycardia.
- **Cutaneous:** flushing, facial edema.
- **Respiratory:** dyspnea.
- **Digestive:** nausea, abdominal pain.

■ Mechanisms

The negative charges of dextran-sulfate-cellulose (DSC) used for selective adsorption of LDL activate the intrinsic coagulation pathway, leading to the conversion of plasma prekallikrein in to plasma kallikrein which catalyzes high molecular weight kininogen to produce large amounts of bradykinin. Bradykinin breakdown is inhibited by ACE inhibitors.

■ Management

Nafamostat mesylate, in contrast to heparin, inhibits bradykinin generation during LDL apheresis. Losartan (AT 1 antagonist) is safe in patients under treatment by LDL apheresis despite increase in bradykinin levels and a slight lowering of blood pressure.

References

Kojima S, Shida M, Takano H, et al. Effects of losartan on blood pressure and humoral factors in a patient who suffered from anaphylactoid reactions when treated with ACE inhibitors during LDL apheresis. *Hypertens Res* 2001;24:595-8.

Sinzinger H, Chehne F, Ferlitsch A, et al. Angiotensin receptor antagonists during dextran sulfate LDL-apheresis are safe. *Thromb Res* 2000;100:43-6.

Elicio N, Bertolini S, Garbarini R, et al. LDL apheresis with dextran sulfate and angiotensin receptor antagonist (Losartan). *Artif Organs* 1997;27:334-5.

Schwarzbeck A, Hilgenfeldt U, Riester U, et al. Anaphylactoid reactions during dextran apheresis may occur even in the absence of ACE-inhibitor administration. *Nephrol Dial Transplant* 1997;12:1083-4.

Koga N, Nagano T, Sato T, et al. Anaphylactoid reactions and bradykinin generation in patients treated with LDL-apheresis and an ACE inhibitor. *ASAIO J* 1993;39:M288-91.

Keller C, Grutzmacher P, Bahr F, et al. LDL-apheresis with dextran sulphate and anaphylactoid reactions to ACE inhibitors. *Lancet* 1993;341(8836):60-1.

Mexiletine

I_b antiarrhythmic agent.

■ Incidence

Rare.

■ Risk factors

For DIHS: elderly black men, flu-like illness within the previous 6 weeks.

■ Clinical manifestations

Drug induced hypersensitivity syndrome

- 1/ Maculopapular rash developing > 3 weeks after starting.
- 2/ Prolonged clinical symptoms after discontinuation of the causative drug.
- 3/ Fever > 38°C (usually precedes the rash).
- 4/ Liver abnormalities (ALT > 100 u/l).
- 5/ Leukocyte abnormalities (leukocytosis > 11x10⁹/l or atypical lymphocytosis (>5%) or eosinophilia > 1.5x10⁹/l).
- 6/ Lymphadenopathy.
- 7/ HHV 6 or 7 reactivation: increase in IgG titers detected in the 2nd to 3rd week after the start of symptoms.
- 8/ Various forms of renal involvement from tubulo-interstitial nephritis to granulomatous necrotizing angitis.

• **Cutaneous:** pruritus, rash (morbilliform, maculopapular), erythroderma, urticaria, prurigo, facial edema, acral edema, acute exanthematous pustular eruption, contact urticaria (in a patient receiving iontophoresis), erythema multiforme, Stevens-Johnson syndrome (rare).

■ Diagnostic methods

Skin tests

Patch tests with 10% and 20% mexiletine hydrochloride in pet; sometimes positive in DIHS.

■ Mechanisms

Hypersensitivity syndrome. The two main hypotheses are:

- 1) Stimulation of T cells by the drug leading to reactivation of herpes virus harbored in T cells.
- 2) Clinically unapparent reactivation of herpes virus occurs. The virus-stimulated T cells show substantial cross-reactivity with certain drugs; administration of the drugs leads to an expansion of these specific T cells, which continues after cessation of the drug due to the persistence of the viral antigens.

■ Management

Avoidance.

Treatment of DIHS: steroids 1 to 1.5 mg/Kg; intravenous immunoglobulins, plasma exchange.

References

Tohyama M, Hashimoto K, Yasukawa M, et al. Association of human herpesvirus 6 reactivation with the flaring and severity of drug-induced hypersensitivity syndrome. *Br J Dermatol* 2007;157:934-40.

Yagami A, Yoshikawa T, Asano Y, et al. Drug-induced hypersensitivity syndrome due to mexiletine hydrochloride associated with reactivation of human herpesvirus 7. *Dermatology* 2006;213:341-4.

Sasaki K, Yamamoto T, Kishi M, et al. Acute exanthematous pustular drug eruption induced by mexiletine. *Eur J Dermatol* 2001;11:469-71.

Higa K, Hirata K, Dan K. Mexiletine-induced severe skin eruption, fever, eosinophilia, atypical lymphocytosis, and liver dysfunction. *Pain* 1997;73:97-9.

Pentoxifylline

A purine derivative used as vasodilator to relieve symptoms in some cases of intermittent claudication.

■ Incidence

Very rare.

■ Clinical manifestations

- **Cutaneous:** generalized exanthematous pustulosis, pruritus, rash, urticaria, angioedema, serum sickness (one case in association with cefoxitin)

■ Diagnostic methods

Skin tests

Prick tests negative.

Intradermal tests: positive (0.2 mg/ml). Negative for other purine derivatives.

Challenge test: positive in one patient.

■ Mechanisms

IgE-mediated hypersensitivity.

■ Management

Avoidance.

References

Patrizi A, Tabanelli M, Antonucci A, et al. Generalized exanthematous pustulosis induced by pentoxifylline. *Int J Dermatol* 2007;46:1310-2.

Gonzalez-Mahave I, Delgado MD, Blasco A, et al. Urticaria due to pentoxifylline. *Allergy* 2005;60:705.

Panwalker AP, Gibson K, Glynn MJ, et al. Serum sickness associated with cefoxitin and pentoxifylline therapy. *Drug Intell Clin Pharm* 1986;20:953-4.

Prazosin

Prazosin, a derivative of quinazoline, is an antihypertensive drug that produces vasodilation by blocking post-synaptic alpha receptors.

■ Incidence

Urticaria: 0.3% of subjects treated.

Anaphylactic shock: one case reported.

■ Clinical manifestations

- **General:** anaphylactic shock
- **Cutaneous:** urticaria, angioedema, pruritus, peripheral edema.
- **Respiratory:** bronchospasm.

■ Diagnostic methods

Skin tests

Prick tests are very hazardous (one collapse reported).

No specific IgE found.

■ Mechanisms

Undetermined.

■ Management

Avoidance.

References

Chodosh S, Tuck J, Pizzuto D. Prazosin in hypertensive patients with chronic bronchitis and asthma: a brief report. *Am J Med* 1989;86:91-3.

Ruzicka T, Ring J. Hypersensitivity to prazosin. *Lancet* 1983;1(8322):473-4.

Propafenone

A membrane-stabilizing antiarrhythmic agent resembling propranolol structurally.

I Incidence

Rare.

I Clinical manifestations

- **Cutaneous:** rash, urticaria, angioedema, acute generalized exanthematous pustulosis, psoriasis-aggravation, lupus erythematosus-like syndrome.
- **Respiratory:** asthma exacerbation, reactive airway disease.
- **Digestive:** allergic hepatitis.

I Diagnostic methods

None.

I Mechanisms

Unknown.

I Management

Avoidance.

References

Pallestchi GM, Bellandi S, Torchia D. Propafenone-induced psoriasis. *Clin Exp Dermatol* 2008;33:209-10.

Incorvaia C, Pravettoni C, Riario-Sforza GG. Angioedema reaction caused by propafenone. *Allergy* 2006;61:269.

Huang YM, Lee WR, Hu CH, et al. Propafenone induced acute generalized exanthematous pustulosis. *Int J Dermatol* 2005;44:256-7.

Olm M, Munne P, Jimenez MJ. Severe reactive airways disease induced by propafenone. *Chest* 1989;95:1366-7.

Guindo J, Rodriguez de la Serna A, Borja J, et al. Propafenone and a syndrome of the lupus erythematosus type. *Ann Intern Med* 1986;104:589.

Protamin

A strongly alkaline polycationic molecule used to neutralize the anticoagulant effect of heparin or to slow the absorption of insulin. It is purified commercially from salmon milt.

■ Incidence

2.9% to 26.6% of insulin-dependent diabetic patients with NPH insulin or PZ insulin have reactions to intravenously administered protamine versus 0.76% to 0.4% of non-diabetic patients.

Pulmonary vasoconstriction: 1.2%

Deaths reported.

■ Risk factors

Single-dose intravenous protamine results in protamine-specific IgE or IgG antibody production in 28% of patients. Seroconversion is associated with male gender and insulin-dependent mellitus; these patients may be at increased risk on subsequent exposure.

Insulin-dependent diabetic patients treated with NPH or PZI: the presence of IgE to protamine leads to a relative risk of 95 if protamine is used; the presence of IgG to protamine leads to a relative risk of 38.

In patients with no prior exposure to SC protamine insulin preparations, the presence of IgG to protamine leads to a relative risk of 25.

Previous protamine exposure.

Vasectomy and fish allergy are not risk factors.

■ Clinical manifestations.

- **General:** anaphylactic shock, systemic hypotension +/- pulmonary vasoconstriction.
- **Cutaneous:** urticaria, rash, angioedema, contact dermatitis (eczematous).
- **Respiratory:** bronchospasm.

■ Diagnostic methods

Skin tests (controversial)

Intradermal skin tests with 1 µg/ml and 10 µg/ml protamine give false positive results. Immediate and delayed (24h and 48h) evaluation is necessary.

Prick tests positive at 10 mg/ml in one patient with NPH insulin allergy.

Protamine specific antibody assays.

Specific IgE and IgG (solid phase immunoassays, ELISA): false positive.

■ Mechanisms

IgE- or IgG-mediated hypersensitivity (with or without complement activation, unrelated to rate of administration).

Complement activation (by heparin-protamine complexes or by interaction with protamine-antipro-

tamine IgG antibody complexes leading to generation of C3a, C4a, C5a).
Direct non-immunological histamine release.
Inhibition of serum carboxypeptidase.
Potentiation of IgE-mediated histamine release.
Increase of thromboxane A2 and 6 ketoprotaglandin F1 alpha, causing pulmonary arterial pressure elevation.

I Management

Methylene blue can reverse catastrophic pulmonary vasoconstriction.
Use of ancrod or hirudin instead of heparin.
Use of hexadimethrine in place of protamine.
Use of adjuncts to promote hemostasis (antifibrinolytics, aprotinin).
Premedication with antihistamines and steroids reduces the severity of an allergic reaction (controversial)

References

- Rapp U, Liekenbröcker T, Kappa A, et al. Delayed-type hypersensitivity to protamine as a complication of insulin therapy. *Contact Dermatitis* 2005;53:57-8.
- Park KW. Protamine and protamine reactions. *Int Anesthesiol Clin* 2004;42:135-45.
- Viaro F, Dalio MB, Evora PR. Catastrophic cardiovascular adverse reactions to protamine are nitric oxide/cyclic guanosine monophosphate dependent and endothelium mediated: should methylene blue be the treatment of choice? *Chest* 2002;122:1061-6.
- Porsche R, Brenner ZR. Allergy to protamine sulphate. *Heart Lung* 1999;28:418-28.
- Nyhan DP, Shampaine EL, Hirshman CA, et al. Single doses of intravenous protamine result in the formation of protamine-specific IgE and IgG antibodies. *J Allergy Clin Immunol* 1996;97:991-7.
- Horow JC, Pharo GH, Levit LS, et al. Neither skin-tests nor serum enzyme-linked immunosorbent assay tests provide specificity for protamine allergy. *Anesth Analg* 1996;82:386-9.
- Weiss ME, Adkinson NF Jr. Allergy to protamine. *Clin Rev Allergy* 1991;9:339-55.

Sartans

The following angiotensin II receptor antagonists are used in the treatment of arterial hypertension: candesartan, eprosartan, irbesartan, losartan, olmesartan, telmisartan and valsartan.

■ Incidence

Angioedema: 7.7 to 50% in patients with previous angioedema under ACE inhibitors.

■ Risk factors

Angioedema: female sex, African-Americans, previous angioedema with ACE inhibitors.

■ Clinical manifestations

- **General:** anaphylactic shock, fever, angioedema (primary location lips and tongue), time to onset from first weeks to up to 15 years. Others: penile angioedema, intestine angioedema (ileus).
- **Cutaneous:** pruritus, angioedema (sometimes dose-dependant, severe; sometimes anteriority of drug-induced angioedema as angiotensin converting enzyme inhibitor), rash, photosensitivity rash, psoriasis (exacerbation or de novo; predominance of the lesions on sun-exposed areas; severe ungual involvement possible), vasculitis (sometimes clinically severe, bullous and pustular, with leucocytoclastic phenomena on biopsy, with systemic manifestations), Henoch-Schoenlein purpura, lymphomatoid drug eruption, bullous pemphigoid.
- **Respiratory:** increase of bronchial hyperresponsiveness in asthmatic patients (controversial).
- **Others:** acute nephritic syndrome, malignant glaucoma (postsurgery).

■ Diagnostic methods

One case with positive lymphocyte transformation test (skin eruption, fever).

■ Mechanisms

Not fully understood for angioedema; increase of kinin production via the stimulation of angiotensin receptor type II and/or lack of degradation of kinins via multiple enzymes other than ACE.

■ Management

Avoidance.

References

McCabe J, Stork C, Mailloux D, et al. Penile angioedema associated with the use of angiotensin-converting-enzyme inhibitors and angiotensin II receptor blockers. *Am J Health Syst Pharm* 2008;65:420-1.

Saraceno R, Citarella L, Spallone G, et al. A biological approach in a patient with psoriasis and bullous pemphigoid associated with associated with losartan therapy. *Clin Exp Dermatol* 2008;33:154-5.

Roskiewicz F, Andriamanana I, Gras-Champel V, et al. Iatrogenic angioedema: the role of angiotensin converting

enzyme inhibitor and angiotensin II receptor blockers. *Nephrol Ther* 2007;3:89-95.

Malde B, Regalado J, Greenberger PA. Investigation of angioedema associated with the use of angiotensin-converting enzyme inhibitors and angiotensin receptor blockers. *Ann Allergy Asthma Immunol* 2007;98:57-63.

Nielsen EW. Hypotensive shock and angio-oedema from angiotensin II receptor blocker: a class effect in spite of tripled tryptase values. *J Intern Med* 2005;258:385-7.

Mutasim DF. Lymphomatoid drug eruption mimicking digitate dermatosis: cross reactivity between two drugs that suppress angiotensin II function. *Am J Dermatopathol* 2003;25:331-4.

Marquart-Elbaz C, Grosshans E, Alt M, et al. Sartans, angiotensin II receptor antagonists, can induce psoriasis. *Br J Dermatol* 2002;147:617-8.

Spironolactone

Spironolactone is a potassium-sparing diuretic used in the management of cirrhotic ascites.

■ Incidence

Rare.

■ Clinical manifestations

- **General:** DRESS syndrome (rare).
- **Cutaneous:** pruritus, rash, bullous pemphigoid, lichenoid eruption, erythema annulare centrifugum, lupus erythematosus-like eruption, gynecomastia, xerosis, erythema multiforme (rare), DRESS syndrome (rare), allergic contact dermatitis (spironolactone-containing anti-acne cream).

■ Diagnostic methods

Skin tests

Patch tests: a few reports (one DRESS syndrome) with positive patch tests.

■ Mechanisms

Unknown.

■ Management

Avoidance.

One case of desensitization (1 mg → 400 mg in 14 days) in a cirrhotic patient.

References

Ghislain PD, Bodarwe AD, Vanderdonck O, et al. Drug-induced eosinophilia and multisystemic failure with positive patch-test reaction to spironolactone: DRESS syndrome. *Acta Derm Venereol* 2004;84:65-8.

Alonso JC, Ortega FJ, Gonzalo MJ, et al. Cutaneous reaction to oral spironolactone with positive patch test. *Contact Dermatitis* 2002;47:178-9.

Corazza M, Strumia R, Lombardi AR, et al. Allergic contact dermatitis from spironolactone. *Contact Dermatitis* 1996;35:365-6.

Greenberger PA, Lazar HP. Readministration of spironolactone in the spironolactone-intolerant patient. *N Engl J Med* 1986;7:343-5.

Statins

Hydroxy-methyl glutaryl coenzyme A (HMG-CoA) reductase inhibitors have become the most prescribed cholesterol lowering drugs: lovastatin, pravastatin, simvastatin.

I Incidence

Hypersensitivity reactions: 0.1%.

I Clinical manifestations

- **General:** hypersensitivity syndrome: hypotension, angioedema, polymyalgia syndrome, myopathy, dermatomyositis, eosinophilia, elevated IgE levels.
- **Cutaneous:** pruritus, rash (eczematous, purpuric, petechial), urticaria, angioedema, acute generalized exanthematous pustulosis (rare), photosensitivity, lichenoid eruption, autoimmune diseases: lupus erythematosus (systemic, subacute), lichen planus-pemphigoides, dermatomyositis; linear IgA bullous dermatosis, toxic epidermal necrolysis (rare, one case with atorvastatin), acquired ichthyosis (rare), porphyria cutanea tarda (rare), cheilitis, alopecia.
- **Respiratory:** hypersensitivity pneumonitis, BOOP.
- **Others:** acute polyradiculoneuropathy.

I Diagnostic methods

Skin tests

Patch tests: no standardization.

Anti JO1 antibodies: 20 to 30% of patients with myositis, 50 to 100% of patients with interstitial lung disease associated myositis.

I Mechanisms

In some cutaneous reactions, decreased epidermal cholesterol synthesis leads to impairment of the cutaneous barrier function.

I Management

Avoidance.

References

Noel B. *Lupus erythematosus and other autoimmune diseases related to statin therapy: a systematic review.* *J Eur Acad Dermatol* 2007;21:17-24.

Kay J, Finn DS, Stone JR. *Case records of the Massachusetts General Hospital. Case 4-2006. A 79-year-old woman with myalgias, fatigue, and shortness of breath.* *N Engl J Med* 2006;354:623-30.

Hampson JP, Smith D, Cowell R, et al. Hypotension and eosinophilia with atorvastatin. *Pharm World Sci* 2005;27:279-80.

Riboldi P, Gerosa M, Meroni PL. Statins and autoimmune diseases. *Lupus* 2005;14:765-8.

Oskay T, Kutluay L. Acute generalized exanthematous pustulosis induced by simvastatin. *Clin Exp Dermatol* 2003;28:558-9.

Stoebner PE, Michot C, Ligeron C, et al. Simvastatin- induced lichen planus pemphigoides (Article in French). *Ann Dermatol Venereol* 2003;130:187-90.

Lantuejoul S, Brambilla E, Brambilla C, et al. Statin-induced fibrotic nonspecific interstitial pneumonia. *Eur Respir J* 2002;19:577-80.

Kenig C, Eickert A, Scharfetter-Kochanek K, et al. Linear IgA bullous dermatosis induced by atorvastatin. *J Am Acad Dermatol* 2001;44:689-92.

VI

DYES, PRESERVATIVES, ANTISEPTICS

Carboxymethylcellulose

Sodium carboxymethylcellulose is the sodium salt of a polycarboxymethyl ester of cellulose. It is used as a suspending agent to promote stabilization of compounds with poor water solubility (corticosteroids, LHRH, somatostatine).

■ Incidence

Infrequent.

Described with barium enema (differentiate from other ingredients: methylparaben, latex, carrageenan) and corticosteroids (cortivazol, prednisolone acetate, triamcinolone acetonide).

■ Risk factors

Female sex (OR 2.4).

Presence of high CMC IgE titers and significant CMC-induced histamine release with *in vitro* leukocyte preparations (Japanese study).

Parenteral administration.

■ Clinical manifestations

• **General:** anaphylactic shock.

• **Cutaneous:** pruritus, urticaria, angioedema, contact urticaria and contact dermatitis (hydrocolloid dressing).

• **Respiratory:** bronchospasm.

■ Diagnostic methods

Skin tests

Prick tests: 5 mg/ml.

Intradermal tests: 0.005 mg/ml to 0.05 mg/ml.

Open tests (10% in aq) and prick tests (0.1% in aq): positive in a case of contact urticaria.

Patch tests (10% concentration).

Specific IgE (ELISA): one study.

Sulfidoleukotriene release (CAST).

Leukocyte-histamine release: 2 cases.

■ Mechanisms

IgE-mediated hypersensitivity.

■ Management

Avoidance is extremely difficult due to the extensive use of carboxymethylcellulose in drugs and foods.

Patients with anaphylaxis to parenteral administration of CMC may tolerate small amounts by the oral route.

References

- Koo FP, Piletta-Zanin P, Politta-Sanchez S, et al. Allergic contact dermatitis to carboxymethyl cellulose in Comfeel* hydrocolloid dressing. *Contact Dermatitis* 2008;58:375-6.
- Rival- Tringani AL, Gunera-Saad N, Berard F, et al. Tolerability of oral administration of carboxymethylcellulose in two patients presenting anaphylactic reaction after carboxymethylcellulose injection (Article in French). *Ann Dermatol Venereol* 2008;135:402-6.
- Venturini M, Lobera T, del Pozo MD, et al. Immediate hypersensitivity to corticosteroids. *J Investig Allergol Clin Immunol* 2006;16:51-6.
- Moreau L, Alomer G, Dube N, et al. Contact urticaria from carboxymethylcellulose in white chalk. *Dermatitis* 2006;17:29-31.
- Mori S, Muroi N, Ono S, et al. Analysis of sensitisation to carboxymethylcellulose: identification of high risk group using ELISA and histamine release experiment. *Inflamm Res* 2004;53:164-9.
- Bigliardi PL, Izakovic J, Weber JM, et al. Anaphylaxis to the carbohydrate carboxymethylcellulose in parenteral corticosteroid preparations. *Dermatology* 2003;207:100-3.
- Muroi N, Nishibori M, Fujii T, et al. Anaphylaxis from the carboxymethylcellulose component of barium sulfate suspension. *N Engl J Med* 1997;337:1275-7.

Chlorhexidine

A biguanide antiseptic and disinfectant found in home products (mouthwash, toothpaste, plasters, dressings, ointment and suppositories), over-the-counter solutions for disinfection of minor cuts and wounds.

In the health services, used in swabs for disinfection. It is a standard skin disinfecting agent (e.g., in epidural anesthesia and surgical incisions).

■ Incidence

Fifty cases reported between 1967 and 1984:

Twenty-two with hypotension, 13 with dyspnea, 9 with anaphylactic shock, 4 with cyanosis.

■ Risk factors

Positive prick tests to chlorhexidine.

Previous reactions to chlorhexidine gluconate.

Male sex.

Urologic surgery or procedure.

■ Clinical manifestations

• **General:** anaphylactic shock (urinary catheterization, disinfection of a drain insertion site, topical application of a dressing on a burn, and placement of a central venous catheter).

• **Cutaneous:** pruritus, contact urticaria, contact dermatitis, photosensitive dermatitis, fixed drug eruption (case reports). Others: pigmentation (teeth, tongue), stomatitis, dysgueusia.

• **Respiratory:** bronchospasm, occupational asthma.

■ Diagnostic methods

Skin tests

Prick tests: chlorhexidine digluconate 0.5%

Intradermal tests: 0.02 ml at 0.0002%

Positive in anaphylaxis.

Patch tests 0.5% in aq (chlorhexidine digluconate) in contact dermatitis.

Specific IgE (IMMUNOCAP 100*).

Sulfidoleukotriene stimulation test (CAST*).

Histamine release test

Tryptase: elevated at the time of reaction

■ Mechanisms

IgE-mediated hypersensitivity.

The entire chlorhexidine molecule (symmetrical bis-guanide with p-chlorophenyl end-groups) could constitute the allergen.

Another possibility is that the chloguanide sites on both ends of the molecule could constitute allergenic sites.

■ Management

Avoidance in allergic patients.

Do not use chlorhexidine gluconate on mucosal surfaces.

Use at lowest bactericidal concentration (0.05%) on wound surfaces.

References

Garvey LH, Kroigaard M, Poulsen LK. IgE-mediated allergy to chlorhexidine. *J Allergy Clin Immunol* 2007;120:409-15.

Aalto-Korte K, Mäkinen-Kiljunen S. Symptoms of immediate chlorhexidine hypersensitivity in patients with a positive prick-test. *Contact Dermatitis* 2006;55:173-7.

Krautheim AB, Jermann TH, Bircher AJ. Chlorhexidine anaphylaxis: case report and review of the literature. *Contact Dermatitis* 2004;50:113-6.

Heinemann C, Sinaiko R, Maibach h. Immunological contact urticaria and anaphylaxis to chlorhexidine: overview (Article in French). *Exogenous Dermatol* 2002;1:1486-94.

Ebo DG, Stevens WJ, Bridts CH, et al. Contact allergic dermatitis and life-threatening anaphylaxis to chlorhexidine. *J Allergy Clin Immunol* 1998;101:128-9.

Chlorobutanol

A preservative with hypnotic, sedative, antiseptic and anesthetic properties used in many externally applied products as well as in drugs (vasopressin, heparin, oxytocin).

■ Incidence

Uncommon. One death reported.

■ Clinical manifestations

- **General:** anaphylactic shock.
- **Cutaneous:** pruritus, maculopapular eruption, ocular hypersensitivity.

■ Diagnostic methods

Skin tests

Intradermal tests using chlorobutanol at 0.5%. One positive result was reported in a patient with a maculopapular eruption.

One positive scratch test in a patient with anaphylactic shock.

Conjunctival provocation test.

Intravenous challenge with chlorobutanol was positive in a patient 5 minutes after 1 ml of 1/1000 chlorobutanol solution.

■ Mechanisms

Undetermined.

■ Management

Avoid use of drugs containing this preservative.

References

Garcia-Medina JJ, Garcia-Medina M, Zanon-Moreno VC, et al. Conjunctival provocation test for the diagnosis of ocular hypersensitivity to chlorobutanol. *Cornea* 2007;26:94-7.

Maycock EJ, Russell WC. Anaphylactoid reaction to Syntocinon*. *Anaesth Intensive Care* 1993;21:211-2.

Hofman H, Goerz G, Plewig G. Anaphylactic shock from chlorobutanol-preserved oxytocin. *Contact Dermatitis* 1986;15:241-2.

Slater RM, Bowles BJ, Pumphrey RS. Anaphylactoid reaction to oxytocin in pregnancy. *Anaesthesia* 1985;40:655-6.

Itabashi A, Katayama S, Yamaji T. Hypersensitivity to chlorobutanol in DDAVP solution. *Lancet*, 1982;1(8263):108.

Dux S, Pitlik S, Perry G, et al. Hypersensitivity reaction to chlorbutol-preserved heparin. *Lancet* 1981;1(8212):149.

Cremophor EL

A non-ionic surfactant (polyoxyethylated castor oil) used to dissolve water-insoluble drugs. Greater specific gravity than water, and high viscosity.

■ Incidence

Adverse reactions have been described with numerous drugs:

- Althesin* (alphaxalone), Epontol* (propanidid): withdrawn from the market,
- Diprivan* (propofol), Daktarin* (miconazole), Konaktion*(vitamin K1), Stesosid* MR (diazepam): reformulated without cremophor E.L.
- Sandimmune* (cyclosporine), Taxol* (paclitaxel), Vumon* (teniposide), Didemnin* B (didemnin B): currently in use.

■ Clinical manifestations

- **General:** anaphylactic shock.
- **Cutaneous:** urticaria, generalized erythema.
- **Respiratory:** bronchospasm.

■ Diagnostic methods

Skin tests

A few cases with positive intradermal tests with Cremophor 0.2 mg/ml to 20 mg/ml.

No specific IgE found.

■ Mechanisms

CARPA (complement activation-related pseudoallergy).

Activation of the complement system on the surface of lipid particles, leading to anaphylatoxin (C5a and C3a) liberation and subsequent release reactions of mast cells basophils and possibly other inflammatory cells in blood.

IgE-mediated hypersensitivity (few cases).

Non IgE-mediated hypersensitivity (IgG 4).

Non specific histamine release.

■ Management

Avoid use as excipient if possible.

In the case of intravenous cyclosporine: proper mixing during the preparation of the infusion and avoidance of polyvinylchlorure in the set-up. This could be extrapolated to other drugs containing cremophor EL.

Cremophor-free intravenous solutions for paclitaxel are under evaluation.

References

- Szebeni J, Alving CR, Rosivall L, et al. *Animal models of complement-mediated hypersensitivity reactions to liposomes and other lipid-based nanoparticles.* *J Liposome Res* 2007;17:107-17.
- Szebeni J. *Complement activation-related pseudoallergy: a new class of drug-induced acute immune toxicity.* *Toxicology* 2005;216:106-21.
- Szebeni J, Alving CR, Savay S, et al. *Formation of complement-activating particles in aqueous solutions of Taxol: possible role in hypersensitivity reactions.* *Int Immunopharmacol* 2001;1:721-35.
- Liau-Chu M, Theis JG, Koren G. *Mechanism of anaphylactoid reactions: improper preparation of high-dose intravenous cyclosporine leads to bolus infusion of Cremophor EL and cyclosporine.* *Ann Pharmacother* 1997;31:1287-91.
- Theis JG, Liau-Chu M, Chan HS, et al. *Anaphylactoid reactions in children receiving high-dose intravenous cyclosporine for reversal of tumor resistance: the causative role of improper dissolution of Cremophor EL.* *J Clin Oncol* 1995;13:2508-16.

Ethylene oxide

A potent alkylating compound of high chemical reactivity widely used for gas sterilization of biomedical devices that do not tolerate heat sterilization. It is extremely irritating in high concentrations.

■ Incidence

Severe but non-fatal reactions: 4.2/106 dialyzers sold.

■ Risk factors

Atopy.

Frequent exposure (spina bifida).

Use of cuprammonium cellulose dialyzers.

■ Clinical manifestations

- **General:** anaphylactic shock.
- **Cutaneous:** irritant contact dermatitis or burns, urticaria, angioedema, pruritus, rash, contact dermatitis, airborne contact dermatitis (suture material).
- **Respiratory:** bronchospasm.
- **ENT:** rhinitis.
- **Other:** local intra-articular reactions (reconstructive knee surgery); sterile shunt malfunction.

■ Diagnostic methods

Skin tests with ETO-HSA.

Prick tests: 1 mg/ml, then

Intradermal skin tests: 0.02 ml ETO-HSA 10 µg/ml; 100µg/ml; 1mg/ ml.

Positive predictive value: 80%.

Negative predictive value: 96%.

No standardized patch test. Some authors proposed to test epichlorohydrin (1% in pet) and epoxy propane (1% in pet), compounds with a similar epoxy chemical structure. Cross-reactions are possible. Provocation patch test with ETO sterilized biomaterial.

Specific IgE (ELISA, ImmunoCAP).

Correlation between ETO-specific IgE and allergic symptoms during dialysis.

Basophil activation.

I Mechanisms

IgE-mediated hypersensitivity.

Even in low concentrations ethylene oxide is able to alter native protein and potentially create neoantigens (hapten hypothesis: EtO conjugated to human serum albumin could act as an allergen).

I Management

Improved degassing techniques, rinsing new dialysers and tubing, replacing EtO by steam or gamma radiation to sterilize dialysers may help resolve this problem.

References

- Demontoux V, Moreau E, Peyron I, et al. Surgery in a patient allergic to ethylene oxide. *Pharm World Sci* 2008;30:208-9.
- Birnie AJ, English JSC. Ethylene oxide allergy may have been confirmed by patch testing to a similar epoxy compound. *Contact Dermatitis* 2006;55:126-8.
- Ebo DG, Bosmans JL, Couttenye MM, et al. Haemodialysis-associated anaphylactic and anaphylactoid reactions. *Allergy* 2006;61:211-20.
- Caroli UM, Berner D, Volz T, et al. Delayed-type hypersensitivity dermatitis to ethylene oxide. *Contact Dermatitis* 2005;53:303-4.
- Dagregorio G, Guillet G. Allergic suture material contact dermatitis induced by ethylene oxide. *Allergy* 2004;59:1239.
- Kraske GK, Shinaberger JH, Klaustermeyer WB. Severe hypersensitivity reaction during hemodialysis. *Ann Allergy Asthma Immunol* 1997;78:217-20.
- Purello D'Ambrosio F, Savica V, Gangemi S, et al. Ethylene oxide allergy in dialysis patients. *Nephrol Dial Transplant* 1997;12:1461-3.
- Pittman T, Kiburz J, Steinhardt G, et al. Ethylene oxide allergy in children with spina bifida. *J Allergy Clin Immunol* 1995;96:486-8.

Ethylenediamine

Ethylenediamine is used as a binding agent (creams, eye drops, aminophylline, enema) conferring greater solubility and reducing the alkalinity of the drug. Aminophylline is a complex of 2 theophylline molecules to one ethylenediamine molecule.

■ Incidence

Ethylenediamine sensitivity: 13% in patients with contact dermatitis.

■ Risk factors

Rapid or intermediate acetylors for immediate reactions.

■ Clinical manifestations

(allergic reaction may occur with intravenous aminophylline and oral formulations or suppositories).

Manifestations usually appear 24 to 48 hours after intake of the drug, but delays of 6 to 8 hours have also been reported.

- **General:** anaphylactic shock, fever, headache, myalgia.
- **Cutaneous:** pruritus, urticaria (sometimes airborne), maculopapular and urticaria eruption, angioedema, exanthem, erythema multiforme like eruption, periorbital edema, exfoliative dermatitis, erythroderma, contact dermatitis (occupational in pharmacists), systemic allergic contact dermatitis (oral aminophylline), Baboon syndrome.
- **Respiratory:** bronchospasm, occupational asthma in exposed subjects to ethylenediamine vapors.

■ Diagnostic methods

Skin tests

Intradermal skin-tests: aminophylline 1%, ethylenediamine 0.1% and 1%.

Patch-tests: aminophylline 1% pet. , ethylenediamine (dihydrochloride) 1% pet.

No specific IgE found.

Specific histamine-release positive in one case.

Controlled challenge IV.

■ Mechanisms

Possible IgE-mediated hypersensitivity in few cases.

Type IV cellular reaction. Sensitization to ethylenediamine is particularly common with topical drugs.

Acetylation is one of the major metabolic pathways for ethylenediamine.

I Management

Ethylenediamine-sensitive patients can develop allergy to piperazine (antihelminthic agent); to piperazine group antihistamines (hydroxyzine, cetirizine, levocetirizine); to triethanolamine containing creams and to ethylenediamine local antihistamines (tripelennamine hydrochloride, antazoline phosphate).

Use an ethylenediamine-free theophylline (diprophylline).

References

- Cusano F, Ferrara G, Crisman G, et al, *Clinicopathologic features of systemic contact dermatitis from ethylenediamine in cetirizine and levocetirizine*, *Dermatology*. 2006;213: 353-5
- Walker SL, Ferguson JE, *Systemic allergic contact dermatitis due to ethylenediamine following administration of oral aminophylline*, *Br. J. Dermatol.* 2004;150(3):594
- Asakawa H, Araki T, Yamamoto N, et al, *Allergy to ethylenediamine and steroid*, *J. Investig. Allergol. Clin. Immunol.* 2000;10(6):372-4
- Guin JD, Fields P, Thomas KL, *Baboon syndrome from i.v. aminophylline in a patient allergic to ethylenediamine*, *Contact. Dermatitis*. 1999;40(3):170-1
- Urbani C.E, *Urticarial reaction to ethylenediamine in aminophylline following mesotherapy*, *Contact. Dermatitis*, 1994;31(3):198-9

Formaldehyde

A low molecular weight organic chemical with numerous industrial applications (plastic, rubber, resins, coatings, adhesives). Also used as a disinfecting, preserving and embalming agent.

Aside from occupational exposure, anaphylaxis from formaldehyde can occur in association with haemodialysis and dental orthodontic treatment (dental root canal compounds).

■ Incidence

Thirty five cases of general allergic reactions to formaldehyde in dentistry. Contact dermatitis is frequent.

■ Risk factors

Previous exposure to formaldehyde.

■ Clinical manifestations

Differentiate from irritation syndrome (ocular, nasal, bronchial).

- **General:** anaphylactic shock.
- **Cutaneous:** urticaria (contact, generalized), urticarial vasculitis (rare), angioedema, contact dermatitis, erythema multiforme (rare).
- **Respiratory:** bronchospasm, rhinitis.

■ Diagnostic methods

Skin tests

Prick tests using formaldehyde solutions at 0.1 and 1% are inconsistently positive in subjects presenting immediate reactions. Results should be read immediately (20 minutes).

Patch tests: formaldehyde 1% in aq. False negative as well as false positive (irritant reaction) may occur.

Specific IgE antibodies against formaldehyde can often be detected by ImmunoCAP and RIA in subjects with immediate manifestations.

■ Mechanisms

IgE-mediated hypersensitivity (anaphylactic shock).

Cell-mediated hypersensitivity (contact dermatitis).

Type III hypersensitivity: IgG antibodies against formaldehyde/serum albumin conjugates have been detected in patients exposed through the respiratory or parenteral route.

■ Management

Avoid using dialysis membranes sterilized with formaldehyde in patients with previous allergic skin reactions to formaldehyde.

Perform an intradermal test with antihepatitis B vaccine in patients presenting contact dermatitis to formaldehyde (risk of generalized urticaria or eczema).
Use of sodium hypochlorite 3% for disinfection and obturation with gutta percha and/or cement or sealants without formaldehyde.
Avoiding apical extrusion or sealants can also be proposed.

References

- Jacob SE, Stechschulte SA. Tosylamide-formaldehyde resin allergy-a consideration in the atopic toddler. *Contact Dermatitis* 2008;58:312-3.
- Pellizzari M, Marshman G. Formaldehyde-induced urticarial vasculitis. *Australas J Dermatol* 2007;48:174-8.
- Lim SW, Smith W, Gillis D, et al. IgE-mediated allergy to formaldehyde from topical application. *Contact Dermatitis* 2006;54:230.
- Braun JJ, Zana H, Purohit A, et al. Anaphylactic reactions to formaldehyde in root canal sealant after endodontic treatment: four cases of anaphylactic shock and three of generalized urticaria. *Allergy* 2003;58:1210-5.
- Modre B, Kränke B. Anaphylactic reaction to formaldehyde. *Allergy* 2001;56:263-4.
- Wantke F, Hemmer W, Haglmüller T, et al. Anaphylaxis after dental treatment with a formaldehyde-containing tooth-filling material. *Allergy* 1995;50:274-6.
- Bousquet J, Michel F.B. Allergy to formaldehyde and ethyleneoxide. *Clin Rev Allergy* 1991;9:357-70.
- Bardana EJ Jr, Montanaro A. Formaldehyde: an analysis of its respiratory, cutaneous and immunologic effects. *Ann Allergy* 1991;66:441-52.
- Maurice F, Rivory JP, Larsson P, et al. Anaphylactic shock caused by formaldehyde in a patient undergoing long term hemodialysis. *J Allergy Clin Immunol* 1986;77:594-7.

Mercurochrome

Mercurochrome (MCCH) is a 2% solution of merbromin (disodic salt of dibromohydroxymercuryfluorescein) is an organic mercurial antiseptic used worldwide.

■ Incidence

Systemic reactions are uncommon. Delayed cutaneous reactions are more frequent.

■ Clinical manifestations

- **General:** anaphylactic shock.
- **Cutaneous:** pruritus, urticaria, angioedema, localized eczema, generalized eczema, DRESS syndrome, AGEP, Baboon syndrome.
- **Respiratory:** dyspnea, wheezing.

■ Diagnostic methods

Skin tests

Prick tests 2% MCCH

Immediate and delayed (24H)

Patch tests 2% aq. MCCH

No specific IgE found.

■ Mechanisms

IgE-mediated hypersensitivity.

T cell-mediated hypersensitivity.

■ Management

Cross-reactivity among organic and inorganic mercury compounds may occur but is not constant for all of them perform patch-tests (thimerosal 0.1% in pet, phenylmercuric acetate 0.01% aq, phenylmercuric nitrate 0.01% aq, metallic mercury 0.5% in pet and mercuric chloride 1% aq).⁷

References

- Lerch M, Bircher AJ. Systemically induced allergic exanthem from mercury. *Contact Dermatitis* 2004;50:349-53.
- Tschanz C, Prins C. Drug rash with eosinophilia and systemic symptoms caused by topical application of mercury. *Dermatology* 2000;201:381-2.
- Galindo PA, Feo F, Garcia R, et al. Mercurochrome allergy. Immediate and delayed hypersensitivity. *Allergy* 1997;52:1138-41.
- S. Rietschel. Ocular inflammation in patients using soft contact lenses. *Arch Dermatol* 1982;118:147-8.

Ortho-Phtalaldehyde

High level disinfectant commonly used for processing heat-sensitive medial devices.

I Incidence

Unknown.

I Clinical manifestations (laryngoscopy, cytoscopy)

- **General:** anaphylactic shock
- **Cutaneous:** contact urticaria (occupational).
- **Respiratory:** bronchospasm (occupational).

I Diagnostic methods

Skin tests

Positive in 4 patients with OPA (immediate and late).

Specific IgE (ELISA).

Basophil histamine release test.

I Mechanisms

IgE mediated hypersensitivity.

I Management

Avoidance.

To prevent health hazards from OPA exposure in health care workers, wearing of a personal protector and use of a fully automated washing machine with a local air exhauster are required.

References

Suzukawa M, Komiya A, Koketsu R, et al, Three cases of ortho-phthalaldehyde-induced anaphylaxis after laryngoscopy : detection of specific IgE in serum, *Allergol. Int.* 2007;56(3):313-6

Fujita H, Sawada Y, Ogawa M, et al. Health hazards from exposure to ortho-phthalaldehyde, a disinfectant for endoscopes, and preventive measures for health care workers (Article in Japanese). *Sangyo. Eiseigaku. Zasshi.* 2007;49(1):1-8.

Fujita H, Ogawa M, Endo Y, A case of occupational bronchial asthma and contact dermatitis caused by ortho-phthalaldehyde exposure in medical worker, *J. Occup. Health.* 2006;48:413-6

Franchi A, Franco G, Evidence-based decision making in an endoscopy nurse with respiratory symptoms exposed to the new ortho-phthalaldehyde (OPA) disinfectant, *Occup. Med.* 2005;55(7):575-8

Sokol WN, Nine episodes of anaphylaxis following cystoscopy caused by Cidex OPA (ortho-phthalaldehyde) high-level disinfectant in 4 patients after cystoscopy, *J. Allergy. Clin. Immunol.* 2004;114(2):392-7

Parabens

These methyl, ethyl, propyl, and butyl esters of hydroxybenzoic acid have bacteriostatic and fungicide properties and are the most widely used preservatives in food, cosmetics and medications (more than 300 pharmaceutical categories).

■ Incidence

0.8% of chronic dermatitis (skin tests).
3% of delayed cutaneous manifestations.
0.9% of drug allergies.

■ Risk factors

Damaged skin (leg ulcer, stasis dermatitis).

Previous sensitization by substances with a para-amine function.

Localization on the face or the neck.

■ Clinical manifestations

After topical use: contact dermatitis, contact urticaria. "Paraben paradox": safe use in cosmetics, sensitization in topical drugs (role of normal or damaged skin).

After systemic administration:

- **Cutaneous:** pruritus, urticaria, angioedema, systemic contact dermatitis after systemic administration in patients with previous contact sensitization, reactivation of positive patch-tests.
- **Respiratory:** dyspnea, bronchospasm, worsening of ongoing asthma.

■ Diagnostic methods

Skin tests

Intradermal skin-tests should be performed with a 5% concentration of methylparaben, ethylparaben, propylparaben, and butylparaben in order to avoid false negatives. A few positive results have been reported in patients with immediate reactions.

Patch-tests: paraben mix (methyl - 4 - hydroxybenzoate, ethyl - 4 - hydroxybenzoate, propyl - 4 - hydroxybenzoate, butyl - 4 - hydroxybenzoate) : 16% in pet. This concentration is near the irritancy threshold. Weak positive tests must be interpreted with caution.

Patch-tests isolated: 3% in pet for each component.

Patch-tests with the cosmetic or topical medicine suspected.

Use test on eczematized skin.

■ Mechanisms

IgE-mediated hypersensitivity in a few cases.

Cell-mediated hypersensitivity is responsible for contact dermatitis.

Cross-sensitivity may occur between parabens and molecules possessing a free amine group in the para position (benzocaine, para-phenylenediamine and sulfonamides). The only difference between such products and parabens is the presence of a hydroxy instead of an amine group in the para position. Cross reactivity between p. amine and p. hydroxyl compounds has been documented.

I Management

Avoidance is difficult.

References

- Sagara R, Nakada T, Iijima M. Paraben allergic contact dermatitis in a patient with livedo reticularis, *Contact. Dermatitis.* 2008;58:53-4
- Sanchez-Perez J, Ballesteros Diez M, Alonso Perez A, et al. Allergic and systemic contact dermatitis to methylparaben, *Contact. Dermatitis.* 2006;54:117-28
- Le Coz CJ. Allergy to parahydroxybenzoic acid esters (parahydroxybenzoates or parabens)- (Article in French). *Ann Dermatol Venereol* 2004;131:309-10.
- Sasseville D. Hypersensitivity to preservatives, *Dermatol. Ther.* 2004;17:251-63
- Mowad CM. Allergic contact dermatitis caused by parabens: 2 case reports and a review, *Am. J. Contact. Dermat.* 2000;11:53-6

Polysorbate 80

Polyoxyethylene-sorbitan-20-monooleate (also known as polysorbate 80 and Tween 80) is a solubilizing agent used in nutritives, creams, ointments, lotions and multiple medical preparations (vitamin oils, vaccines, anticancer agents, erythropoietin, darbopoietin) and as an additive in tablets.

■ Clinical manifestations

- **General:** anaphylactic shock.
- **Cutaneous:** urticaria, contact dermatitis.

■ Diagnostic methods

Skin tests

Prick tests: usually negative

Intradermal tests: positive in one patient

Patch test, 5% in pet: positive in contact dermatitis.

Specific IgE (immunoblotting and ELISA): negative.

Flow cytometric detection of basophil activation: negative.

■ Mechanisms

Probably non-immunologic.

■ Management

Avoidance.

References

Price KS, Hamilton RG. Anaphylactoid reactions in two patients after omalizumab administration after successful long-term therapy. *Allergy Asthma Proc* 2007;28:313-9.

Coors EA, Seybold H, Merk HF, et al. Polysorbate 80 in medical products and non-immunologic anaphylactoid reactions. *Ann Allergy Asthma Immunol* 2005;95:593-9.

Povidone / Povidone iodine

Povidone or polyvinyl pyrrolidone is a polymer with a molecular weight ranging from 10000 to 700000, comparable to plasma proteins and used as excipient in topical, oral, and parenteral pharmaceutical products.

■ Incidence

Rare.

■ Clinical manifestations

- **General:** anaphylactic shock.
- **Cutaneous:** urticaria, contact dermatitis. With povidone iodine : irritant contact dermatitis may be severe; ulcerations and caustic reaction, toxic epidermal necrolysis like lesions, vasculitis like lesions, allergic contact dermatitis (less frequent).
- **Respiratory:** asthma (hair spray).
- **Ocular:** conjunctivitis (intraocular lenses).
- **E.N.T:** rhinorrhea.

■ Diagnostic methods

Skin tests

Prick tests (Povidone, Betadine*).

Intradermal tests + 1/10000 (10µg/ml).

Patch-tests : povidone iodine 10% and 1% in aq ; Careful interpretation (irritation).

Repeated open application tests (ROAT) may be more appropriated.

Basophil activation test.

Leukotriene release test.

Provocation challenge.

■ Mechanisms

Non specific histamine release.

IgE-mediated hypersensitivity.

Povidone 10 has been shown to be a potent activator of suppressor T-cells, whereas povidone 40

and 60 are able to activate B-cells.

I Management

Avoidance.

References

Pedrosa C, Costa H, Oliveira G, et al, Anaphylaxis to povidone in a child, Pediatr. Allergy. Immunol 2005;16: 361-2

Lachapelle JM. Allergic contact dermatitis from povidone-iodine: a re-evaluation study (Article in French). Contact Dermatitis 2005;52:9-10.

Vernassiere C, Trechot P, Commun N, et al, Low negative predictive value of skin tests in investigating delayed reactions to radio-contrast media, Contact. Dermatitis. 2004;50:359-66

Le Pabic F, Sainte-Laudy J, Blanchard N, et al, First case of anaphylaxis to iodinated povidone, Allergy 2003;58:826-7

Gonzalo-Garijo M.A, Duran-Quintana J.A, Bobadilla-Gonzalez P, et al, Anaphylactic shock following povidone, Ann. Pharmacother., 1996;30(1):37-40

Sulfites (E 220 to 227)

Sulfites are used in the pharmaceutical and food industry for their antioxidizing and antibacterial properties. SO₂: sulfurous anhydride. Na₂SO₃: sodium sulfite. NaHSO₃: sodium bisulfite. Na₂S₂O₅: sodium metabisulfite. K₂S₂O₅: potassium metabisulfite.

■ Incidence

< 2% in the general population.

4.8 to 13.6% of all asthmatics have sulfite sensitive asthmatic symptoms.

1.7 to 6.8 % of positive sodium metabisulfite patch-tests in patients with eczematous dermatitis.

The majority of sulfite reactions are dietary; 3% of total reactions are attributed to drugs.

■ Risk factors

Aspirin intolerance?

Steroid dependent asthma.

■ Clinical manifestations

(reported with: novocaine, lidocaine, gentamicin, metoclopramide, vitamin B injection preparations, doxycycline...)

- **General:** anaphylactic shock.
- **Cutaneous:** urticaria, angioedema, contact dermatitis (face, eyes, eyelid, periorbital, lips and perioral, perianal, vulva, scalp), Burning-Mouth syndrome.
- **Respiratory:** bronchospasm, occupational asthma, laryngeal edema.
- **Others:** chronic cholestatic liver disease.

Mode of exposure

Food: preservative in dried food (e.g. fish), bleaching agent in codfish filets, dried fruits, fresh grapes, candies, vegetables, shrimps, wine, beer, cider, fruit and vegetable juice.

Drug: at least 1000 sulfite-containing drugs in USA (aminoglycosides, local anesthetics with epinephrine, corticosteroids, antifungal creams).

Cosmetics (hair colours and bleaches, skin fading/lighteners, false tan lotion, antiaging cream and moisturizers, facial cleansers, around-eye cream, body washes/cleansers, hair sprays, perfumes, blush, bronzers/highlighters).

■ Diagnostic methods

Skin tests

Prick tests (1 to 10 mg/ml), intradermal skin-tests (5 mg/ml), delayed skin-tests with sulfite solution 2% are usually negative.

Patch-tests with sodium metabisulfite 1% in petrolatum are used in the diagnosis of contact allergy. A positive patch test is not always relevant.

Challenge tests.

- Oral challenge tests: 5,10,25,50,100 mg dissolved in 20 ml of 0.5% citric acid positive in 20% of steroid-dependent asthmatic children.
- Inhalation challenge tests.
- Subcutaneous challenge tests (do not exceed 10 mg): not always positive in sulfite-sensitive individuals.

I Mechanisms

Several hypotheses:

- IgE-mediated hypersensitivity (positive skin-tests, positive transfer-tests, no specific IgE found)
- Inhalation of sulfur dioxide (bronchoconstriction)
- Direct nervous stimulation by SO₂
- Direct membrane toxicity
- Sulfite oxidase deficiency
- Delayed contact sensitivity in contact eczema.

I Management

Cyanocobalamin is effective in preventing clinical sulfite reactions.

Avoid use:

- Foods: easy if the presence of sulfites is indicated on the package label. If not, a detection band can be used, but false negative results are frequent
- Drugs: see the drug listing, or use detection band.

Use methoxamine, metaraminol or norepinephrine instead of adrenaline in sulfite sensitive subjects.

References

Madan V, Walker SL, Beck MH, Sodium metabisulfite allergy is common but is it relevant?, *Contact. Dermatitis.* 2007;57(3):173-6

Malik MM, Hegarty MA, Bourke JF, Sodium metabisulfite-a marker for cosmetic allergy?, *Contact. Dermatitis.* 2007;56:241-2

Breslin DS, Mc Brien ME, Management of severe anaphylactic reactions should include administration of alpha adrenergic agonists, *Anesth. Analg.* 2004;98:1499-500

Miltgen J, Marotel C, Natali F, et al. Clinical aspects and diagnosis of sulfite intolerance. A propos of 9 patients (Article in French). *Rev Pneum Clin* 1996;52(6):363-71.

Levanti C, Ricciardi L, Isola S, et al, Burning mouth syndrome: hypersensitivity to sodium metabisulfite, *Acta. Derm. Venereol.* 1996;76:158-9

Vena G.A, Foti C, Angelini G, Sulfite contact allergy, *Contact Dermatitis*, 1994;31(3):172-5

Lodi A, Chiarelli G, Mancini L.L, et al, Contact allergy to sodium sulfite contained in an antifungal preparation, *Contact Dermatitis*, 1993;29(2):97

Wüthrich B, Kägi MK, Hafner J, Disulfite-induced acute intermittent urticaria with vasculitis, *Dermatology.* 1993;187:290-2

Tartrazine (FD-C yellow n°5)

Tartrazine is an azo dye used in many foods and drugs including antibiotics, antihistamines, steroids, bronchodilators and antidepressants.

■ Incidence

Less than 0.12% in the general population.
3.8% in psychiatric patients.

■ Risk factors

Aspirin sensitivity (controversial).

■ Clinical manifestations

- **General:** anaphylactic shock.
- **Cutaneous:** urticaria (acute and chronic), angioedema, fixed drug eruption, contact dermatitis (rare), allergic vasculitis.
- **Respiratory:** bronchospasm.
- **E.N.T.:** rhinitis.

■ Diagnostic methods

The oral challenge with tartrazine is a only reliable method of accurate diagnosis:

Urticaria: tartrazine 1,5,25 and 50 mg at 30 minute intervals.

Asthma: tartrazine 0,1 mg to 50 mg at 30 minute intervals.

■ Mechanisms

Direct histamine release?

■ Management

Tartrazine free diet and avoidance of all drugs containing tartrazine. If symptoms improve, re-challenge with tartrazine. Reappearance of symptoms is sufficient proof of tartrazine hypersensitivity.

In obscure cases, perform oral challenge.

Routine tartrazine exclusion may not be beneficial for most asthmatic patients except those very few individuals with proven sensitivity.

References

- Elhkim MO, Héraud F, Bemrah N, et al, *New considerations regarding the risk assessment on tartrazine an update toxicological assessment, intolerance reactions and maximum theoretical daily intake in France*, *Regul. Toxicol. Pharmacol.* 2007;47(3):308-16
- Nettis E, Colanardi MC, Ferrannini A, et al, *Suspected tartrazine-induced acute urticaria/angioedema is only rarely reproducible by oral rechallenge*, *Clin. Exp. Allergy.* 2003;33(12):1725-9
- Ardern KD, Ram FS, *Tartrazine exclusion for allergic asthma*, *Cochrane. Database. Syst. Rev.* 2001;(4): CD000460
- Bathia MS, *Allergy to tartrazine in psychotropic drugs*, *J. Clin. Psychiatry.* 2000;61(7):473-6
- Kalinke DU, Wuthrich B, *Purpura pigmentosa progressiva in type III cryoglobulinemia and tartrazine intolerance. A follow-up over 20 years, (Article in German)*, *Hautarzt.* 1999;50:47-51
- Orchard D.C, Varigos G.A, *Fixed drug eruption to tartrazine*, *Austral. J. Dermatol.*, 1997;38(4):212-4

Thimerosal

Thimerosal or thiomersal, or merthiolate is an ethylmercury derivative used as an antiseptic and preservative in topical drugs, cosmetics and vaccines to prevent bacterial contamination.

Since 2002, all childhood vaccines used in Europe and USA are thiomersal free or contain only minute amounts of thiomersal.

Thiomersal is metabolized to ethylmercury ($\text{CH}_3\text{CH}_2\text{Hg}^{2+}$) and thiosalicylate.

■ Incidence

1 to 25% of positive patch-tests to thimerosal in patients with contact allergy.
10% of patients with positive patch-tests to thimerosal show adverse reactions to thimerosal containing vaccines.

■ Risk factors

Young adults (greater exposure to vaccines containing thimerosal?)

■ Clinical manifestations

- **General:** anaphylaxis is a theoretical risk and has not been proven to occur as a result of thimerosal in vaccines; flu-like syndrome, joint aches.
- **Cutaneous:** generalized urticaria, delayed generalized dermatitis, exacerbation of atopic dermatitis, persistent local reactions to vaccines, contact dermatitis, eyelid dermatitis, contact urticaria, conjunctivitis, Well's syndrome (exceptional).
- **Respiratory:** asthma (one case).
- **Others:** acute laryngeal obstruction (throat spray), prolonged external otitis (topical ear treatment).

■ Diagnostic methods

Skin tests

Patch-tests.

Thimerosal (merthiolate): 0.1% in pet (10 to 18% of false positives).

A positive patch test is a poor predictor of reaction to thimerosal containing vaccine.

■ Mechanisms

The ethylmercury radical appears to be the allergenic determinant.

The high frequency of patch-test reactions to thimerosal is due to sensitization by thimerosal containing vaccines.

There is a cross-reactivity between thiosalicylate and a degraded photoproduct of piroxicam (sensitization to thimerosal with photosensitivity to piroxicam).

I Management

Hypersensitivity to thimerosal does not imply true mercury allergy. A positive patch-test with thimerosal should often be regarded as an accidental finding with no clinical relevance.

A history of ocular sensitivity to thimerosal does not preclude hepatitis B vaccine administration.

Replace thimerosal in soft contact lenses care with sterile single-unit preservative-free saline with thermal disinfection or use special preservative-free care system containing only a low concentration (0.6%) of hydrogen peroxide.

References

- McMahon AW, Iskander JK, Haber P, et al, Inactivated influenza vaccine (IIV) in children < 2 years of age : examination of selected adverse events reported to the Vaccine Adverse Event Reporting System (VAERS) after thimerosal-free or thimerosal-containing vaccine, *VACCINE*. 2008;26:427-9
- National Advisory Committee on Immunization (NACI), Thimerosal : updated statement. An Advisory Committee Statement (ACS), *Can. Commun. Dis. Rep.* 2007;33(ACS-6):1-13
- Lee-Wong M, Resnick D, Chong K, A generalized reaction to thimerosal from an influenza vaccine, *Ann. Allergy. Asthma. Immunol.* 2005;94(1):90-4
- Hessel L, Mercury in vaccines, (Article in French), *Bull. Acad. Natl. Med.* 2003;187(8):1501-10
- Ball LK, Ball R, Pratt RD, An assessment of thimerosal use in childhood vaccines, *Pediatrics.* 2001;107(5): 1147-54
- Luka R.E, Oppenheimer J.J, Miller N, et al, Delayed hypersensitivity to thimerosal in Rho (D) immunoglobulin, *J. Allergy. Clin. Immunol.*, 1997;100(1):138-9
- Gonçalo M, Figueiredo A, Gonçalo S, Hypersensitivity to thimerosal: the sensitizing moiety, *Contact. Dermatitis*, 1996;34:201-3
- Cirne de Castro J.L, Freitas J.P, Menezes-Brandao F, et al, Sensitivity to thimerosal and photosensitivity to piroxicam, *Contact. Dermatitis*, 1991;24(3):187-92

VII

PRODUCTS USED IN DIALYSIS



Poly acrylonitrile AN 69 membrane

Haemodialysis is usually a safe procedure, but anaphylactoid reactions can sometimes be due to this membrane.

■ Incidence

Unknown.

■ Risk factors

Concomitant intake of ACE inhibitors or to a lesser extent angiotensin receptor antagonist therapy.

Clinical manifestations (onset within 20 minutes after starting dialysis)

Major signs: dyspnea, angioedema, burning/heat sensation at the access site or throughout the body.

Minor signs: urticaria, rhinorrhea, lacrimation, itching, abdominal cramps.

■ Diagnostic methods

No readily available assays to quantify bradykinin.

■ Mechanisms

Contact of plasma with negatively-charged AN 69 membranes initiates the contact phase of coagulation and leads to the activation of the Hageman factor and conversion of prekallikrein to kallikrein, which cleaves bradykinin from the high molecular weight kininogen.

Normally, kininogen is cleared almost completely by kininases during its passage in the pulmonary circulation. This does not occur in patients taking ACE inhibitors, leading to bradykinin accumulation and development of anaphylactoid reactions in such patients.

■ Management

Use alkaline rinsing solution (remains to be elucidated).

Use a surface-treated AN 69 ST* membrane, which does not lead to bradykinin release.

Replace the AN 69 membrane by another membrane (cellulosic or synthetic)

References

Ebo DG, Bosmans JL, Couttenye MM, et al. Haemodialysis-associated anaphylactic and anaphylactoid reactions. *Allergy* 2006;61:211-20.

Molinario G, Cugno M, Perez M, et al. Angiotensin-converting enzyme inhibitor-associated angioedema is characterized by a slower degradation of des-arginine (9)-bradykinin degradation of des-arginine (9)-bradykinin. *J Pharmacol Exp Ther* 2002;303:232-7.

Thomas M, Valette P, Mausset AL, et al. High molecular weight kininogen adsorption on hemodialysis membra-

nes: influence of pH and relationship with contact phase activation of blood plasma influence of pretreatment with polyethyleneimine. *Int J Artif Organs* 2000;23:20-6.

Tielemans C, Gastaldello K, Goldman M, et al. Acute hemodialysis membrane-associated reactions. *Nephrol Dial Transplant* 1996;11:112-5.

Verresen L, Fink E, Lemke H.D, et al. Bradykinin is a mediator of anaphylactoid reactions during hemodialysis with AN 69 membranes. *Kidney Int* 1994;45:1497-1503.

Iron

Parenteral supplementation of iron is required in some patients with iron deficiency (including those with oral iron intolerance), chronic uncorrected bleeding, malabsorption, gastrointestinal inflammatory disease, dialysis patients or failure to take prescribed oral iron.

Three intravenous iron preparations are currently in use: iron dextran, sodium ferric gluconate complex in sucrose and iron sucrose.

■ Incidence

Iron dextran: 29.2 reports/million 100 mg dose equivalent
1.4/million 100 mg dose equivalent fatal-event reporting rate.

Sodium ferric gluconate: 10.5 reports/million 100 mg dose equivalent
0.6/million 100 mg dose equivalent fatal-event reporting rate.

Iron sucrose: 4.2 reports/million 100 mg dose equivalent
0 fatal-event reporting rate.

■ Risk factors

Iron dextran: drug allergy (OR:2.4) multiple drug allergy (OR:5.5).

■ Clinical manifestations

- **General:** anaphylactic shock.
- **Cutaneous:** pruritus, urticaria, angioedema, flushing, serum sickness.
- **Respiratory:** bronchospasm.

■ Diagnostic methods

Tryptase levels elevated at the time of reaction.

■ Mechanisms

The dextran molecule rather than the iron moiety is thought to be the culprit.

■ Management

Do not use test dose.

Intravenous infusion of iron should not be faster than 12.5 mg/min.

Switch from iron dextran to sodium ferric gluconate (but iron dextran-sensitive patients have a seven-fold higher risk of reaction) or iron sucrose.

References

- Sane R, Baribeault D, Rosenberg CL. Safe administration of iron sucrose in a patient with a previous hypersensitivity reaction to ferric gluconate. *Pharmacotherapy* 2007;27:613-5.
- Bailie GR, Clark JA, Lane CE, et al. Hypersensitivity reactions and deaths associated with intravenous iron preparations. *Nephrol Dial Transplant* 2005;20:1443-9.
- Coyne DW, Adkinson NF, Nissenson AR, et al. Sodium ferric gluconate complex in hemodialysis patients. II. Adverse reactions in iron dextran-sensitive and dextran-tolerant patients. *Kidney Int* 2003;63:217-24.
- Michael B, Coyne DW, Fishbane S, et al. Sodium ferric gluconate complex in hemodialysis patients: adverse reactions compared to placebo and iron dextran. *Kidney Int* 2002;61:1830-9.
- Fishbane S, Ungureanu VD, Maesaka JK, et al. The safety of intravenous iron dextran in hemodialysis patients. *Am J Kidney Dis* 1996;28:529-34.
- Monaghan MS, Glasco G, St John G, et al. Safe administration of iron dextran to a patient who reacted to the test dose. *South Med J* 1994;87:1010-2.

Nafamostat Mesilate

6-amindino-2-naphthyl p-guanidino-benzoate dimethane sulfonate is a serine protease inhibitor used as an anticoagulant for haemodialysis mainly in Japan.

■ Incidence

Low.

■ Clinical manifestations

- **General:** anaphylactic shock.
- **Respiratory:** chest oppression.
- **Digestive:** abdominal pain, nausea, vomiting.

Diagnostic methods

Skin tests: one positive case.

Specific IgE (ELISA): one positive case.

Drug lymphocyte stimulation test.

■ Mechanisms

IgE-mediated hypersensitivity in some cases.

■ Management

Avoidance.

References

Yamazato M, Mano R, Oshiro-Chinen S, et al. Severe abdominal pain associated with allergic reaction to nafamostat mesilate in a chronic hemodialysis patient. *Internal Medicine* 2002;41:864-6.

Higuchi N, Yamazaki H, Kikuchi H, et al. Anaphylactoid reaction induced by a protease inhibitor, nafamostat mesilate, following nine administrations in a hemodialysis patient. *Nephron* 2000;86:400-1.

Okada H, Moriwaki K, Nakamoto H, et al. Positive skin reaction test in haemodialysis patients allergic to nafamostat mesilate. *Nephrol Dial Transplant* 1998;13:2166-7.

Maruyama H, Miyakawa Y, Gejyo F, et al. Anaphylactoid reaction induced by nafamostat mesilate in a hemodialysis patient. *Nephron* 1996;74:468-9.

VIII

DIAGNOSTIC AGENTS

Fluorescein

Intravenous fluorescein angiography is a useful and commonly performed ophtalmic procedure.

■ Incidence

Death: 1/222,000 procedures.

Mild reactions (nausea, vomiting, pruritus, sneezing, vasovagal disorders): 3 to 14% (m: 8%).

Urticaria: 0.5 to 1.2% (m: 1.06%).

Respiratory distress (bronchospasm, laryngospasm): 0.02 to 0.1%.

■ Risk factors

Diabetes (OR 1.8).

Arterial hypertension (OR 1.84).

Allergy history (OR 3.9).

Previous allergic reaction.

■ Clinical manifestations

- **General:** anaphylactic shock.
- **Cutaneous:** pruritus, urticaria, psoriasiform eruption.
- **Respiratory:** bronchospasm, laryngeal oedema.
- **Digestive:** nausea vomiting.
- **Neurological:** tonicoclonic seizure.

■ Diagnostic methods

Skin tests

Prick tests: 2 mg/ml

Intradermal tests: 200 µg/ml.

Tryptase.

Elevated beta-tryptase in a serum sample collected at the time of an adverse reaction indicates massive mast cell activation and anaphylactic shock.

■ Mechanisms

IgE mediated hypersensitivity.

Non-specific histamine release.

Vasovagal reactions.

Vasospastic toxic effect of an intravenous injection.

I Management

Premedication with antihistamines and corticosteroids may lessen the severity of reactions (nausea).

Desensitization in 1 to 2 days. For example: 0.1 ml 1/100 to 0.4 ml full strength (12 doses/3 hours).

Consider oral fluorescein angiography.

A positive prick test with 10% fluorescein solution could be useful for the prospective diagnosis of anaphylactic reactions to intravenous fluorescein administration.

References

Knowles SR, Weber EA, Berbrayer CS. Allergic reaction to fluorescein dye: successful one-day desensitization. *Can J Ophthalmol* 2007;42:329-30.

Lira RP, Oliveira CL, Marques MV, et al. Adverse reactions of fluorescein angiography: a prospective study. *Arq Bras Oftalmol* 2007;70:615-8.

Kwan AS, Barry C, McAllister IL, et al. Fluorescein angiography and adverse drug reactions revisited: the Lions Eye experience. *Clin Experiment Ophthalmol* 2006;34:33-8.

Mayama M, Hirayama K, Nakano H, et al. Psoriasiform drug eruption induced by fluorescein sodium used for fluorescein angiography. *Br J Dermatol* 1999;140:982-4.

Matsuura M, Ando F, Fukumoto K, et al. Usefulness of the prick-test for anaphylactoid reaction in intravenous fluorescein administration. *Nippon Ganka Gakkai Zasshi* 1996;100:313-7.

Rohr AS, Pappano JE Jr. Prophylaxis against fluorescein-induced anaphylactoid reactions. *J Allergy Clin Immunol* 1992;90:407-8.

Indigo carmine dye

Indigo carmine (sodium indigosulfonate) is a blue dye used by surgeons to identify and to examine the urinary tract.

■ Incidence

Very unusual.

■ Clinical manifestations

- **General:** anaphylactic shock, bradycardia, cardiac arrest.
- **Cutaneous:** urticaria.
- **Respiratory:** bronchospasm.

■ Mechanisms

Unknown.

■ Management

Avoidance

References

Yusim Y, Livingston D, Sidi A. Blue dyes, blue people: the systemic effects of blue dyes when administered via different routes. *J Clin Anesth* 2007;19:315-21.

Gousse AE, Safir MH, Madjar S, et al. Life-threatening anaphylactoid reaction associated with indigo carmine intravenous injection. *Urology* 2000;56:508.

Naitoh J, Fox BM. Severe hypotension, bronchospasm and urticaria from intravenous indigo carmine. *Urology* 1994;44:271-2.

Indocyanine green

This substance is used in the diagnosis and management of choroidal vasculature affections. Indocyanine green is a tricarboyanine organic dye with less than 5% of iodine (for stabilization).

■ Incidence

Mild adverse reactions: 0.15%

Moderate adverse reactions: 0.2%

Severe adverse reactions: 0.05%

One death reported during cardiac catheterization with indocyanine green.

■ Clinical manifestations

• **General:** anaphylactic shock.

• **Cutaneous:** pruritus.

• **Respiratory:** wheezing.

■ Diagnostic methods

None.

■ Mechanisms

Anaphylaxis may be related to the iodine additive or to the dye itself.

■ Management

Avoidance.

References

Olsen TW, Lim JI, Capone A Jr, et al. Anaphylactic shock following indocyanine green angiography (letter). *Arch Ophthalmol* 1996;114:97.

Hope-Ross M, Yannuzzi LA, Gradoudas ES. Adverse reactions due to indocyanine green. *Ophthalmology* 1994;101:529-33.

Obana A, Miki P, Hayashi K. Survey of complications of indocyanine green angiography in Japan. *Am J Ophthalmol* 1994;118:749-53.

Wolf S, Arend O, Schulte K, et al. Severe anaphylactic reaction after indocyanine green fluorescence angiography. *Am J Ophthalmol* 1992;114:638-9.

Benya R, Quintana J, Brundage B. Adverse reactions to indocyanine green. A case report and review of the literature. *Cathet Cardiovasc Diagn* 1989;17:231.

Iodinated contrast media

Iodinated radiographic contrast media are widely used. Reactions from intravascular injections are usually mild and self-treated. Radiographic contrast media are all triiodinated benzene derivatives and can be divided into 4 categories:

- **Ionic monomers** (highest osmotoxicity: ratio 1/5; highest carboxyl group toxicity)
iothalamate, ioxithalamate, amiditrizoate.
- **Ionic dimers** (lower osmotoxicity: ratio 1/3; lower carboxyl group toxicity)
ioxaglate.
- **Non-ionic monomers** (same osmotoxicity as ionic dimers; no carboxyl group toxicity).
iopromide, iopentol, iopamidol, iomeprol, ioxitol, iohexol, ioversol, iobitridol.
- **Non ionic dimers** (lowest osmotoxicity; no carboxyl group toxicity).
Iodixanol, iotrolan.

Incidence

Immediate reaction:

Itching/localized urticaria: Ionic contrast media: 6%
Non-ionic contrast media: 0.9%

High osmolarity contrast media (HOCM):

- Mild to moderate: 3.8% to 12.7%
- Severe: 0.1% to 0.4%

Low osmolarity contrast media (LOCM):

Mild to moderate: 0.7% to 3.1%

- Severe: 0.02% to 0.04%.
- Death: about 1/100,000

Delayed reactions: 0.9 to 2.9%

No significant association with immediate reactions, allergy, previous adverse reaction to contrast media.

May be overestimated due to false delayed adverse reactions resulting from clinical methodology (questionnaire).

Risk factors

- **Asthma** : OR 4.5

A patient with peak expiratory flow rate less than 400 l/min 10 minutes before injection runs a 3.8 times higher risk of developing an adverse reaction to intravascular injection of contrast media.

- **Drug allergy OR:** 1.3-3.2

relative risk of any reaction: 1.6 to 3

relative risk of severe reaction: 2.3 to 3.2

- **Previous contrast reaction OR:** 2-6

- **Atopy OR** : 1.6-3

- **Beta-adrenergic blockers OR:** 1-2.7

- **Female gender** is associated with greater risk of anaphylactoid reactions and severe anaphylactoid reactions OR:1-1.4
- **Cardiac diseases**
- **Seafood allergy or povidone-iodine allergy** are not risk factors
- Concomitant use of interleukin 2 increases incidence and severity of delayed reactions (fever, chills, rigors, flushing, dizziness, hypotension).

I Clinical manifestations

Differentiate from other cardiac or non-cardiac manifestations: vasovagal response, cardiogenic shock, myocardial infarction, cardiac tamponade, cardiac rupture, hypovolemia, sepsis or other drug intolerance.

Immediate reactions

Minor reactions

Pruritus, urticaria (limited), erythema; no treatment.

Moderate reactions

Urticaria (diffuse), angioedema, laryngeal edema, bronchospasm: treatment.

Severe reactions

Cardiovascular shock, respiratory arrest, cardiac arrest: hospitalization.

Differentiate from non-idiosyncratic manifestations: warmth, metallic taste in the mouth, nausea, vomiting, contrast-induced renal failure.

Delayed reactions (1 hour to 7 days): usually mild to moderate transient and self limiting.

Maculopapular rash (> 50% of cases)

Pruritus, erythema, urticaria, angioedema, facial flush, macular exanthema, rubella-like rash, scaling skin eruption, eczema, erythema multiforme (minor), fixed drug eruption, fixed drug eruption (sometimes with multiple lesions), recurrent flexural exanthema (SDRIFE or Baboon syndrome).

Few cases of severe skin reactions: Stevens-Johnson syndrome, toxic epidermal necrolysis and cutaneous vasculitis.

Occasionally: angioedema of the face combined with hypotension and/or dyspnea.

I Diagnostic methods

Immediate hypersensitivity reactions

During or immediately after the reaction

Plasma histamine: peak concentration immediately, elimination half-life:15-20 min. Blood samples must be obtained within the first 30 to 60 minutes.

Tryptase: peak concentration observed 15 to 30 min after the reaction ; elimination half-life in plasma 90 mn to 2 hours. Blood sampling 1 to 2 hr after onset of symptoms.

After recovery

Skin test: prick tests with undiluted contrast media. If negative, intradermal tests with 1/10,000 to 1/100 solution. Rarely positive and then only in patients with severe reactions. Cross-reactivity with other ICM may be observed in skin tests. No further reactions were seen in reactors administered an ICM after having negative skin tests.

Specific serum IgE antibodies: no commercial assay is available. The value of the tests in diagnosis of severe immediate reactions remains to be established, although some investigators have reported the presence of contrast media-specific IgE (2- 3% up to 47% of cases).

Basophil activation: the role of the histamine release test is not yet defined.

Non-immediate hypersensitivity reactions

During or immediately after the reaction

Sometimes liver or renal abnormalities

Flow cytometry (CD 25, CD 69, HLA-DR), enzyme immunoassay (soluble CD 25): research tools.

Skin biopsies: few typical features.

After recovery

Skin tests:

Undiluted prick tests with reading after 2 and 3 to 4 days, and intradermal tests with diluted contrast media and late readings after 1 to 3 days appear to be specific and useful in allergy diagnosis of delayed skin reactions.

Patch test : with pure injectable product

Lymphocyte transformation tests: occasionally used but not recommended for routine use.

I Mechanisms

Immediate reactions.

Histamine release by direct membrane effect of the osmolarity of the contrast media solution or the chemical structure of the contrast media molecule.

Histamine release by activation of the complement system.

Histamine release by an IgE mediated mechanism.

Delayed reactions.

T cell-mediated (positive patch tests and delayed intradermal tests).

Presence of dermal infiltrates of T cells.

Reappearance of the eruption after provocation testing.

I Management

Prevention of immediate reactions

Contrast medium selection

Use a low osmolar contrast media in patients with risk factors or previous contrast media induced immediate adverse reaction.

The safe readministration of a skin negative contrast media in patients with previous life threatening anaphylactic reactions has so far only been described in 5 patients.

Premedication

Severe contrast media-induced anaphylactic reactions have occurred in previous reactors despite prophylactic use of corticosteroids.

The role of premedication needs to be further established.

Prevention of delayed reactions

Contrast medium selection

Use of another contrast media if reexposure is required.

The administration of skin tests negative contrast media in previous reactors should be done with caution (reactions have been observed).

Premedication

Repeated non immediate reactions have been reported despite corticosteroid premedication. Another pretreatment was described with intramuscular 6 methylprednisolone and oral cyclosporine.

References

- Christiansen C. Hypersensitivity reactions to iodinated contrast media: an update. In Pichler WJ (ed): *Drug Hypersensitivity*, Basel, Karger, 2007, pp 233-241.
- Arnold AW, Hausermann P, Bach S, et al. Recurrent flexural exanthema (SDRIFE or Baboon syndrome) after administration of two different iodine radiocontrast media. *Dermatology* 2007;214:89-93.
- Brockow K, Christiansen C, Kanny G, et al. Management of hypersensitivity reactions to iodinated contrast media. *Allergy* 2005;60:150-8.
- Dewachter P, Trechot P, Mouton –Faivre C. Iodine allergy: point of view (Article in French). *Ann Fr Anesth Reanim* 2005;24:40-52.
- Kanny G, Pichler W, Morisset M, et al. T cell mediated reactions to iodinated contrast media: evaluation by skin and lymphocyte activation tests. *J Allergy Clin Immunol* 2005;115:179-85.
- Vernassiere C, Trechot P, Commun N, et al. Low negative predictive value of skin tests in investigating delayed reactions to radiocontrast media. *Contact Dermatitis* 2004;50:359-66.
- Moneret-Vautrin DA, Kanny G, Morisset M, et al. Anaphylactoid reactions and late skin reactions to iodinated contrast media: present state of the question—idea development. *Rev Med Int* 2001;22:969-77.
- Greenberger P.A, Patterson R. The prevention of immediate generalized reactions to radiocontrast media in high-risk patients. *J Allergy Clin Immunol* 1991;87:867-72.

Isosulfan blue

1% isosulfan blue dye and technecium 99-labeled sulfur colloid are used in lymphatic mapping (melanoma, breast cancer).

I Incidence

Global: 0.7% to 1.9%

Anaphylaxis: 1/100 to 1/1000.

I Risk factors

Sulfa allergy is not a risk factor.

I Clinical manifestations

- **General:** anaphylactic shock.
- **Cutaneous:** blue hives, urticaria, pruritus, generalized rash.
- **Respiratory:** hypoxemia.

I Diagnostic methods

Skin tests

Positive in 2 cases

CD 63 expression

I Mechanisms

IgE-mediated hypersensitivity.

I Management

Prophylaxis: methylprednisolone 20 mg or dexamethasone 4 mg, diphenhydramine 50 mg, famotidine 20 mg, intravenous just before injection reduces the severity but not the overall incidence.

Switch to methylene blue dye: less expensive, but severe reactions to it do occur (cutaneous and subcutaneous necrosis); cross-reactivity may exist.

References

Scherer K, Studer W, Figueiredo V, et al. Anaphylaxis to isosulfan blue and cross-reactivity to patent blue V: case report and review of the nomenclature of vital blue dyes. *Ann Allergy Asthma Immunol* 2006;96:497-500.

Wilke LG, Mc Call LM, Posther KE. Surgical complications associated with sentinel lymph node biopsy: results from a prospective international cooperative group trial. *Ann Surg Oncol* 2006;13:491-500.

Raut CP, Hunt KK, Akins JS. Incidence of anaphylactoid reactions to isosulfan blue dye during breast carcinoma lymphatic mapping in patients treated with preoperative prophylaxis: results of a surgical prospective clinical practice protocol. *Cancer* 2005;104:692-9.

Quiney NF, Kissin MW, Tytler I. Anaphylactic reaction to isosulphan blue. *Br J Anaesth* 2003;90:105-6.

Montgomery LL, Thorne AC, van Zee KJ, et al. Isosulfan blue dye reactions during sentinel lymph node mapping for breast cancer. *Anesth Analg* 2002;95:385-8.

Methylene blue

A dye currently used as a tracer for detecting digestive and urinary fistula, or as an alternative to isosulfan blue dye in sentinel lymph node biopsies.

■ Incidence

Very rare.

■ Clinical manifestations

- **General:** anaphylactic shock.
- **Cutaneous:** urticaria, ulcero-necrotic dermatitis, blue macules (sometimes painful).
- **Respiratory:** bronchospasm.

■ Diagnostic methods

Skin tests

Prick test: positive with methylene blue in one patient.

Plasma histamine elevated at the time of reaction

In vitro leukocyte histamine release: positive in one patient.

No relationship between allergic reactions and specific IgE or IgG titers.

■ Mechanisms

IgE mediated hypersensitivity.

■ Management

Avoidance.

References

Dewachter P, Mouton-Faivre C, Tréchet P, et al. Severe anaphylactic shock with methylene blue instillation. *Anesth Analg* 2005;101:149-50.

Rzymiski P, Wozniak J, Opala T, et al. Anaphylactic reaction to methylene blue dye after laparoscopic chromopertubation. *Int J Gynecol Obstet* 2003;81:71-2.

Trikha A, Mohan V, Kashyap L, et al. Pulmonary oedema following intrauterine methylene blue injection. *Acta Anaesthesiol Scand* 1996;40:382-4.

Paramagnetic contrast agents

Gadolinium chelates used as contrast agents for magnetic resonance imaging (MRI) are considered to be relatively safe.

Gadopentetate dimeglumine, gadoteridol, gadoterate meglumine, gadodiamide, gadobenate dimeglumine.

■ Incidence

Adults: 0.07%.

Children: 0.04%.

74% mild, 19% moderate, 7% severe.

All of the gadolinium chelates have the same incidence of severe anaphylactoid reactions. One fatality has been reported.

■ Risk factors

Asthma, allergy, previous reaction to MRI contrast agents, previous reaction to iodinated contrast agents.

■ Clinical manifestations

The most frequent reactions are mild non allergic (nausea, vomiting: 0.26% to 0.40%).

- **General:** anaphylactic shock.
- **Cutaneous:** pruritus, facial oedema, urticaria, maculopapular rash. Others: injection-site reactions (cutaneous nodules, pain, thrombophlebitis).
- **Respiratory:** bronchospasm, laryngospasm.
- **Others:** nephrogenic systemic fibrosis or fibrosing dermopathy (in patients with severe renal failure).

■ Diagnostic methods

Skin tests

Prick test: positive in one patient with gadoterate meglumine.

Intradermal tests (1/1,000, 1/100, 1/10): one case positive with gadoterate dimeglumine (1/100, 1/10); one case positive with gadoterate meglumine (1/1,000).

Tryptase

Elevated at the time of the reaction

Leukocyte histamine release test

One case positive with gadoterate meglumine.

I Mechanisms

IgE-mediated hypersensitivity in some cases

Although not yet fully understood, the same mechanisms as iodinated contrast agents might be involved.

I Management

Allergic-like reactions to gadolinium-containing contrast media can occur despite premedication with corticosteroids and antihistamines.

References

Dillman JR, Ellis JH, Cohan RH, et al. Allergic-like breakthrough reactions to gadolinium contrast agents after corticosteroid and antihistamine premedication. *Am J Roentgenol* 2008;19:187-90.

Dillman JR, Ellis JH, Cohan RH, et al. Frequency and severity of acute allergic-like reactions to gadolinium-containing i.v. contrast media in children and adults. *Am J Roentgenol* 2007;189:1533-8.

Kalogeromitros DC, Makris MP, Aggelides XS, et al. Anaphylaxis to gadiobenate dimeglumine (Multihance) a case report. *Int Arch Allergy Immunol* 2007;144:150-4.

Beaudouin E, Kanny G, Blanloeil Y, et al. Anaphylactic shock induced by gadoterate meglumine (DOTAREM *), a case report (Article in French). *Allerg Immunol* 2003;35:382-5.

Nelson KL, Gifford LM, Lauber-Huber C, et al. Clinical safety of gadopentetate dimeglumine. *Radiology* 1995;196:439-43.

Patent blue dye

Patent blue is an aniline dye (alphazurin 2 G) used as other blue dyes for lymphatic mapping in sentinel lymph node biopsy (breast cancer, melanoma).

■ Incidence

0.1 to 2.7% of lymphography procedures.

■ Risk factors

Exposure to tryphenylmethane dyes: textile industry, cosmetics, print shops, farms, pharmaceutical plants, food processing plants, plaque-disclosing agents in dentistry.

■ Clinical manifestations

- **General:** anaphylactic shock.
- **Cutaneous:** pruritus, urticaria (blue urticaria), angioedema, contact dermatitis.
- **Respiratory:** bronchospasm.

■ Diagnostic methods

Skin tests

In the course of routine preliminary testing:

0.14 to 3.5% of patients were positive to an intradermal skin test.

2.7% were positive to a prick-test.

0.3% were positive to a patch-test.

Scratch, prick (2.5% aqueous solution) and, especially, intradermal skin tests, using 1/100,000 up to 1/100 dilutions. Positive results are often observed in patients presenting immediate generalized reactions.

IgE antibodies have never been detected.

Histamine release from leukocytes incubated with patent blue.

Basophil activation (flow cytometry)

■ Mechanisms

Possible IgE-mediated hypersensitivity in some cases.

Non-specific histamine release.

Indirect histamine release with activation of the alternative complement pathway.

Cross-reactivity among blue dyes (isosulfan blue, methylene blue) is frequent.

Lymphatic mapping may be performed with radiocolloid (technetium-labelled nano colloidal albumin).

I Management

Predictive skin testing does not detect latent patent blue sensitivity in all cases.

References

Keller B, Yawalkar N, Pichler C, et al. Hypersensitivity reactions against patent blue during sentinel lymph node removal in three melanoma patients. *Am J Surg* 2007;193:122-4.

Scherer K, Studer W, Figueiredo V, et al. Anaphylaxis to isosulfan blue and cross-reactivity to patent blue V: case report and review of the nomenclature of vital blue dye. *Ann Allergy Asthma Immunol* 2006;96:497-500.

Cottineau C, Beydon L, Drouet M, et al. Allergic reaction to patent blue dye with positive detection of basophil activation by flow cytometry (Article in French). *Ann Fr Anesth Reanim* 2005;24:1406-7.

Belhaouari M, Marty MH, Sorbette F, et al. Reactions caused by "patent blue" observed in lymphography (Article in French). *Therapie* 1989;44:377-8.

Pevny I, Carl H. Allergy to dyes used in lymphangiography. *Contact Dermatitis* 1985;12:54-5.

IX

HORMONES AND ENZYMES

Aprotinin

A polyvalent proteinase inhibitor isolated from bovine lungs. Major application in cardiac surgery for the beneficial effect on perioperative blood loss and transfusion requirement. It may reduce the systemic inflammatory response after cardiopulmonary bypass and it has a stabilizing effect in biological tissue sealants.

■ Incidence

0.09% after first exposure.

1.5 to 2.8% in patients previously exposed to aprotinin.

0.5% (fibrin tissue adhesives).

■ Risk factors

Re-exposure less than 90 days after initial exposure (all severe reactions were in patients exposed within 6 months). The incidence of hypersensitivity reactions was 4.1%, 1.9% and 0.4% in less than 6 months, 6 to 12 months and more than 12 months reexposure.

Intolerance to beef meat, egg white, cheese and milk.

High levels of anti-aprotinin IgG.

■ Clinical manifestations

• **General:** anaphylactic shock.

• **Cutaneous:** pruritus, localized or generalized urticaria, exanthema.

• **Respiratory:** bronchospasm.

■ Diagnostic methods

Skin tests

Skin prick tests (1/100 to 1/10) then intradermal tests (1/1000): a few cases with positive skin tests after an allergic reaction.

Specific IgE and IgG (ELISA, IF)

After 48 months, 50% of all patients still show measurable levels of IgG anti-aprotinin.

IgE and IgG anti-aprotinin antibodies are found in 55% of patients with allergic reactions and 32% of non-reactors. Thus, the clinical value of this information is not clearly established.

■ Mechanisms

IgE-mediated hypersensitivity.

IgG-mediated hypersensitivity.

Non-specific histamine release.

■ Management

Careful evaluation of benefit-risk ratio.

Test dose is dangerous.

Premedication is ineffective.

Quantify antiaprotinin IgG before reexposure.

Use other pharmacological therapies (controversial): desmopressin, aminocaproic acid, tranexamic acid.

References

Dietrich W, Ebell A, Busley R, et al. Aprotinin and anaphylaxis: analysis of 12.403 exposures to aprotinin in cardiac surgery. *Ann Thorac Surg* 2007;84:1144-50.

Beierlein W, Scheule AM, Dietrich W, et al. Forty years of clinical aprotinin use: a review of 124 hypersensitivity reactions. *Ann Thorac Surg* 2005;79:741-8.

Dietrich W, Späth P, Zühlsdorf M, et al. Anaphylactic reactions to aprotinin reexposure in cardiac surgery: relation to antiaprotinin immunoglobulin G and E antibodies. *Anesthesiology* 2001;95:64-71.

Laxenaire MC, Dewachter P, Pecquet C. Allergic risk of aprotinin (Article in French). *Ann Fr Anest Reanim* 2000;19:96-104.

Dobkowski WB, Murkin JM. A risk-benefit assessment of aprotinin in cardiac surgical procedures. *Drug Saf* 1998;18:21-41.

Calcitonin

Calcitonin is a 32 amino acid polypeptide synthesized by the parafollicular cells of the thyroid. It inhibits bone resorption and increases urinary calcium and phosphorus output. Three types of calcitonin are used clinically, i.e., natural porcine, synthetic salmon and synthetic human calcitonin, for the treatment of Paget's disease, hypercalcemia, hyperparathyroidism, and osteoporosis.

■ Incidence

Uncommon.

■ Clinical manifestations

The more common side effects are flushing, nausea, vomiting, diarrhea, abdominal pain, erythema on the face and hands, and other local reactions.

- **General:** anaphylactic shock.
- **Cutaneous:** pruritus, rash, angioedema, urticaria. Others: disseminated granuloma annulare.
- **Respiratory:** bronchospasm.

■ Diagnostic methods

Skin tests

Prick tests:

Positive in one patient with commercial salmon calcitonin (50 UI/ml)

Positive in one patient with eel calcitonin (100 UI/ml)

Intradermal tests:

Positive in one patient (1/1000 and 1/100) with porcine calcitonin

Positive in one patient (1 UI/ml) with salmon calcitonin

Specific IgE: one case with specific IgE to porcine calcitonin (RIA)

Leukocyte histamine release: negative in one patient

Drug challenge: intranasal or intramuscular

■ Mechanisms

IgE-mediated hypersensitivity.

■ Management

Allergic reactions to calcitonin are rare and usually due to non-human calcitonins.

Subcutaneous administration is safer than intramuscular injections.

Cross-reactivity between calcitonins is not frequent.

References

Rodriguez A, Trujillo MJ, Herrero T, et al. *Allergy to calcitonin*. *Allergy* 2001;56:801.

Porcel SL, Cumplido JA, de la Hoz B, et al. *Anaphylaxis to calcitonin (Article in Spanish)*. *Allergol Immunopathol* 2000;28:243-5.

Piccone U, Pala M, Caprari M. *Calcitonin-induced anaphylactic shock. Case report and review of the literature (Article in Italian)*. *Minerva Cardioangiol* 1994;42:435-41.

Cuskey J, Dubois L, du Buske L. *Induction of urticaria and angioedema by synthetic salmon calcitonin*. *J Allergy Clin Immunol* 1991;87:A359.

Pirson F, Tafforeau M, Birnbaum J, et al. *Anaphylactic reaction to calcitonin (Article in French)*. *Rev Fr Allerg Immunol Clin* 1988;28:248-9.

Corticosteroids

Anti-inflammatory drugs widely used in various fields of medicine.

Allergic reactions have been reported with intramuscular, intraarticular, periarticular, intralesional, oral, inhalational and intravenous routes of administration.

■ Incidence

Hydrocortisone, prednisolone and methylprednisolone are the most frequently implicated in anaphylaxis.

About 100 published reports of immediate hypersensitivity reactions occurring after oral and parenteral administration.

■ Risk factors

Aspirin-sensitive patients (intravenous hydrocortisone).

■ Clinical manifestations

• **General:** anaphylactic shock.

• **Cutaneous:** immediate reactions: urticaria, angioedema.

Delayed hypersensitivity reactions: reactivation of eczema following oral, parenteral, intra-articular, intra-lesional administration of a corticosteroid. Maculopapular rash, papulo-vesicular rash, exanthematous rash, eczematous rash, annular and centrifugum eczema, flexural rash, rash with or without bullae or purpura, erythema multiforme, acute generalized exanthematous pustulosis.

• **Respiratory:** bronchospasm (hydrocortisone hemisuccinate and methylprednisolone).

■ Diagnostic methods

Skin tests

Corticosteroids:

• Prick tests:	Methylprednisolone succinate	40 mg/ml
	Hydrocortisone succinate	100 mg/ml
	Prednisolone succinate	10 to 30 mg/ml
	Betamethasone phosphate	4 to 6 mg/ml
	Dexamethasone phosphate	4 to 5 mg/ml
• Intradermal tests:	Methylprednisolone succinate	0.4 mg/ml
	Hydrocortisone succinate	1 mg/ml
	Prednisolone succinate	0.1 mg/ml
	Betamethasone phosphate	0.06 mg/ml
	Dexamethasone phosphate	0.05 mg/ml

Excipients:

Carboxymethylcellulose: prick tests: 5 mg/ml, intradermal tests: 0.005 mg and 0.05 mg/ml.

Tween 80: prick tests: 0.4 mg/ml, intradermal tests: 0.004 and 0.04 mg/ml.

Benzylalcohol: prick tests: 10 mg/ml, intradermal tests: 0.1 and 1 mg/ml.

Specific IgE: one case with methylprednisolone.

CD63-based basophil activation: one case with prednisolone succinate.

- **Patch test:** use standard series to detect corticosteroid allergy.

Budesonide: 0.01% in pet.

Betamethasone-17-valerate: 1% in pet.

Triamcinolone acetonide: 1% in pet.

Tixocortol -21 (pivalate): 0.1% in pet (or 1% in pet; no statistically significant difference between the two concentrations).

Alclomethasone-17, 21-dipropionate: 1% in pet.

Clobetasol-17- propionate: 1% in pet.

Dexamethasone-21-phosphate disodium salt: 1% in pet.

Hydrocortisone-17- butyrate: 1% in eth.

Patch tests may be read 48 hr and 72 hr or 96 hr after placement of tests but also on Day 7 or 10 (delayed reactions are frequent, so late reading is necessary).

- Others.

Betamethasone dipropionate: 1% in eth.

Amcinonide: 1% in eth.

Beclomethasone dipropionate: 1% in eth.

Clobetasone butyrate: 1% in eth.

Desonide: 0.1% in eth.

Desoximethasone: 1% in eth.

Fluprednidene acetate: 0.01% in eth.

Diflorasone diacetate: 1% in D/e (dimethyl sulphoxide/ethanol, 50/50).

Fluticasone propionate: 1% in D/e (dimethyl sulphoxide/ethanol, 50/50).

Fluocortolone: 1% in eth.

Fluocinolone acetonide: 1 in eth.

Hydrocortisone: 1% in D/e (dimethyl sulphoxide/ethanol, 50/50).

Methylprednisolone aceponate: 1% in eth.

Mometasone furoate: 0.01 % in eth.

Prednicarbate: 1% in eth.

Controlled challenge test:

Oral hydrocortisone: 5, 10, 15, 30 mg

Oral prednisolone: 5, 10, 15, 20 mg

Intravenous hydrocortisone: 5, 10, 20, 40, 75 mg

Intravenous prednisolone: 5, 10, 15, 30, 40 mg.

■ Mechanisms

IgE-mediated hypersensitivity.

Formation of steroid glyoxal, cortisol degradation product, which in aqueous solution may be responsible for the presentation of the steroid carbon rings to the immune system as a hapten.

The immunogenic role of succinate esters could be attributed to their greater solubility in water

and to their higher affinity to serum proteins.
Carboxymethyl cellulose is sometimes the culprit.

I Management

Avoidance of hydrocortisone, methylprednisolone and prednisolone in any formulation (succinate, acetate or sodium phosphate) in patients with allergic reactions to systemic corticosteroids.

Betamethasone, deflazacort and dexamethasone are possible alternatives.

Cross-reactivity has been reported between:

Methylprednisolone sodium succinate, methylprednisolone 21 sodium succinate and prednisolone 21 sodium succinate.

Paramethasone, betamethasone and methylprednisolone.

One case of hydrocortisone desensitization in a patient with radiocontrast induced-anaphylactoid reaction and corticosteroid allergy.

References

- Lehmann S, Ott H. Glucocorticoid hypersensitivity as a rare but potentially fatal side effect of paediatric asthma treatment: a case report. *J Med Case Rep* 2008;2:186.
- Rodrigues-Alves R, Spinola-Santos A, Pedro E, et al. Immediate hypersensitivity to corticosteroids: finding an alternative. *J Investig Allergol Clin Immunol* 2007;17:284-5.
- Venturini M, Lobera T, del Pozo MD, et al. Immediate hypersensitivity to corticosteroids. *J Investig Allergol Clin Immunol* 2006;16:51-6.
- Lee-Wong M, Mc Clelland S, Chong K, et al. A case of hydrocortisone desensitization in a patient with radiocontrast-induced anaphylactoid reaction and corticosteroid allergy. *Allergy Asthma Proc* 2006;27:265-8.
- Buettiker U, Kerller M, Pichler WJ, et al. Oral prednisolone induced acute generalized exanthematous pustulosis due to corticosteroids of a group A confirmed by epicutaneous testing and lymphocyte transformation tests. *Dermatology* 2006;213:40-3.
- Padial A, Posadas S, Alvarez J, et al. Non immediate reactions to systemic corticosteroids suggest an immunological mechanism. *Allergy* 2005;60:665-70.
- Cheam H, Butani L. Immunoglobulin E-mediated reactions to corticosteroids. *Curr Allergy Asthma Rep* 2005;5:22-7.
- Kilpio K, Hannuksela M. Corticosteroid allergy in asthma. *Allergy* 2003;58:1131-5.
- Butani L. Corticosteroid-induced hypersensitivity reactions. *Ann Allergy Asthma Immunol* 2002;89:439-45.
- Figueredo E, Cuesta-Herranz J, de Las Heras M, et al. Anaphylaxis to dexamethasone. *Allergy* 1997;52:877.

Glucagon

A naturally occurring polypeptide of 29 amino acids currently synthesized in special non-pathogenic *E. coli* genetically altered by the addition of the glucagon gene. Used for bowel relaxation during barium gastrointestinal studies and emergency treatment of hypoglycemia.

■ Incidence

Extremely uncommon.

■ Clinical manifestations

Periorbital oedema with respiratory distress (2 cases).

Dizziness and shortness of breath (1 case).

Urticaria, erythema multiforme, delayed hypersensitivity with papulous plaques and purpuric rash, pruritus, reproduction of features of the glucagonoma syndrome, injection-site reaction.

■ Diagnostic methods

None.

■ Mechanisms

Delayed hypersensitivity in some cases.

■ Management

Avoidance.

Use hyoscine butylbromide, pirenzepine, cimetropium bromide or peppermint oil mixed with barium suspension.

References

Neoh C, Tan AW, Leow YH. Delayed hypersensitivity reaction after intravenous glucagon administered for a barium enema: a case report. *Ann Acad Med Singapore* 2006;35:279-81.

Case CC, Vassilopoulou-Sellin R. Reproduction of features of the glucagonoma syndrome with continuous intravenous glucagon infusion as therapy for tumor-induced hypoglycemia. *Endocr Pract* 2003;9:22-5.

Herskovitz PI, Sendovski U. Severe allergic reaction to intravenous injection of glucagon. *Radiology* 1997;202:879.

Gelfand DW, Sowers JC, DePonte KA, et al. Anaphylactic and allergic reactions during double-contrast studies: is glucagon or barium suspension the allergen? *Am J Roentgenol* 1985;144:405-6.

Gonadotropin Releasing Hormone (GnRH analogues)

GnRH analogues are used in the treatment of prostatic carcinoma, endometriosis and precocious puberty.

Tripterolin, Gonadorelin, Buserelin, Leuprolide acetate, Nafarelin, Goserelin acetate.

■ Incidence

Local reactions: 0 to 13%.

General reactions are rare. Several reports of systemic hypersensitivity reactions associated with leuprolide acetate.

■ Risk factors

Route of administration (constant infusion > intermittent use).

Length of treatment.

■ Clinical manifestations

• **General:** anaphylactic shock.

• **Cutaneous:** hot flash (frequent), flush, pruritus, urticaria, angioedema, rash, vasculitis (rare; cases with triptorelin, leuprolide), edema (acral), injection-site reaction, local reaction with implant (leuprolide, histreline), frequent: bleeding, bruising, burning, pain, pruritus, edema, erythema; acne, seborrhea (frequent with nafarelin), vaginitis.

• **Respiratory:** sneeze, bronchospasm.

■ Diagnostic methods

Skin tests

Prick tests positive in various concentrations for gonadorelin, buserelin, goserelin, leuprolide.

Intradermal test: one positive case with leuprolide.

Specific IgE (RIA): a few cases published.

Specific IgG (RIA): controversial role.

MIF one positive case with triptorelin.

Skin-biopsy: one case of allergic vasculitis with triptorelin.

■ Mechanisms

IgE-mediated hypersensitivity (positive immediate skin tests, specific IgE).

Type III reaction (one case).

Non-specific histamine release.

I Management

Avoidance of all GnRHs.

References

Shiota M, Tokuda N, Kanou T, et al. Injection-site resulting from the administration of both leuprorelin acetate and goserelin acetate for the treatment of prostatic cancer. *J Nippon Med Sch* 2007;74:306-8.

Turk BG, Dereli T, Dereli D, et al. Leuprolide acetate-induced leukocytoclastic vasculitis. *Acta Obstet Gynecol Scand* 2007;86:892-3.

Grant JP Jr, Levinson AW. Anaphylaxis to leuprolide acetate depot injection during treatment for prostate cancer. *Clin Genitourin Cancer* 2007;5:284-6.

Lam C, Tjon J, Hamilton J, et al. Recurrent anaphylaxis associated with gonadotropin-releasing hormone analogs: case report and review of the literature. *Pharmacotherapy* 2006;26:1811-5.

Kono T, Ishii M, Taniguchi S. Intranasal buserelin acetate-induced pigmented roseola-like eruption. *Br J Dermatol* 2000;143:658-9.

Raj SG, Karadsheh AJ, Guillot RJ, et al. Case report: systemic hypersensitivity reaction to goserelin acetate. *Am J Med Sci* 1996;312:187-90.

Insulin

The prevalence of insulin allergy has considerably decreased since human recombinant insulins became available.

I Incidence

Uncommon in type 2 diabetes.

Non-purified insulin: 1 to 55%.

Highly purified human recombinant insulin 5 to 10% for local reactions, 0.1 to 2% for systemic reactions.

I Risk factors

HLA B₇ DR₂ DR₄.

Subcutaneous route.

I Clinical manifestations

I/ Local

Immediate (within minutes of injection): pain + itching accompanied by erythema and swelling < 1 hour.

Biphasic (immediate + late phase response): starting at 4 hours and persisting 1-3 days.

Intermediate (Arthus reaction): onset at 4-8 hours, peaks at 12 hours, induration with pruritus.

Delayed (tuberculin-like): onset at 12 hours, peaks at 24-48 hours, induration with erythema and pruritus.

II/ Systemic.

• **General:** anaphylactic shock, serum sickness, generalized lymphadenopathy, immunological insulin resistance.

• **Cutaneous:** local reactions: erythema, edema, urticaria, induration, pruritus, pain, lipodystrophy (atrophy or hypertrophy). Systemic reactions: pruritus, urticaria, angioedema, leukocytoclastic vasculitis (rare).

• **Respiratory:** bronchospasm.

I Diagnostic methods

Skin tests

Insulin

Prick test: pure insulin preparation 100 U/ml (low sensitivity).

Intradermal test: 0.02 ml of increasing dosages of commercial peptides ranging from 1/100.000 to 1/10 solution.

40% of patients without clinical allergy show positive immediate test to the insulin used for treatment (15% with highly purified preparations).

Protamine.

Prick tests: 10 mg/ml.

Intradermal tests: C < 10 µg/ml.

Metacresol.

Patch tests: sometimes positive.

Specific IgE

Insulin.

44% of patients treated with human recombinant insulin without any clinical symptoms develop anti-insulin IgE antibodies. High titers of IgE are frequently found in systemic insulin allergy.

Protamine.

50% of patients treated with protamine-containing insulin have protamine-specific IgE.

Specific IgG4

Positive in one case with glargine insulin allergy.

I Mechanisms

IgE-mediated hypersensitivity (local reactions: immediate or biphasic; general reactions: anaphylactic shock, urticaria).

Type III reactions (antigen-antibody initiated complement fixation, leukocyte attraction and inflammatory response): Arthus reaction, adenopathies, serum sickness, immunological insulin resistance).

Type IV reactions: rare.

Tertiary structural change before or during insulin injection, insulin self-aggregation promotes the formation of anti-insulin antibodies.

Cross-reactivity with animal insulins (in patients who had received them previously).

Route of administration (subcutaneous tissue is rich in mast cells).

Protamine, zinc (2 cases), parabens, metacresol, phenol, isophane are sometimes responsible for allergic reactions.

Insulin syringes and insulin vial stoppers containing latex may lead to allergic reactions to latex in diabetics.

Methylmethacrylate (plastic catheter of a pump infusion set).

I Management

I/ Local and mild symptoms.

Simple methods: dose division, variation of injection site, antihistamines, local corticosteroids.

Switch to a different insulin (with negative intradermal tests).

Lispro and aspart analogs are generally useful.

II/ Generalized reactions.

Frequent subcutaneous injection of small increasing doses of insulin: 1 U of 0.005 U/ml human regular insulin → 8 U of 50 U/ml in 15 steps, injections given at 30 minutes intervals.

In case of failure, more prolonged protocols or repeated desensitization can be proposed.

Type III or type IV allergies have been reported to be partially or totally refractory to this procedure. Failure to desensitize could indirectly indicate an immune complex disease, and Lispro has been efficient in this particular situation, since the formation of immune complexes might be profoundly affected.

Continuous subcutaneous insulin infusion therapy seems the ideal method for desensitization.

Omalizumab and pancreas transplantation have been successfully used in some cases.

In case of protamine allergy, use a protamine-free insulin preparation.

References

- Radermecker RP, Scheen AJ. Allergy reactions to insulin: effects of continuous subcutaneous insulin infusion and insulin analogues. *Diabetes Metab Res Rev* 2007;23:348-55.
- Rajpar SF, Foulds IS, Abdullah A, et al. Severe adverse cutaneous reaction to insulin due to cresol sensitivity. *Contact Dermatitis* 2006;55:119-20.
- Madero MF, Sastre J, Carnes J, et al. IgG(4)-mediated allergic reaction to glargine insulin. *Allergy* 2006;61:1022-3.
- Castera V, Dutour-Meyer A, Koeppl MC, et al. Systemic allergy to human insulin and its rapid and long acting analogs: successful treatment by continuous subcutaneous insulin lispro infusion. *Diabetes Metabolism* 2005;31:391-400.
- Matheu V, Perez E, Hernandez M, et al. Insulin allergy and resistance successfully treated by desensitisation with Aspart insulin. *Clin Mol Allergy* 2005;23:3-16.
- Bodtger U, Wittrup M. A rational clinical approach to suspected insulin allergy: status after five years and 22 cases. *Diabet Med* 2005;22:102-6.
- Messaad D, Outtas O, Demoly P. Hypersensitivity to insulin (Article in French). *Presse Med* 2004;33:361-8.
- Mandrup-Poulsen T, Molvig J, Pildal J, et al. Leukocytoclastic vasculitis induced by subcutaneous injection of human insulin in a patient with type I diabetes and essential thrombocytopenia. *Diabetes Care* 2002;25:242-3.
- Frigerio C, Aubry M, Gomez F, et al. Desensitization-resistant insulin allergy. *Allergy* 1997;52:238-9.
- Kumar D. Lispro analog for treatment of generalized allergy to human insulin. *Diabetes Care* 1997;20:1357-9.

Pseudoephedrine

Sympathomimetic agents which are widely used as vasoconstrictors in eye drops, ear drops, and topical preparations.

■ Incidence

Low.

■ Clinical manifestations

- **General:** anaphylactic shock.
- **Cutaneous:** urticaria, angioedema, acute generalized exanthematous pustulosis, toxic epidermal necrolysis, erythroderma, non-pigmented fixed drug reaction, systemic contact dermatitis, Baboon syndrome, pigmented purpuric dermatosis, erythema multiforme.
- **Ophthalmic:** conjunctivitis with eyelids eczema (eye drops)

■ Diagnostic methods

Skin tests

Prick tests: positive with pseudoephedrine and ephedrine (25 mg/ml) in one patient with anaphylaxis.

Patch tests: pseudoephedrine 10%, phenylephrine 10% in pet, ephedrine 10% and 20%, phenylpropanolamine 10%, fepradinol 5%, methoxanine 1% and oxymethazoline 10% in DMSO.

Often positive in patients with delayed symptoms.

Flare-up reaction with a positive patch test, so the 1% dilution is recommended to avoid this reaction.

Oral challenge test.

■ Mechanisms

IgE-mediated hypersensitivity is exceptional.

Delayed contact hypersensitivity is more frequent.

■ Management

Avoidance.

Cross-reactivity by patch test is frequent between the different sympathomimetic drugs, especially if the drug was administered systematically.

Cross-reactivity is more frequent between pseudoephedrine and ephedrine (phenylpropanolamine-derived) than between phenylephrine and epinephrine (phenylethanolamine-derived).

Sensitization to pseudoephedrine does not exclude the use of neosynephrine-containing eye drops

and the use of epinephrine-containing local anesthetics.

References

- Nagge JJ, Knowles SR, Juurlink DN, et al. Pseudoephedrine induced toxic epidermal necrolysis. *Arch Dermatol* 2005;141:907-8.
- Barranco R, Rodriguez A, de Barrio M, et al. Sympathomimetic drug allergy: cross-reactivity study by patch-tests. *Am J Clin Dermatol* 2004;5:351-5.
- Padial MA, Alavarez-Ferreira J, Tapia B, et al. Acute generalized exanthematous pustulosis associated with pseudoephedrine. *Br J Dermatol* 2004;150:139-42.
- Sanchez-Morillas L, Reano-Martos M, Rodriguez-Mosquera M, et al. Baboon syndrome due to pseudoephedrine. *Contact Dermatitis* 2003;48:234.
- Venturini M, Lezaun A, Abos T, et al. Immediate hypersensitivity due to pseudoephedrine. *Allergy* 2002;57:52-3.
- Thomas P, Rueff F, Pryzbilla B. Severe allergic contact blepharoconjunctivitis from phenylephrine in eye drops, with corresponding T-cell hyperresponsiveness in vitro. *Contact Dermatitis* 1998;38:41-3.
- Rochina A, Burches E, Morales C, et al. Adverse reaction to pseudoephedrine. *J Invest Allergol Immunol* 1995;5:235-6.

Streptokinase

Streptokinase is a 47,000 D protein produced by Beta hemolytic streptococci. Once bonded with plasminogen, the streptokinase-plasminogen complex cleaves arginine 560 on free plasminogen molecules in plasma.

Clinical uses of streptokinase include the treatment of acute myocardial infarction, deep venous thrombosis, arterial thrombosis and embolism.

■ Incidence

ISIS-2 trial: 4.4% of allergic reactions to streptokinase.

ISIS-3 trial: 3.6% of allergic reactions to streptokinase.

GUSTO-1 trial: 5.7% of allergic reactions to streptokinase (0.6% anaphylaxis).

■ Risk factors

Previous exposure to streptokinase: topical (6 months), antithrombotic use (4 years).

■ Clinical manifestations

Immediate reactions.

- **General:** anaphylactic shock.
- **Cutaneous:** rash, periorbital swelling.
- **Respiratory:** bronchospasm, ARDS, rhinorrhea, sneezing.
- **Delayed reactions:** fever, arthralgias, myalgias, leucocytoclastic vasculitis, renal abnormalities.

■ Diagnostic methods

Skin tests

Prick tests with streptokinase 300,000 IU/ml.

Intradermal tests: 0.02 ml of 3 IU and 10 IU streptokinase.

Some cases positive in patients with anaphylaxis.

Serologic methods.

Precipitating antibodies.

Anti-streptokinase IgE, IgG, IgM (ELISA).

Anti-streptokinase IgG (fluorimetric assay; fibrin plate assay).

Lymphocyte transformation test (one case).

■ Mechanisms

Complement activation.

Human albumin, phosphate buffers, and sodium glutamate are contained in streptokinase preparations.

IgE-mediated hypersensitivity: positive skin tests, specific IgE.

Type III hypersensitivity: serum sickness, vasculitis, glomerulonephritis.

The presence of anti-streptokinase antibodies in high titers may lead to a lower rate of coronary re-perfusion if streptokinase is re-used.

I Management

Use alteplase, reteplase or tenecteplase in streptokinase-allergic patients.

The biologic efficacy of streptokinase is not compromised by an allergic reaction.

The precise relation between streptokinase allergy, antibody titers, and clinical outcome requires further studies.

Hydrocortisone and antihistamines appear to have no protective effect against hypotensive reactions.

Perform an intradermal test with 100 IU of streptokinase before intravenous use. If positive, do not use streptokinase; a negative skin test is predictive of safe administration of streptokinase.

Rapid enzyme immunoassay of anti-streptokinase antibodies in human plasma (in 30 minutes) should allow the best thrombolytic therapy for the patient.

References

Betancourt BY, Marrero-Miragaya MA, Jimenez-Lopez G, et al. Pharmacovigilance program to monitor adverse reactions of recombinant streptokinase in acute myocardial infarction. *BMC Clin Pharmacol* 2005;2:5.

The International Collaborative Study of Severe Anaphylaxis. Risk of anaphylaxis in a hospital population in relation to the use of various drugs: an international study. *Pharmacoepidemiol Drug Saf* 2003;12:195-202.

Tsang TS, Califf RM, Stebbins AL, et al. Incidence and impact on outcome of streptokinase allergy in the GUSTO-1 trial. *Am J Cardiol* 1997;79:1232-5.

Jennings K. Antibodies to streptokinase (editorial). *BMJ* 1996;312(7028):393-4.

Lee HS. How safe is the re-administration of streptokinase? *Drug Safe* 1995;13:76-80.

Lynch M, Pentecost BL, Littler WA, et al. The significance of anti-streptokinase antibodies. *Clin Exp Immunol* 1994;96:427-31.

Topical corticosteroids

Topical corticosteroids are widely used, in particular in dermatology and in allergy. The first reports of allergy to hydrocortisone were published in 1959. Subsequently, with the use of routine patch tests with corticosteroids, the high frequency of hypersensitivity became evident in the late 1980s.

■ Classification

There are 5 chemical/structural classes of corticosteroids (see Isaksson, 2004).

Corticosteroids in group A: hydrocortisone, hydrocortisone acetate, methylprednisolone, prednisone, prednisolone, tixocortol and esters such as pivalate, fludrocortisone (acetate), cloprednol

Corticosteroids in group B: budesonide, desonide, amcinonide, triamcinolone (acetonide), fluclo-ronide, fluocinonide, flunisolide, fluocinolone acetonide, halcinonide, procinonide

Corticosteroids in group C: betamethasone, dexamethasone, desoximethasone, fluocortolone, halo-methasone, fluprednidene acetate

Corticosteroids in group D 1: beclomethasone dipropionate, betamethasone dipropionate, clobeta-sonone butyrate, alclometasone-17, 21-dipropionate, betamethasone-17-valerate, clobetasol propio-nate, clobetasone propionate, diflucortolone valerate, diflorasone diacetate, fluticasone propionate, mometasone furoate

Corticosteroids in group D 2: hydrocortisone (17-butyrate;17-aceponate;17-buteprate), methyl-prednisolone aceponate, prednicarbate, hydrocortisone valerate

■ Prevalence

1 to 5% with positive tests to different topical corticosteroids in populations undergoing patch tests.

■ Exposure

Topical corticoids with skin application

Inhalation

Gastrointestinal canal

■ Risk factors

Long term application for leg ulcers, atopic dermatitis, contact dermatitis, psoriasis or other types of inflammatory dermatitis

■ Clinical manifestations

Diagnosis is difficult due to the anti-inflammatory action on cutaneous lesions.

Increased eczema (atopic or contact dermatitis) despite well-conducted treatment

Eczematization of chronic dermatitis

Resistance of corticosensible dermatitis to the treatment

Erythema multiforme-like contact dermatitis

Mucosal edema

Reactivation of eczema following oral, parenteral, intra-articular, intra-lesional administration of a

corticosteroid

Maculo-papular rash, annular and centrifugum eczema (distant from treated areas), acute generalized exanthematous pustulosis, flexural rash

Anaphylaxis, urticaria, angioedema following parenteral administration of a corticosteroid

With nasal corticosteroids: pruritus, congestion, nasal burning, worsening of rhinitis, perforation of the nasal septum, contact stomatitis of the face and sometimes spread to flexures.

I Diagnostic methods

Skin tests

Patch tests

Standard series to detect corticosteroid allergy

Budesonide: 0.01% in pet

Betamethasone-17-valerate: 1% in pet

Triamcinolone acetonide: 1% in pet

Tixocortol-21(pivalate): 0.1% in pet (or 1% in pet; no statistically significant difference between the two concentrations)

Alclomethasone-17, 21-dipropionate: 1% in pet

Clobetasol-17-propionate: 1% in pet

Dexamethasone-21-phosphate disodium salt: 1% in pet

Hydrocortisone-17-butyrate: 1% in eth

Patch tests may be read 48 hr and 72 hr or 96 hr after placing the tests but also on Day 7 or 10 (delayed reactions are frequent, so late reading is necessary).

Others (see Isaksson)

Betamethasone dipropionate: 1% in eth

Amcinonide: 1% in eth

Beclomethasone dipropionate: 1% in eth

Clobetasone butyrate: 1% in eth

Desonide: 0.1% in eth

Desoximethasone : 1% in eth

Fluprednidene acetate: 0.01% in eth

Diflorasone diacetate: 1% in D/e (dimethyl sulphoxide/ethanol, 50/ 50)

Fluticasone propionate: 1% in D/e (dimethyl sulphoxide/ethanol, 50/ 50)

Fluocortolone: 1% in eth

Fluocinolone acetonide: 1% in eth

Hydrocortisone: 1% in D/e (dimethyl sulphoxide/ethanol, 50/ 50)

Methylprednisolone aceponate: 1% in eth

Mometasone furoate: 0.01% in eth

Prednicarbate: 1% in eth

For exploration of corticosteroid allergy

Group A: tixocortol pivalate

Group B: budesonide

Group C: betamethasone-17-valerate

Group D 1: betamethasone -17-valerate

Group D 2: budesonide and hydrocortisone -17-butyrate

Vehicles

The most frequent ingredients used in topical corticosteroids are: propylene glycol, parabens, sorbitan sesquioleate, formaldehyde-releasing preservatives, lanolin, methylchloroisothiazolinone/methylisothiazolinone, fragrance

■ Mechanisms

Delayed type hypersensitivity is more frequent than type I allergy.

■ Management

Avoidance.

Cross reactivity.

Group A: avoidance of A and D 2; C and D 1 are accepted

Group B: avoidance of B; A, C and D 1 are accepted

Group C: avoidance of C and D 1; A, B and D 2 are accepted

Group D 1: avoidance of C and D 1; A, B and D 2 are accepted

Group D 2: avoidance of D 2 and A; C and D 1 are accepted

References

Coloe J, Zirwas MJ. Allergens in corticosteroid vehicles. *Dermatitis* 2008;19:38-42.

Kalavala M, Statham BN, Green CM, et al. Tixocortol pivalate: what is the right concentration? *Contact Dermatitis* 2007;57:44-6.

Isaksson M. Systemic contact allergy to corticosteroids revisited. *Contact Dermatitis* 2007;57:386-8.

Chavarria Mur E, Gonzalez-Carrascosa M, Suarez Fernandez R, et al. Generalized exanthematous reaction pustulosis induced by topical corticosteroids. *Contact Dermatitis* 2005;53:114-5.

Isaksson M. Corticosteroids. *Dermatologic Therapy* 2004;17:314-20.

Isaksson M, Bruze M. Allergic contact dermatitis in response to budesonide reactivated by inhalation of the allergen. *J Am Acad Dermatol* 2002;45:880-5.

Stingeni L, Caraffini S, Assalve D, et al. Erythema-multiforme-like contact dermatitis from budesonide. *Contact Dermatitis* 1996;34:154-5.

X

SERA AND VACCINES

Antitetanus toxoid serum

Used in emergency settings to prevent tetanus in wounded patients not properly vaccinated against tetanus.

■ Incidence

Rare.

■ Risk factors

Sensitization to horse, dog, and cat albumins.

■ Clinical manifestations

- **General:** anaphylactic shock.

■ Diagnostic methods

Skin tests

Prick tests positive with pure antiserum.

Intradermal tests positive with 1/100 antiserum.

Specific serum IgE (ELISA)

Positive for horse, dog, and cat serum albumins.

■ Mechanisms

IgE-mediated hypersensitivity.

■ Management

Avoidance.

References

- Demoly P, Botros HG, Rabillon J, et al. Anaphylaxis to antitetanus toxoid serum. *Allergy* 2002;57:860-1.

Antivenoms

Antivenoms are prepared from immunized animal sera. They constitute the specific treatment for snake, spider and scorpion envenomation.

■ Incidence

Snake.

Crotalidae polyvalent immune Fab (ovine): 4.2 to 5.4%.

Brown snake antivenom: 10%.

Tiger snake antivenom: 41 to 75%.

Polyvalent snake antivenom: 41% (immediate reactions), 56% (serum sickness).

In Australia: 4.6% with premedication, 10% without premedication.

Spider.

Redback spider antivenom: 4% (immediate reactions), 10% (serum sickness).

Scorpion.

8% with *Centuroides sculpturatus* antivenom.

1.7 to 2.6% with *L. quinquestriatus* venom.

■ Risk factors

Allergy to animal serum or dander (horse, goat).

The risk of serum sickness is correlated with antivenom dosage (polyvalent crotalidae antivenom).

■ Clinical manifestations

- **General:** anaphylactic shock, serum sickness.
- **Cutaneous:** pruritus, urticaria, angioedema, rash.
- **Respiratory:** bronchospasm, acute pulmonary oedema.
- **Digestive:** vomiting, abdominal pain, diarrhea.

■ Diagnostic methods

Skin tests

Intradermal tests: 0.02 to 0.1 ml of a 1/10 dilution of the reconstituted antivenom.

Its usefulness is controversial. The incidence of false positives and false negatives seem to be high. Nevertheless, the specificity of *Centuroides sculpturatus* antivenom is 98%, the sensitivity 68%.

■ Mechanisms

IgE-mediated hypersensitivity (foreign animal proteins present in the antivenom).

Circulating immune complexes (serum sickness).

Complement activation from Fc receptor binding by antivenom or impurities.

I Management

In high risk patients, perform intradermal skin tests.

- If positive, the risk of an immediate reaction is high
- Negative results do not absolutely rule out the possibility of a reaction.

Low dose subcutaneous adrenaline is useful in preventing acute adverse reactions with antivenom in patients with snake bites (grade A recommendation).

No strong evidence to support the use of hydrocortisone as premedication for snake antivenom (grade B recommendation).

Current evidence does not support routine antihistamines as premedication for snake antivenom (grade A recommendation).

Rapid desensitization has been recommended.

References

Cannon R, Ruha AM, Kashani J. Acute hypersensitivity reactions associated with administration of crotalidae polyvalent immune Fab antivenom. *Ann Emerg Med* 2008;51:407-11.

Isbister GK, Brown SG, MacDonald E, et al. Current use of Australian snake antivenoms and frequency of immediate-type hypersensitivity reactions and anaphylaxis. *Med J Aust* 2008;188:473-6.

Evidence behind the WHO guidelines: hospital care for children: should s/c adrenaline, hydrocortisone or antihistamines be used as premedication for snake antivenom? *J Trop Pediatr* 2006;52:155-7.

LoVecchio F, Klemens J, Roundy EB, et al. Serum sickness following administration of anti venom (crotalidae) polyvalent in 181 cases of presumed rattlesnake envenomation. *Wilderness Environ Med* 2003;14:220-1.

Clark RF, Mc Kinney PE, Chase PB, et al. Immediate and delayed allergic reactions to crotalidae polyvalent immune Fab (ovine) antivenom. *Ann Emerg Med* 2002;39:671-6.

BCG Vaccine

BCG vaccine is widely used throughout the world to prevent tuberculosis. Other indications are intravesical treatment of superficial bladder cancer.

■ Incidence

Uncommon: mild reactions in 1/1,000; severe reactions 1 to 5/1,000,000. Fewer than ten cases in neonates and infants have been reported. More frequent when BCG is used for intravesical instillations.

■ Clinical manifestations

Differentiate from lymphadenitis or generalized granulomatosis.

- **General:** anaphylactic shock.
- **Cutaneous:** injection site reactions: small red areas at the site of injection usually appearing 10-14 days after injection and slowly decreasing in size; they should disappear after about 6 months; delayed granuloma lesion at the vaccination site; cold abscess; large keloids; juvenile sarcoidosis; fixed drug eruption at the site of BCG vaccination; local sign redness, irritation, ulceration at the BCG site during Kawasaki disease; eczema; granulomatous balanoposthitis. Lupus vulgaris, lichen scrofulosorum-like eruption; erythema induratum of Bazin. Rare: urticaria, acute erythroderma with multiple skin abscesses; pityriasis-rosea like eruption, erythema multiforme, pustular or urticarial vasculitis, Sweet's syndrome.
- **Respiratory:** interstitial pneumonitis.

■ Diagnostic methods

Tryptase measurement.

Elevated at the time of reaction (one case).

Dextran-specific IgG antibodies.

High titers were found in maternal serum in neonates with anaphylactoid reactions (passive reaction). One case (a sixteen year boy) with high levels (8 mg/l SIEMENS) after an anaphylactoid shock.

■ Mechanisms

Concerning the neonatal anaphylactic reactions reported after BCG vaccination, passively acquired maternal dextran antibodies reacted with 100 KD dextran which is a component of the BCG vaccine.

■ Management

SSI-BCG vaccine used in France does not contain dextran.

Pulsed steroid therapy controls hypersensitivity reactions after BCG intravesical instillation.

References

- Nadasy KA, Patel RS, Emmett M, et al. Four cases of disseminated mycobacterium bovis infection following intravesical BCG instillation for treatment of bladder carcinoma. *South Med J* 2008;101:91-5.
- Kureshi F, Kalaaji AN, Halvorson L, et al. Cutaneous complications of intravesical treatments for bladder cancer: granulomatous inflammation of the penis following BCG therapy and penile gangrene following mitomycin therapy. *J Am Acad Dermatol* 2006;55:328-31.
- Bellet JS, Prose NS. Skin complications of bacillus Calmette-Guerin immunization. *Curr Opin Infect Dis* 2005;18:97-100.
- Fauquert JL, Tridon A, Labbe A, et al. Post-BCG anaphylactoid reaction: the role of dextran? (Article in French). *Rev Fr Allerg Immu Clin* 2001;41:412-4.
- Rudin C, Gunthard J, Halter C, et al. Anaphylactoid reaction to BCG vaccine containing high molecular weight dextran. *Eur J Pediatr* 1995;154:941-2.
- Barbaud A, Schmutz JL, Mougeolle JM. Cutaneous immunoallergic reactions caused by vaccines (Article in French). *Ann Dermatol Venereol* 1995;122:129-38.

Botulinal antitoxin

Botulism is a paralyzing illness caused by the action of neurotoxins produced by *Clostridium botulinum*. One method of management is injection of an equine botulinal antitoxin.

■ Incidence

9% of injections (immediate manifestations: 5%, delayed manifestations: 4%).

■ Clinical manifestations

Anaphylactic shock (occurs even with small amounts of serum): 1.9% of cases;

Urticaria: 2.6% of cases.

Serum sickness (injections exceeding 40 ml): 3.7% of cases.

Generalized erythema, laryngeal edema: 0.7% of cases.

■ Diagnostic methods

Skin tests

Intradermal tests may be positive in patients presenting anaphylactic shock. However, the false negative rate is high (50%) and this test does not rule out the possibility of generalized reactions.

■ Mechanisms

IgE-mediated hypersensitivity probably underlies anaphylactic manifestations, but IgE antibodies have never been demonstrated.

The role of immune complexes is likely in cases involving serum sickness.

■ Management

No effective prevention of immediate reactions.

Inject less than 40 ml of botulinal antitoxin so as to minimize serum sickness.

Using botulinal immune globulin obtained from hyperimmunized human donors will be beneficial.

References

- Black RE, Gunn RA. Hypersensitivity reactions associated with botulinal antitoxin. *Am J Med* 1980;69:567-70.

Bovine serum albumin

Bovine serum albumin is a powerful immunogen able to produce allergic reactions. It is used during bone marrow transplantation and *in vitro* fertilization.

■ Incidence

Serum sickness: 1% to 15% (in 32 patients with in vitro fertilization).

■ Risk factors

Atopy.

Animal epithelium allergy.

■ Clinical manifestations

• **General:** anaphylactic shock, serum sickness.

• **Cutaneous:** urticaria, angioedema.

• **Respiratory:** bronchospasm, rhinoconjunctivitis.

■ Diagnostic methods

Skin tests

Prick tests: positive with BSA in 1% distilled water.

Intradermal tests with BSA 0.1 and 10 mg/ ml are positive in immediate and late responses, and positive to fetal calf serum (containing bovine serum albumin).

Specific serum IgE: IgE binding protein of 60 to 65 Kda anti BSA (ELISA / ImmunoCAP).

Specific serum IgG (ELISA) in serum sickness-like reactions.

Mast cell and basophil activation (CD63 expression).

■ Mechanisms

IgE-mediated hypersensitivity: positive skin tests and specific IgE against BSA. Sensitization to BSA may develop following natural contact (eating meat, drinking cow's milk, exposure to animal epithelia, dander or saliva containing serum albumin cross-reactive with BSA)

Serum sickness-like reactions: IgG 1-mediated sensitization to BSA

■ Management

Preoperative skin prick tests or specific serum IgE with the insemination medium is recommended.

Concerning bone marrow infusion, autologous plasma or serum is now used instead of BSA.

References

Pagan JA, Postigo I, Rodriguez-Pacheco JR, et al. Bovine serum albumin contained in culture medium used in artificial insemination is an important anaphylaxis risk factor. *Fertil Steril* 2008;90:2013.

Orta M, Ordoqui E, Aranzabal A, et al. Anaphylactic reaction after artificial insemination. *Ann Allergy Asthma Immunol* 2003;90:446-51.

Wehner-Caroli J, Schreiner T, Schippert W, et al. Anaphylactic reaction to bovine serum albumin after embryo transfer. *Fertil Steril* 1998;70:771-3.

Wüthrich B, Stern A, Johansson SGO. Severe anaphylactic reaction to bovine serum albumin at the first attempt of artificial insemination. *Allergy* 1995;50:179-83.

Moneret-Vautrin DA, Wal JM, Guillet-Rossof F, et al. Bovine serum albumin immunization. A new risk of allergy during protocols for in vivo fertilization. *Allergy* 1991;46:228-34.

Equine rabies immunoglobulins

In developing countries, equine rabies immunoglobulin (ERIG) is more readily available than human rabies immunoglobulin (HRIG). Modern ammonium sulfate-precipitated ERIG products are safe and effective (cost: 1/10 of human rabies immune globulins).

■ Incidence

Anaphylaxis: 1/35,000.

Serum sickness: 1.13 to 3.58% (exceedingly rare in children < 10 years of age).

■ Risk factors

Female sex.

■ Clinical manifestations

• **General:** anaphylactic shock, serum sickness.

• **Cutaneous:** generalized urticaria.

• **Respiratory:** bronchospasm.

■ Diagnostic methods

Skin tests are no longer performed (poor predictive value).

■ Mechanisms

IgE-mediated hypersensitivity.

Type III hypersensitivity (serum sickness).

■ Management

Premedication regimens (pheniramine, ranitidine, hydrocortisone, epinephrine) have been proposed.

References

Kularatne SA, Gihan MC, Jameel AM, et al. Outcome of skin sensitivity for predicting reactions to rabies equine immunoglobulins. *Ceylon Med J* 2007;52:149.

Suwansinon K, Jaijareowsup N, Wilde H, et al. Sex and age-related differences in rabies immunoglobulin hypersensitivity. *Trans R Soc Trop Med Hyg* 2007;101:206-8.

Rabies vaccines. WHO position paper. *Wkly Epidemiol Rec* 2007;82:425-35.

Tantawichien T, Benjavongkulchai M, Wilde H, et al. Value of skin testing for predicting reactions to equine rabies immunoglobulin. *Clin Infect Dis* 1995;21:660-2.

Wilde H, Chomchey P, Punyaratabandhu P, et al. Purified equine rabies immunoglobulin: a safe and affordable alternative to human rabies immunoglobulin. *Bull World Health Organ* 1989;67:731-6.

Hepatitis B vaccine

Recombinant DNA techniques have resulted in the development of vaccines to the hepatitis B virus prepared by cloning and expressing Hb antigens in yeast or CHO cells.

■ Incidence

Anaphylaxis: 1.1 to 7.8/1,000,000 doses.

Erythema multiforme: 1/100,000 doses.

■ Risk factors

Sensitization to formaldehyde.

Yeast allergy (especially in females 10 to 64 years old).

■ Clinical manifestations

• **General:** anaphylactic shock, arthralgias, myalgias, serum sickness.

• **Cutaneous:**

Local: injection-site reactions, transient (erythema, pruritus, edema, induration, pain, solitary mastocytoma). Subcutaneous nodules (aluminium hydroxide).

General: urticaria, angioedema, exanthema, lichen planus, lichenoid eruption (cutaneous and oral), pityriasis rosea-like eruption, erythema multiforme, eczema (rare), vasculitis, polyarteritis nodosa, Takayashu disease, Churg-Strauss syndrome, lupus erythematosus, erythema nodosum, granuloma annulare, pseudolymphomatous reaction.

• **Haematological:** thrombocytopenia.

■ Diagnostic methods

Skin tests

Prick tests: full vaccine 1/10, *Saccharomyces cerevesiae*, aluminum chloride 0.5%, latex.

Intradermal skin tests: full vaccine 1/100.

Patch tests: aluminum chloride 0.5%, formaldehyde 1%.

Few cases with positive tests to aluminum chloride, *saccharomyces cerevesiae*, latex or formaldehyde reported.

Specific IgE: *Saccharomyces cerevesiae*.

■ Mechanisms

Aluminum hydroxide, formalin, yeast or latex are responsible for the few reported allergic reactions to the hepatitis B vaccine.

■ Management

Use a yeast-free vaccine in yeast-allergic patients.

Use a formaldehyde-free vaccine in formaldehyde-allergic patient.

In patients with latex allergy, use a glass syringe and remove the rubber bung.

References

DiMiceli L, Pool V, Kelso JM, et al. Vaccination of yeast sensitive individuals: review of safety data in the US vaccine adverse reporting system (VAERS). *Vaccine* 2006;24:703-7.

Wine E, Ballin A, Dalal I. Infantile erythema multiforme following hepatitis B vaccine. *Acta Paediatr* 2006;95:890-1.

Craido PR, de Oliveira Ramos R, Vasconcellos C, et al. Two case reports of cutaneous adverse reactions following hepatitis B vaccine: lichen planus and granuloma annulare. *J Eur Dermatol Venereol* 2004;18:603-6.

Stavrianeas NG, Katoulis AC, Kanelleas A, et al. Papulonodular lichenoid hand pseudolymphomatous reaction at the injection site of hepatitis B virus vaccination. *Dermatology* 2002;205:166-8.

Beretta L, Caronni M, Vanoli M, et al. Churg-Strauss vasculitis with brain involvement following hepatitis B vaccination. *Clin Exp Rheumatol* 2001;19:757.

De Keyser F, Naeyaert JM, Hindryckx P, et al. Immune-mediated pathology following hepatitis B vaccination. Two cases of polyarteritis nodosa and one case of pityriasis rosea-like eruption. *Clin Exp Rheumatol* 2000;18:81-5.

Lear JT, English JSC. Anaphylaxis after hepatitis B vaccination. *Lancet* 1995;345:1249.

Barbaud A, Schmutz JL, Mougeolle JM. Cutaneous immunoallergic reactions caused by vaccines (Article in French). *Ann Dermatol Venereol* 1995;122:129-38.

Human serum albumin

Used as a plasma expander, in plasma exchange and for pulmonary perfusion scan (technetium 99 m-labeled human albumin microspheres). Recombinant HSA (Rhsa) has been successfully produced using a methylotrophic yeast

■ Incidence

0.099% for anaphylaxis

One-third of reactions are life-threatening.

■ Clinical manifestations

- **General:** anaphylactic shock.

- **Cutaneous:** with plasma-derived HSA: anaphylaxis, pruritus, urticaria, angioedema. With recombinant HSA: rash and pruritus are the most frequent, injection site reaction: erythema, eczema, edema, purpura, Henoch-Schönlein purpura, hot flush.

- **Respiratory:** bronchospasm.

■ Diagnostic methods

Skin tests

Intradermal tests with undiluted human serum albumin lead to false positive results.

Some authors have reported positive skin tests with dialysed, undialyzed and ultracentrifuged HSA 0.5% and 5%.

Specific IgE (ELISA): for IgE antibodies to 5% HSA.

Tryptase: elevated at the time of reaction

■ Mechanisms

IgE-mediated hypersensitivity is suggested by positive immediate skin tests and evidence of specific serum IgE.

Albumin aggregates (high molecular weight aggregates and some denatured albumin-globulin complexes may form during preparation of albumin solution)

A specific immune response to caprylate-modified HAS occurs occasionally

IgG anti-IgA in IgA-deficient patients.

Complement activation.

■ Management

Avoidance.

References

- Kasahara A, Kita K, Tomita E, et al. Repeated administration of recombinant human serum albumin caused no serious allergic reactions in patients with liver cirrhosis: a multicenter clinical study. *J Gastroenterol* 2008;43:464-72.
- Fujita A, Kitayama M, Hirota K. Anaphylactoid shock in a patient following 5% human serum albumin infusion during off-pump coronary artery bypass grafting. *J Anesth* 2007;21:396-8.
- Stafford CT, Lobel CA, Fruge BC, et al. Anaphylaxis to human serum albumin. *Ann Allergy* 1988;61,85-8.
- Edelman BB, Straughn MA, Getz P, et al. Uneventful plasma exchange with albumin replacement in a patient with a previous anaphylactoid reaction to albumin. *Transfusion* 1985;25:435-6.
- Littenberg RL. Anaphylactoid reaction to human albumin microspheres. *J Nucl Med* 1975;16:236-7.

Influenza vaccine

■ Incidence

Extremely low.

■ Risk factors

Egg allergy.

Gelatin allergy.

■ Clinical manifestations

• **General:** anaphylactic shock.

• **Cutaneous:** injection site reaction (erythema, edema, induration, pain, inflammation): frequent; urticaria, angioedema, fixed drug eruption, vasculitis (de novo or reactivation: cutaneous or systemic with histological leucocytoclastic vasculitis), Henoch-Schonlein purpura, microscopic polyangiitis (ANCA positive), bullous pemphigoid reactivation, pemphigus induction, Sweet's syndrome (sometimes bullous), Gianotti-Crosti syndrome.

■ Diagnostic methods

Skin tests

Prick tests with pure vaccine and intradermal tests 1/100 are usually negative.

Specific IgE (IgE immunoblot): a protein band at 100 kDa (gelatin), a protein band at 68 kDa (hemagglutinin from influenza vaccine), a protein band at 45 kDa (ovalbumin) in a patient with anaphylaxis.

■ Mechanisms

Egg allergy (ovalbumin): the content of ovalbumin/ovomuroid is variable: 0.02 to 1.2 µg/ml.

Gelatin allergy.

Vaccine allergy (hemagglutinin).

■ Management (controversial)

In patient with egg allergy and skin tests positive to vaccine:

- vaccination in a 2 dose protocol at 30 min interval if the vaccine preparation contains no more than 1.2 µg/ml egg protein
- incremental dosage if > 1.2 µg/ml or unknown.

References

Coop CA, Balanon SK, White KM, et al, Anaphylaxis from the influenza virus vaccine, *Int. Arch. Allergy. Immunol.* 2007;146(1):85-8

Uji M, Matsushita H, Iwata S, *Microscopic polyangiitis after influenza vaccination*, *Intern. Med.* 2005;44: 892-6

Mormil R, d'Alterio V, Treccagnoli G, et al, *Henoch-Schonlein purpura with antiphospholipid antibodies after influenza vaccination: how fearful is it in children?*, *Vaccine.* 2004;23:567-8

Zeiger RS, *Current issues with influenza vaccination in egg allergy*, *J. Allergy. Clin. Immunol.* 2002;110(6): 834-40

James JM, Zeiger RS, Lester MR, et al, *Safe administration of influenza vaccine to patients with egg allergy*, *J. Pediatr.* 1998;133(5):624-8

Barbaud A, Schmutz JL, Mougeolle JM. *Cutaneous immunoallergic reactions caused by vaccines (Article in French).* *Ann Dermatol Venereol* 1995;122:129-38.

Intravenous immunoglobulins

Polyvalent immunoglobulins are used in the treatment of congenital or acquired immunodeficiencies and in the management of some immune disorders.

■ Incidence

2 to 6% (rate-related).

■ Risk factors

Selective IgA deficiency.

CVID patients with retained class-switched CD 27 + IgM (neg) IgD (neg) memory B cells (FREIBURG classification group II) and total IgA deficiency.

Multiple blood or plasma infusions.

Autoimmune diseases.

■ Clinical manifestations

Occurring on the first or second infusion.

Severe: anaphylactic shock.

Moderate: chest tightness, mild wheezing.

Mild: headache, flushing, low backache, muscle pain, nausea, chills, abdominal pain.

• **Cutaneous reactions:** eczematous reactions (acral eruption with palmar-plantar desquamation occurring 8 to 15 days after infusion lasting 15 days; may occur faster and more seriously on the next infusion), acute generalized eczema, pruritus, maculopapular rash, lichenoid dermatitis, purpuric eruption, Baboon syndrome, erythema multiforme, lupus erythematosus (subacute), vasculitis with leukocytoclastic reaction, alopecia.

■ Diagnostic methods

Skin tests

Prick, intradermal and patch tests are negative.

Antibodies.

IgG anti-IgA antibodies are detected in 22% of patients with common variable immunodeficiency, and in 20 to 60% of patients with selective IgA deficiency.

Anti-IgA antibodies are found more frequently in patients with combined IgA and IgG2 subclass deficiencies.

IgA antibodies are class-specific, subclass-specific, antiallotypic, antiisoallotypic, or of limited specificity.

IgE anti-IgA (ELISA) has been reported in patients with anaphylactic shock and IgA deficiency.

■ Mechanisms

Formation of immune complexes between antibodies in intravenous immunoglobulins and microbial antigens in the recipient with subsequent complement activation.

Presence of IgG or IgE anti-IgA in patients with absolute absence of IgA.

I Management

Slow infusion rate alleviates chills, fever, and headache.

Use of IgA-depleted intravenous IgG preparations until the activity of anti-IgA decreases significantly or becomes undetectable.

Ex-vivo pretreatment of intravenous immunoglobulin preparation containing less than 0.1 mg/ml IgA with autologous plasma.

Use of the subcutaneous route (no reaction).

References

- Ahrens N, Höflich C, Bombard S, et al. Immune tolerance induction in patients with IgA anaphylactoid reactions following long-term intravenous IgG treatment. *Clin Exp Immunol* 2008;151:455-8.
- Horn J, Thon V, Bartonkova D, et al. Anti-IgA antibodies in common variable immunodeficiency (CVID): diagnostic workup and therapeutic strategy. *Clin Immunol* 2007;122:156-62.
- Bodemer AA, Longley BJ. Thrombotic lymphocytic vasculitic reaction to intravenous immunoglobulin. *J Am Acad Dermatol* 2006;55:S112-3.
- Salama A, Temmesfeld B, Hippenstiel S, et al. A new strategy for the prevention of IgA anaphylactic transfusion reactions. *Transfusion* 2004;44:509-11.
- Jegou R, Moutarda I, Ollivier I, et al. Side effects of intravenous immunoglobulin therapy (Article in French). *Ann Dermatol Venerol* 2001;128:786-91.
- Barbaud A, Trechot P, Granel F, et al. A Baboon syndrome induced by intravenous human immunoglobulins: report of a case and immunological analysis. *Dermatology* 1999;199:258-60.
- Leclech C, Maillard H, Penisson-Besnier I, et al. Unusual skin reactions after intravenous infusion of polyvalent immunoglobulin: 3 cases (Article in French). *Presse Med* 1999;28:531.

Measles-Mumps-Rubella vaccine

Measles and mumps vaccine strains are grown in chick embryo cells and rubella in human diploid culture.

■ Incidence

Anaphylaxis 1.8 to 10/10⁶ doses.

In Finland: Anaphylaxis 1/100,000

Urticaria 1/100,000

Asthma 0.3/100,000

Henoch-Shonlein purpura 0.07/100,000

Stevens-Johnson's syndrome 0.03/100,000

■ Risk factors

Gelatin allergy.

HLA DR9 (Japanese individuals).

■ Clinical manifestations

• **General:** anaphylactic shock.

• **Cutaneous:** injection-site reaction, pruritus, urticaria, angioedema, rash (several to 48 h after vaccination): morbilliform, rubeoliform. Vasculitis, Henoch-Schönlein purpura, erythema multiforme, Stevens-Johnson syndrome, toxic epidermal necrolysis, Gianotti-Crosti syndrome, Mucha-Haberman disease.

• **Respiratory:** cough, asthma.

■ Diagnostic methods

Skin tests

Prick or intradermal tests in egg-allergic individuals have been debated; several studies have found poor positive and negative values.

Skin tests can also trigger anaphylaxis.

Specific serum IgE to gelatin (ImmunoCAP, IMMUNOSPOT).

Gelatin-specific cell mediated immunity: in vitro lymphocyte proliferation assay, antigen-specific IL-2 responsiveness (delayed reactions to gelatin).

■ Mechanisms

Gelatin allergy (14.5 mg/dose of vaccine): 93% of cases in Japan; 27% in USA and Finland.

Neomycin allergy (25 µg/dose): extremely rare (a few cases reported).

Egg allergy (controversial) (0.5 to 1 ng of ovalbumin/dose): hundreds of egg-allergic children have been vaccinated safely without special precautions.

I Management

The vaccine produced entirely in human diploid cells containing the Rubini virus strains provides poor protection against mumps.

Use a gelatin free vaccine in gelatin-allergic patients.

Egg-allergic children can be vaccinated without special precautions.

Extra precautions including continuous observation for 20 min after vaccination, with further monitoring of cardiorespiratory parameters to a total of 2 hours are needed if there is a history of any cardiorespiratory symptoms or signs after egg ingestion or active chronic asthma is present.

References

- Piquer-Gibert M, Plaza-Martin A, Martorell-Aragones A, et al. Recommendations for administering the triple viral vaccine and antiinfluenza vaccine in patients with egg allergy. Allergol Immunopathol 2007;35:209-12.*
- Cerecedo Carballo I, Dieguez-Pastor MC, Bartolome-Zavala B, et al. Safety of measles-mumps-rubella vaccine (MMR) in patients allergic to eggs. Allergol Immunopathol 2007;35:105-9.*
- Bernardini ML, D'Angelo G, Oggiano N, et al. Erythema multiforme following live attenuated trivalent measles mumps rubella vaccine. Acta Derm. Venereol 2006;86:359-60.*
- Pool V, Braun MM, Kelso JM, et al. Prevalence of anti-gelatin IgE antibodies in people with anaphylaxis after measles-mumps-rubella vaccine in the United States. Pediatrics 2002;110:e71.*
- Carapetis JR, Curtis N, Royle J. MMR immunisation. True anaphylaxis to MMR vaccine is extremely rare. BMJ 2001;323(7317):869.*
- Patja A, Maniken-Kiljunen S, Davidkin I, et al. Allergic reactions to measles-mumps-rubella vaccination. Pediatrics 2001;107:e27.*
- Khakoo GA, Lack G. Recommendations for using MMR vaccine in children allergic to eggs. BMJ 2000;320(7239):929-32.*

Pneumococcal vaccine

Incidence

Rare.

Clinical manifestations

- **General:** fever, anaphylactic shock, serum sickness (sometimes severe in AIDS patients).
- **Cutaneous:** pruritus, rash, urticaria, angioedema, facial edema, petechiae, pityriasis rosea, injection-site reaction, leucocytoclastic vasculitis sometimes delayed, acute exanthematous pustular dermatitis (rare).

Diagnostic methods

Skin tests: positive in one child with anaphylaxis.

Specific serum IgE (self-made RAST*): positive in one child with anaphylaxis.

Mechanisms

IgE-mediated hypersensitivity (immediate generalized reaction).

Management

Avoidance.

References

- Hengge UR, Scharf RE, Kroon FP, et al. Severe serum sickness following pneumococcal vaccination in an AIDS patient. *Int J STD AIDS* 2006;17:210-1.
- Holdiness MR. Rare systemic dermatologic reaction after pneumococcal vaccine administration. *South Med J* 2003;96:64-5.
- Saamaz S, Karabiber H, Boran C, et al. Pityriasis rosea-like eruption due to pneumococcal vaccine in a child with nephrotic syndrome. *J Dermatol* 2003;30:245-7.
- Ponvert C, Ardelean-Jaby D, Colin-Gorski AM, et al. Anaphylaxis to the 23-valent pneumococcal vaccine in child: a case-control study based on immediate responses in skin tests and specific IgE determination. *Vaccine* 2001;19:4588-91.
- Fox BC, Peterson A. Leukocytoclastic vasculitis after pneumococcal vaccination. *Am J Infect Control* 1998;26:365-6.
- Correia O, Nunes JP, Vaz-da-Silva M, et al. Acute exanthematous pustular dermatitis after pneumococcal vaccine. *Dermatology* 1993;187:217.

Rabies vaccine

Human diploid cell rabies vaccine is an inactivated vaccine prepared from the rabies virus grown in human diploid cell cultures then dissolved in tributyl phosphate and inactivated a second time with b-propiolactone.

■ Incidence

Local reactions: 21-74%.

Mild systemic reactions: 5-40%.

Systemic hypersensitivity: 6% (less common following primary immunization).

108/100,000 - 87/100,000 type III reactions

9/100,000 type I reactions

In some reports, type III reactions occurred in 6% of immunized individuals boosted with the current HDC rabies vaccine.

■ Risk factor

Booster doses for type III reactions.

■ Clinical manifestations

- **General:** fever, headache, dizziness, serum sickness, arthralgia, arthritis.
- **Cutaneous:** pruritus, rash, urticaria (sometimes delayed), angioedema (sometimes delayed).
- **Respiratory:** bronchospasm, laryngeal edema.
- **Others:** nausea, vomiting.

■ Diagnostic methods

Skin tests

Positive tests to vaccine and mock vaccine.

Specific serum IgE (immunofluorescence): the specificity of this method has been confirmed by solid phase binding of the vaccine to antigens (19 out of 21 cases of urticaria).

■ Mechanisms

IgE-mediated hypersensitivity.

Type III hypersensitivity.

The principal antigen implicated in the IgE-mediated response is a modified protein component of the vaccine: a b-propiolactone-human serum albumin (BPL-HSA) complex formed during preparation of the vaccine.

Some individuals produce a dual reaction (IgG and IgE) against BPL-HSA and fetal calf serum.

I Management

The new HDC rabies vaccine, Lyssavac-HDC Berna, is safer (no type III hypersensitivity reactions reported).

The vaccine should be prepared without b-propiolactone (inactivation with formalin or tributylphosphate only).

Boosters should only be administered to risk-group patients

The use of the intradermal route for both primary and booster injections may result in lower rates of reactions.

References

Rabies vaccines. WHO position paper. Wkly Epidemiol Rec 2007;82:425-35.

Briggs DJ, Dreesen DW, Morgan P, et al. Safety and immunogenicity of Lyssavac Berna human diploid cell rabies vaccine in healthy adults. Vaccine 1996;14:1361-5.

Fishbein DB, Yenne KN, Dreesen DW, et al. Risk factors for systemic hypersensitivity reactions after booster vaccinations with human diploid cell rabies vaccine: a nationwide prospective study. Vaccine 1993;11:1390-4.

Swanson MC, Rosanoff E, Gurwith M, et al. IgE and IgG antibodies to beta propiolactone and human serum albumin associated with urticarial reactions to rabies vaccine. J Infect Dis 1987;155:909-3.

Warrington RJ, Martens CJ, Rubin M, et al. Immunologic studies in subjects with a serum sickness-like illness after immunization with human diploid cell rabies vaccine. J Allergy Clin Immunol 1987;79:605-10.

Systemic allergic reactions following immunization with human diploid cell rabies vaccine. MMWR Morb Mortal Wkly Rep 1984;33:185-7.

Tetanus/Diphtheria toxoid

Tetanus and diphtheria toxoids have been in use for several decades and have proven their effectiveness and safety. However, a few immediate and delayed reactions have been observed.

■ Incidence

Local reactions after booster injections:

pain and tenderness: 50 -85%

erythema and edema: 20 - 30%

marked swelling: 2%

abscess: 6 to 10/million doses.

Anaphylaxis: 0.1 to 1/100,000.

■ Risk factors

Previous history of reaction to tetanus toxoid.

■ Clinical manifestations

• **General:** anaphylactic shock, fever.

• **Cutaneous:** injection-site reaction (sometimes extensive and severe), pruritus, rash, urticaria, angioedema, vasculitis, erythema multiforme. Rare: toxic epidermal necrolysis, pemphigus, granuloma annulare.

• **Others:** glomerulonephritis.

■ Diagnostic methods

Skin tests

Prick tests with undiluted vaccine.

Intradermal test 1/100.

Positive in allergic patients but also positive in 8 to 63% of non-allergic vaccinated patients.

Specific serum IgE /IgG (ELISA/Immunoblotting/ImmunoCAP Phadia/FEIA) (only for tetanus toxoid).

Two proteins (150 and 50 kDA) derived from tetanus toxoid corresponding to the intracellular form and to a chain of the extracellular form of the tetanus neurotoxin. 25% of non-allergic patients have detectable specific IgE.

■ Mechanisms

IgE-mediated hypersensitivity.

Hyperimmunization.

Preservatives: formaldehyde, 2-phenoxyethanol.

I Management

Obtain an antitetanus IgG titer to verify the need for a booster.

Use a tetanus toxoid formulation with a different preservative.

Use an isolated tetanus toxoid which is less reactogen than associations (diphtheria/ tetanus)

Desensitization has been reported to be effective.

1	0.02 cc	1/1 000	ID	
2	0.02 cc	1/100	ID	
3	0.02 cc	1/10	SC	
4	0.10 cc	1/10	SC	At 30 min intervals
5	0.05 cc	Full strength	SC	
6	0.10 cc	Full strength	SC	
7	0.15 cc	Full strength	SC	
8	0.20 cc	Full strength	SC	

References

Karıncaoglu Y, Aki T, Ergucan-Onal R, et al. Erythema multiforme due to diphtheria-pertussis-tetanus vaccine. *Pediatr Dermatol* 2007;24:334-5.

Sekaran NK, Edwards KM. Extensive swelling reaction associated with diphtheria and tetanus toxoids and acellular vaccine. *Pediatr Infect Dis J* 2006;25:374-5.

Mayorga C, Torres MJ, Corzo JL, et al. Immediate allergy to tetanus toxoid vaccine: determination of immunoglobulin E and immunoglobulin G antibodies to allergenic proteins. *Ann Allergy Asthma Immunol* 2003;90:238-43.

Martin-Munoz MF, Pereira MJ, Posadas S, et al. Anaphylactic reaction to diphtheria-tetanus vaccine in a child: specific IgE/IgG determinations and cross-reactivity studies. *Vaccine* 2002;20:3409-12.

Bellioni Businco B, Paganelli R, Bruno G, et al. Allergy to tetanus toxoid vaccine. *Allergy* 2001;56:701-2.

Ponvert C, Scheinmann P, Karila C, et al. Allergy to multivalent vaccines in children: a study of 30 cases using immediate, semi-late and late skin test responses, specific antibody assays, and challenge with monovalent and bivalent vaccines (Article in French). *Rev Fr Allergol Immunol Clin* 2001;41:701-19.

Uriel AJ, Boyter AC, Mac Connachie AM, et al. Immunization against tetanus in a hypersensitive individual using a graded dosing regimen (letter). *J Infect* 1995;30:83-4.

Yellow fever vaccine

■ Incidence

1/131,000

■ Risk factors

Egg allergy.
Gelatin allergy.

■ Clinical manifestations (95% of cases following the first injection)

- **General:** anaphylactic shock.
- **Cutaneous:** injection site reaction.

■ Mechanisms

Egg or gelatin allergy.

■ Management

Desensitization: successful in one patient starting from 0.1 ml of a 1/1000 dilution to 0.2 ml undiluted.

References

- Kelso JM, Mootrey GT, Tsai TF. Anaphylaxis from yellow fever vaccine. J Allergy Clin Immunol 1999;103:698-701.*
- Mosimann B, Stози B, Francillon C, et al. Yellow fever vaccine and egg allergy. J Allergy Clin Immunol 1995;95:1064.*
- Charpin J, Vervloet D, Birnbaum J. Yellow fever desensitization to an anti-amaril 17 D vaccine performed on a patient with anaphylaxis to eggs (Article in French). Bull Acad Natl Med 1989;171:101-5.*

XI

VITAMINS



Calcipotriol

Calcipotriol is a vitamin D3 derivative widely used in the treatment of psoriasis.

I Incidence

High: 20% of patients.

I Clinical manifestations

- **Cutaneous:** lesional and perilesional irritation, contact allergy (underestimated), generalized pustular psoriasis (precipitated by topical ointment).

I Diagnostic methods

Patch tests with the cream (ointment is irritant) or, better, with calcipotriol 10 µg/ml in isopropanol. Patch tests with propylene glycol.

I Mechanisms

Irritation.

Sometimes delayed contact hypersensitivity.

I Management

Cream and solution are less irritating than ointment.

Avoidance in cases of contact allergy.

Cross-reactivity may exist between calcipotriol and other vitamin D3 analogue: tacalcitol and calcitriol.

References

Foti C, Carnimeo L, Bonamonte D, et al. Tolerance to calcitriol and tacalcitol in three patients with allergic contact dermatitis to calcipotriol. *J Drugs Dermatol* 2005;4:756-9.

Park YK, Lee JH, Chung WG. Allergic contact dermatitis from calcipotriol. *Acta Derm Venereol* 2002;82:71-2.

Krayenbühl BH, Elsner P. Allergic and irritant contact dermatitis to calcipotriol. *Am J Contact Dermat* 1999;10:78-80.

Giordano-Labadie F, Laplanche G, Bazex J. Contact eczema caused by calcipotriol (Article in French). *Ann Dermatol Venereol* 1996;123:196-7.

de Groot A. Contact allergy to calcipotriol. *Contact Dermatitis* 1994;30:242-3.

Cyanocobalamin/hydroxocobalamin (Vitamin B12)

Vitamin B12 is widely used as a supplement in patients with ileal malabsorption and those with pernicious anemia.

■ Incidence

Rare. Deaths reported.

■ Risk factors

Intravenous administration.

■ Clinical manifestations

(occurring within weeks or months, but sometimes after several years of treatment)

- **General:** anaphylactic shock.
- **Cutaneous:** generalized urticaria, angioedema, eczematous rash, pruritus. Others: acne, rosacea.
- **Respiratory:** bronchospasm.

Recurrence of allergic reactions to vitamin B12 may occur after ingestion of Marmite (yeast derived extract containing at least 15 µg of cyanocobalamin/100 g).

■ Diagnostic methods

Skin tests

Prick tests: positive with pure hydroxocobalamin in a few cases

Intradermal tests: positive at 1/100 to 1/10 dilution.

No specific IgE found

Specific histamine release: positive in one patient.

■ Mechanisms

The vitamin itself, the preservatives (benzyl alcohol) or some contaminants may be involved. Contact dermatitis due to the cobalt ring contained in this vitamin has been reported.

Possible IgE-mediated hypersensitivity (positive skin tests, specific histamine release).

■ Management

Cross-reactivity between hydroxocobalamin and cyanocobalamin has been described but is not always found.

In patients with hydroxocobalamin allergy, if skin tests are negative cyanocobalamin can be used in increasing intramuscular doses (0.1mg; 0.5mg; 1 mg).

Combination of corticosteroids and antihistamines may be useful.

Desensitization in patients allergic to both hydroxocobalamin and cyanocobalamin may be performed. For example, with cyanocobalamin: 0.1 ml (1/100 = 10 µg/ml) to 0.5 ml pure (500 µg)

Oral or nasal route may be an alternative, but reactions have been reported and therapeutic efficacy is lower.

References

- Caballero MR, Lukawska J, Lee TH, et al. Allergy to vitamin B12: two cases of successful desensitization with cyanocobalamin. Allergy 2007;62:1341-2.*
- Turvey SE, Cronin B, Arnold AD, et al. Adverse reactions to vitamin B12 injections due to benzyl alcohol sensitivity: successful treatment with intranasal cyanocobalamin. Allergy 2004;59:1023-4.*
- Heyworth-Smith D, Hogan PG. Allergy to hydroxycobalamin with tolerance of cyanocobalamin. Med J Aust 2002;177:162.*
- Tordjman R, Genereau T, Guinnepain MT, et al. Reintroduction of vitamin B12 in 2 patients with prior B12-induced anaphylaxis. Eur J Haematol 1998;60:269-70.*
- Branco-Ferreira M, Clode MH, Pereira-Barbosa MA, et al. Anaphylactic reaction to hydroxycobalamin. Allergy 1997;52:118-9.*

Folic acid / folinic acid

Folic acid is reduced by the liver to metabolically active 5-methyltetrahydrofolate. Folinic acid (5-formyltetrahydrofolate) bypasses the reduction steps required for folic acid. Folates have numerous pharmacological effects, both therapeutic and preventive. In oncology, folinic acid at high doses increases 5-FU toxicity by stabilising the ternary couple.

■ Incidence

Extremely rare.

■ Clinical manifestations

- **General:** anaphylactic shock.
- **Cutaneous:** pruritus, urticaria, rash (rare), hypersensitivity syndrome (exceptional).

■ Diagnostic methods

Skin tests: positive in a patient to folic acid and other folate analogues.

Specific serum IgE (dot immunoblot assay/ELISA): IgE antibody to folate-HSA.

Challenge test.

■ Mechanisms

IgE-mediated hypersensitivity.

■ Management

Avoidance.

A diet rich in natural folates (pteroylpolyglutamates) appears useful as a management strategy to provide adequate nutrition to patients with folic acid hypersensitivity.

References

Smith J, Empson M, Wall C. Recurrent anaphylaxis to synthetic folic acid. *Lancet* 2007;370(9588):652.

Pfab F, Willi R, Albert A, et al. Anaphylactic reaction to folic acid verified by provocational test. *Allergy* 2007;62:823-4.

Benchalal M, Yahchouchy-Chouillard E, Fouere S, et al. Anaphylactic shock secondary to intravenous administration of folinic acid. *Ann Oncol* 2002;13:480-1.

Dykewicz MS, Orfan NA, Sun W. In vitro demonstration of IgE antibody to folate-albumin in anaphylaxis from folic acid. *J Allergy Clin Immunol* 2000;106:386-9.

Sesin GP, Kirschenbaum H. Folic acid hypersensitivity and fever: a case report. *Am J Hosp Pharm* 1979;36:1565-7.

Riboflavin

Riboflavin (vitamin B2) is contained in soft drinks and multivitamin tablets.

▮ Incidence

One case described

▮ Clinical manifestations

General: anaphylactic shock.

▮ Diagnostic methods

Skin tests

Prick tests.

Intradermal skin tests: positive

▮ Mechanisms

Possible IgE-mediated hypersensitivity.

▮ Management

Avoidance.

References

▮ *Ou LS, Kuo ML, Huang JL. Anaphylaxis to riboflavin (vitamin B2). Ann Allergy Asthma Immunol 2001;87:430-3.*

Thiamine (Vitamin B1)

Vitamin B1 or thiamine hydrochloride is used in thiamine deficiency syndromes (cardiovascular beriberi syndrome and central Wernicke-Korsakoff syndrome). It is the most allergenic vitamin.

■ Incidence

9 deaths reported between 1965 and 1985, but only 0.1% major reactions and 1% minor local reactions in a large study (1,070 consecutive parenteral administrations of thiamine hydrochloride).

■ Risk factors

Multiple large doses.

Parenteral administration (IV, IM, SC).

Allergic symptoms upon prior administration.

■ Clinical manifestations

• **General:** anaphylactic shock.

• **Cutaneous:** pruritus, rash, urticaria, angioedema, eczema, DRESS syndrome (one case associated with quinine).

• **Respiratory:** bronchospasm.

• **Digestive:** nausea, abdominal cramps.

■ Diagnostic methods

Skin tests

A few cases of positive skin prick tests or intradermal tests (0.5 to 5 mg/ ml)

Specific serum IgE and IgG (ELISA).

Specific histamine release.

■ Mechanisms

Thiamine may act as a hapten (transformation to an azoprotein).

■ Management

Administration of parenteral thiamine only when required (thiamine deficiency).

References

Gréco M, Dupré-Goetghebeur D, Leroy JP, et al. DRESS syndrome related to Hexaquine (quinine and thiamine)- (Article in French). *Ann Dermatol Venereol* 2006;133:354-8.

Johri S, Shetty S, Soni A, et al. Anaphylaxis from intravenous thiamine long-forgotten? *Am J Emer Med* 2000;18:642-3.

Morinville V, Jeannot-Peter N, Hauser C. Anaphylaxis to parenteral thiamine (vitamin B1). *Schweiz Med Wochenschr* 1998;128:1743-4.

Fernandez M, Barcelo M, Munoz C, et al. Anaphylaxis to thiamine (vitamin B1). *Allergy* 1997;52:958-60.

Proebstle TM, Gall H, Jugert FK, et al. Specific IgE and IgG serum antibodies to thiamine associated with anaphylactic reaction. *J Allergy Clin Immunol* 1995;95:1059-60.

Vitamin B6

Pyridoxine, pyridoxal and pyridoxamine are 3 biologically similar interchangeable compounds referred to as vitamin B6. Pyridoxine is widely used in the preparation of medications and cosmetics (hair lotion).

■ Incidence

Contact dermatitis is infrequent.
Photoallergy is exceptional.

■ Clinical manifestations

• **Cutaneous:** contact dermatitis, photosensitive dermatitis with sometimes vesiculo-bullous lesions localized on sun exposed skin. Others: rosacea eruption with high dose of vitamins.

■ Diagnostic methods

Skin tests

Patch tests and photopatch tests (UVA radiation): pyridoxine hydrochloride (1% and 5% in pet).

■ Mechanisms

Delayed hypersensitivity.

Photoallergy: photopatch positive and sometimes decreased MED (minimal erythematous dose) after systemic administration.

■ Management

Avoidance.

References

Bajaj AK, Rastogi S, Misra A, et al. Occupational and systemic contact dermatitis with photosensitivity due to vitamin B6. *Contact Dermatitis* 2001;44:184.

Murata Y, Kumano K, Ueda T, et al. Photosensitive dermatitis caused by pyridoxine hydrochloride. *J Am Acad Dermatol* 1998;39:314-7.

Tanaka M, Niizeki H, Shimizu S, et al. Photoallergic drug eruption due to pyridoxine hydrochloride. *J Dermatol* 1996;23:708-9.

Camarasa JG, Serra-Baldrich E, Lluch M. Contact allergy to vitamin B6. *Contact Dermatitis* 1990;23:115.

Vitamin K

Vitamin K is mainly used in patients with hypoprothrombinemia.

■ Incidence

Anaphylaxis: 3/10,000 intravenous doses (0.04 to 11/10,000).

23 cases reported from 1966 to 1999 (3 deaths).

52 cases of cutaneous hypersensitivity reactions to vitamin K reported from 1964 to 1995 (Europe and North America).

94 cases of cutaneous hypersensitivity reactions to vitamin K reported in Japan up to 1988.

■ Risk factors

Intravenous route (even in low doses by slow dilute infusion)

■ Clinical manifestations

- **General (intravenous vitamin K1):** anaphylactic shock, facial flush, abdominal pain, loss of consciousness.

- **Cutaneous:**

Acute: erythematous, eczematoid, pruritic, indurated plaque beginning after 10 to 15 days; at the injection site (IM or SC) with oil-soluble vitamin K1 (phytomenadione). This acute reaction usually resolves in a few weeks. Persistent reactions are possible despite treatment with topical steroids (several months).

Reaction resembling localized scleroderma or morphea (more rare): onset from 2 months to 1.5 years following administration of vitamin K1; around the injection site; may be preceded by an eczematoid reaction; reaction may last for years (Texier's syndrome).

Contact dermatitis: occupational contact with vitamin K3 (in pig feed, pharmaceutical factories and laboratories, and in veterinary laboratories)

Urticaria, diffuse maculo-papular rash: a few cases have been reported.

■ Diagnostic methods

Skin tests

Intradermal tests: 0.02 ml phytomenadione 0.05% in NaCl 0.9%.

Patch tests: 10 mg/ml in olive oil.

Patch tests may be positive in patients with an eczematous localized site reaction (sometimes delayed after the 4th day).

Intradermal tests may be positive in eczematous localized site reactions, with an eczematous reaction developing in 48 to 72 hours.

Patch tests may be negative and intradermal reactions positive in the same patient.

■ Mechanisms

Cremophor EL used in some countries as a solvent for intravenous formulation of vitamin K1 is thought to be the culprit in anaphylactoid reactions.

Delayed hypersensitivity (positive patch tests).

The phytyl moiety contained in phytomenadione, but not in other forms of vitamin K, might be the epitope.

■ Management

Vitamin K exists in 4 different pharmacological forms:

- vitamin K1 (phytomenadione): naturally occurring form (oil soluble)
- vitamin K2 (menaquinone): synthesized by bacteria in intestine
- vitamin K3 (menadiolone): synthetic analogue (oil soluble)
- vitamin K4 (menadiol): synthetic analogue (water soluble).

When administered orally, vitamins K1, K3, and K4 do not result in skin disease.

Cross-reactivity between vitamin K3 and K4 has been described, but not between vitamin K1 and other vitamin K derivatives.

Prefer oral and water-soluble formulations of vitamin K.

Intravenous vitamin K should be limited to patients with serious hemorrhage that is secondary to a relative or absolute deficiency of vitamin K.

References

Wjasow C, Mc Namara R. Anaphylaxis after low dose intravenous vitamin K. *J Emerg Med* 2003;24:169-72.

Riegert-Johnson DL, Volcheck GW. The incidence of anaphylaxis following intravenous phytonadione (vitamin K1): a 5 year retrospective review. *Ann Allergy Asthma Immunol* 2002;89:400-6.

Fiore LD, Scola MA, Cantillon CE, et al. Anaphylactoid reactions to vitamin K. *J Thromb Thrombolysis* 2001;11:175-83.

Wilkins K, de Koven J, Assaad D. Cutaneous reactions associated with vitamin K1. *J Cutan Med Surg* 2000;4:164-8.

Bruynzeel I, Hebeda CL, Folkers E, et al. Cutaneous hypersensitivity reactions to vitamin K: 2 case reports and a review of the literature. *Contact Dermatitis* 1995;32:78-82.

XII

GASTROENTEROLOGY

Histamine H₂ receptor antagonists

Histamine H₂ receptor antagonists are widely used in the treatment of gastric and duodenal ulcers, gastro oesophageal reflux and hypersecretions states.

Ranitidine, Nizatidine, Famotidine, Cimetidine.

■ Incidence

Uncommon.

■ Clinical manifestations

- **General:** anaphylactic shock.
- **Cutaneous:** pruritus, urticaria, angioedema, maculopapular rash, erythema multiforme, Stevens-Johnson syndrome, toxic epidermal necrolysis, cutaneous delayed reactions (papular eruptions), photosensitivity, fixed drug eruption, Baboon syndrome, lichenoid eruption, acute generalized exanthematous pustulosis, vasculitis, psoriasis exacerbation, lupus erythematosus exacerbation.
- **Respiratory:** dyspnea, bronchospasm, laryngeal edema.
- **Digestive:** acute cholestatic hepatitis with rash and hypereosinophilia.
- **Haematological:** thrombocytopenia.

■ Diagnostic methods

Skin tests

Prick tests: 10 mg/ml (ranitidine, nizatidine)

Or 0.25, 2.5, and then 25 mg/ml

Intradermal tests: + from 1/10,000 to 1/10.

Basophil activation test.

Specific IgE positive (ranitidine): one case.

Leukotriene release test.

Leukocyte histamine release.

Challenge test.

■ Mechanisms

IgE-mediated hypersensitivity (positive skin tests, specific serum IgE, leukocyte histamine release). Cross-reactivity among histamine H₂ receptors antagonists exists (ranitidine/nizatidine).

I Management

Avoidance.

Use another H2 antagonist if necessary (after negative cutaneous testing and oral challenge).

References

Okamoto O, Fujiwara S. Drug eruption caused by ranitidine hydrochloride (Zantac*) which showed a strong reaction in a drug-induced lymphocyte stimulation test. *J Dermatol* 2007;34:74-9.

Koyh YI, Park HS, Choi IS. Ranitidine induced anaphylaxis: detection of serum specific IgE antibody. *Allergy* 2006;61:269-70.

Demirkan K, Bozkurt B, Karakaya G, et al. Anaphylactic reaction to drugs commonly used for gastrointestinal system diseases 3 cases reports and review of the literature. *J Investif Allergol Clin Immunol* 2006;16:203-9.

Morisset M, Moneret-Vautrin DA, Loppinet V, et al. Cross-allergy to ranitidine and nizatidine. *Allergy* 2000;55:682.

Mira-Perceval JL, Ortiz JL, Sarrío F, et al. Nizatidine anaphylaxis. *J Allergy Clin Immunol* 1996;97:855-6.

Proton pump inhibitors

Omeprazole, Lansoprazole, Pantoprazole, Rabeprazole, Esomeprazole.
Proton pump inhibitors are widely used in the treatment of peptic ulcer and gastroesophageal diseases.

■ Incidence

Uncommon.

■ Clinical manifestations

- **General:** anaphylactic shock (omeprazole, lansoprazole, pantoprazole: a few cases).
- **Cutaneous:** pruritus, rash, urticaria, angioedema, erythroderma, exfoliative dermatitis, photosensitive eruption, erythema multiforme, Stevens-Johnson syndrome, toxic epidermal necrolysis (two deaths). Others: DRESS, acute generalized exanthematous pustulosis, fixed drug eruption, pityriasis rosea, lichenoid eruption, erythema nodosum, dermatomyositis, vasculitis.
- **Haematological:** thrombocytopenia.
- **Renal:** acute interstitial nephritis.

■ Diagnostic methods

Skin tests

Usually positive

- Prick tests:
omeprazole 4 mg/ml
lansoprazole 3 and 30 mg/ml
pantoprazole 4mg/ml
rabeprazole 20 mg/ml
- Intradermal tests:
omeprazole 0.04, 0.4 mg/ml
lansoprazole 0.03, 0.3 mg/ml
pantoprazole 0.04, 0.4 mg/ml
rabeprazole 2 mg/ml
- Patch tests:
30% in pet or aq (commercialized form); with caution in severe +++ cutaneous reactions.

No specific serum IgE found.

Drug rechallenge.

Serum tryptase levels.

I Mechanisms

IgE-mediated hypersensitivity.

Cross reactivity among proton pump inhibitors exists:

Omeprazole/lansoprazole,
Lansoprazole/rabeprazole,
but not with other imidazoles.

I Management

Avoidance; if impossible, a PPI with negative skin tests may be used.
Desensitization with omeprazole 0.001 mg → 16 mg (5-6 hours).

References

- Perez-Pimiento AJ, Prieto-Lastra L, Rodriguez-Cabreros MI, et al. Hypersensitivity to lansoprazole and rabeprazole with tolerance to other proton pump inhibitors. J Allergy Clin Immunol 2006;117:707-8.*
- Confino-Cohen R, Goldberg A. Anaphylaxis to omeprazole diagnosis and desensitization protocol. Ann Allergy Asthma Immunol 2006;96:33-6.*
- Porcel S, Rodriguez A, Jimenez S, et al. Allergy to lansoprazole: study of cross-reactivity among proton pump inhibitors. Allergy 2005;60:1087-8.*
- Gonzalez P, Soriano V, Lopez P, et al. Anaphylaxis to proton pump inhibitors. Allergol Immunopathol 2002;30:342-3.*
- Cockayne SE, Glet RJ, Gawkrödger DJ, et al. Severe erythrodermic reactions to the proton pump inhibitors omeprazole and lansoprazole. Br J Dermatol 1999;141:173-5.*

Sulfasalazine

A compound consisting of sulphapyridine (a sulfonamide) and 5-aminosalicylic acid joined by an azo bond; used in the treatment of inflammatory bowel diseases and rheumatoid arthritis. Sulphapyridine is believed to be responsible for most of the hypersensitivity reactions although the salicylate compound may also be implicated.

■ Incidence

5 to 55% of patients present adverse side effects.

Hypersensitivity is involved in only 2% of these manifestations.

■ Risk factors

Hypersensitivity syndrome: slow acetylator genotype (N-acetyltransferase 2), elderly black men, flu-like illness within the previous 6 weeks.

■ Clinical manifestations

General hypersensitivity syndrome (mortality 20%):

- maculopapular rash developing > 3 weeks after starting the drug
- fever > 38° C
- prolonged clinical syndrome after discontinuing the drug
- liver abnormalities (ALT > 100 U/l)
- leukocyte abnormalities: leukocytosis >11.10⁹ /l or atypical lymphocytes >5% or eosinophilia >1.5 10⁹ /l
- lymphadenopathy
- HHV-6, CMV, EBV reactivation (increase in IgG titers detected in the 2nd or 3rd week after start of the symptoms).
- various forms of renal involvement: tubulo interstitial nephritis to granulomatous necrotizing angitis, cardiac manifestations.
- **Cutaneous:** pruritus, rash, erythroderma, urticaria, angioedema, fixed drug reaction, acute generalized exanthematous pustulosis, erythema multiforme, Stevens-Johnson syndrome, toxic epidermal necrolysis, lupus erythematosus, bullous pemphigoid, lichen planus, photosensitivity.
- **Haematological:** blood dyscrasias: bone marrow depression, aplastic anemia, agranulocytosis, neutropenia, thrombocytopenia.
- **Respiratory:** hypersensitivity pneumonitis (50 cases published until 2002; 5 deaths): dyspnea, cough, fever, eosinophilic pneumonia, interstitial inflammation with or without fibrosis.
- **Digestive:** hepatitis, hepatic failure, pancreatitis (rare).

Blood dyscrasias, hepatitis and hepatic failure, serious skin reactions are reported more commonly in patients receiving sulfasalazine for rheumatoid arthritis rather than for inflammatory bowel disease.

I Diagnostic methods

Skin tests

Patch tests: sometimes positive.

Lymphocyte transformation test: sometimes positive.

I Mechanisms

Anticonvulsant hypersensitivity syndrome. Two main hypotheses: stimulation of T cells by the drug leading to reactivation of herpes virus harbored in T cells. Clinically unapparent reactivation of herpes virus occurs. The virus-stimulated T cells show a substantial cross-reactivity with certain drugs; administration of the drug leads to expansion of these specific T cells, and this continues after cessation of the drug due to persistence of viral antigens.

Type IV b hypersensitivity reaction: T helper 2 cells play a significant role. Tissue cells produce high levels of interleukin-5 and eotaxin that result in a maculopapular rash with eosinophilia.

I Management

Avoidance.

A majority of sulfasalazine-intolerant patients (90%) are able to tolerate at least one of the three 5-ASA preparations (mesalazine, olsalazine, balsalazide), but hypersensitivity to 5-ASA itself exists, and the tolerance profile of mesalazine in such patients is not much better (pancreatitis, interstitial nephritis).

Desensitization is a safe approach in mild hypersensitivity reactions, but is contra-indicated in patients with the hypersensitivity syndrome, blood dyscrasias or serious cutaneous reactions.

Many protocols for use in adults and also in children have been published. For example, in adults, starting with 1 mg and doubling the dose each week: 1 mg, 2 mg, 4 mg, 8 mg, 10 mg, 20 mg, 40 mg, 80 mg, 100 mg, 200 mg, 400 mg, 800 mg, 1000 mg, 2000 mg. If a reaction occurs, slow the progression.

Treatment of the hypersensitivity syndrome: steroids 1 to 1.5 mg/kg; intravenous immunoglobulins, plasma exchange.

References

- Komatsuda A, Okamoto Y, Hatakeyama T, et al. Sulfasalazine-induced hypersensitivity syndrome and hemophagocytic syndrome associated with reactivation of Epstein Barr virus. *Clin Rheumatol* 2008;27:395-7.
- Petkov T, Pehlivanov G, Grozdev I, et al. Toxic epidermal necrolysis as a dermatological manifestation of drug hypersensitivity syndrome. *Eur J Dermatol* 2007;17:422-7.
- Teo L, Tan E. Sulphasalazine-induced DRESS. *Singapore Med J* 2006;47:237-9.
- Iemoli E, Piconi S, Ardizzone S, et al. Erythroderma and toxic epidermal necrolysis caused by 5-aminosalicylic acid. *Inflamm Bowel Dis* 2006;12:1007-8.
- Ransford RAJ, Langman MJS. Sulphasalazine and mesalazine: serious adverse reaction reports to the Committee on Safety of Medicines. *Gut* 2002;51:536-9.

Kawaguchi M, Mitsuhashi Y, Kondo S. Acute generalized exanthematous pustulosis induced by salazopyrindine in a patient with ulcerative colitis. *J Dermatol* 1999;26:359-62.

Lachaux A, Legall C, Loras-Duclaux I, et al. Hypersensitivity to 5-aminosalicylic acid. Value of desensitization by oral route (Article in French). *Arch Pediatr* 1997;4:144-6.

Akahoshi K, Chijiwa Y, Kabemura T, et al. Desensitization for sulfasalazine-induced skin-rash in a patient with ulcerative colitis. *J Gastroenterol* 1994;29:772-5.

Koski JM. Desensitization to sulphasalazine in patients with arthritis. *Clin Exp Rheumatol* 1993;11:169-70.

XIII

BIOLOGICAL AGENTS



Adalimumab

A fully human recombinant monoclonal anti-TNF alpha antibody used in the treatment of rheumatoid and psoriatic arthritis.

I Incidence

5% of adults in phase I, II, III studies developed low titer antibodies to adalimumab during treatment which did not correlate with adverse effects.

Allergic reactions: 1%.

I Clinical manifestations

- **General:** anaphylactic shock, hypersensitivity reaction in the first two hours of infusion: urticaria, dyspnea and/or hypotension. Serum sickness-like reaction.

- **Cutaneous:** injection site reaction: frequent in the first month, transitory (2/3 days), may disappear in two months; eosinophilic cellulitis-like reaction, urticaria, angioedema, pruritus, delayed rash, psoriasis, palmoplantar pustulosis, lichenoid reaction, erythema multiforme, interstitial granulomatous dermatitis, vasculitis, lupus erythematosus, granuloma annulare, alopecia areata universalis.

- **Respiratory:** asthma.

I Diagnostic methods

None.

I Mechanisms

Unknown.

I Management

Avoidance.

References

Benucci M, Manfredi M, Demoly P, et al. Injection site reactions to TNF-alpha blocking agents with positive skin tests. *Allergy* 2008;63:138-9.

Borras-Blasco J, Gracia-Perez A, Nunez-Cornejo C, et al. Exacerbation of psoriatic skin lesion in a patient with psoriatic arthritis receiving adalimumab. *J Clin Pharm Ther* 2008;33:321-5.

Pelivani N, Hassan AS, Braathen LR, et al. Alopecia areata universalis elicited during treatment with adalimumab. *Dermatology* 2008;216:320-3.

Campi P, Benucci M, Manfredi M, et al. Hypersensitivity reactions to biological agents with special emphasis on tumor necrosis factor-alpha antagonists. *Curr Opin Allergy Clin Immunol* 2007;7:393-403.

Nikas SN, Voulgari PV, Drosos AA. Urticaria and angioedema-like skin reactions in a patient treated with adalimumab. *Clin Rheumatol* 2007;26:787-8.

Spilane AP, Xia Y, Sniezek PJ. Drug-induced lupus erythematosus in a patient treated with adalimumab. *J Am Acad Dermatol* 2007;56:S114-6.

Alefacept

Alefacept is the first biological agent approved by the FDA for the treatment of moderate to severe chronic plaque psoriasis. It is a fully human fusion protein binding to CD2 on T cells.

■ Incidence

Unknown.

■ Clinical manifestations

- **General:** fatigue, headache (14%), influenza (8%), nasopharyngitis (10%), rhinitis, upper respiratory tract infections arthralgias, increase in liver enzymes, nausea.
- **Cutaneous:** pruritus (8%), injection site reactions (16%): pain, inflammation, bleeding, edema.
- **Others:** development of antibodies against alefacept (< 1% of patients) is not associated with hypersensitivity reactions.

■ Diagnostic methods

None.

■ Mechanisms

Unknown.

■ Management

Discontinuation of treatment is usually not necessary.

References

Jenneck C, Novak N. The safety and efficacy of alefacept in the treatment of chronic plaque psoriasis. *Ther Clin Risk Manag* 2007;3:411-20.

Scheinfeld N. Alefacept: a safety profile. *Expert Opin Drug Saf* 2005;4:975-85.

Thielen AM, Kuenzli S, Saurat JH. Cutaneous adverse events of biological therapy for psoriasis: review of the literature. *Dermatology* 2005;211:209-17.

Frampton J, Wagstaff A. Alefacept. *Am J Clin Dermatol* 2003;4:277-86.

Alemtuzumab

A CD 52 monoclonal antibody with significant clinical activity in the chemotherapy refractory B-cell chronic lymphocytic leukemia.

■ Clinical manifestations

- **General:** infusion-related side effects (IV): hypotension, rigors, fever, shortness of breath, bronchospasm, chills, rash.
- **Cutaneous:** pruritus, rash, urticaria, bullous eruption, injection site reactions, edema (peripheral, orbital, oral).

■ Diagnostic methods

None.

■ Mechanisms

Cytokine release.

■ Management

Antihistamines, acetaminophen and corticosteroids prevent infusion-related events.

References

Lenz HJ. Management and preparedness for infusion and hypersensitivity reactions. *The Oncologist* 2007;12:601-9.

Osterborg A, Karlsson C, Lundin J, et al. Strategies in the management of alemtuzumab-related side effects. *Semin Oncol* 2006;33:529-35.

Anakinra

Anakinra is a recombinant human form of interleukin-1 receptor used to treat patients with rheumatoid arthritis.

■ Incidence

Local cutaneous reactions at injection sites are frequent.

■ Clinical manifestations

- **Cutaneous:** occurring during the first month of treatment: well defined erythema and oedema involving the injection sites.

■ Diagnostic methods

Skin tests

Prick tests: negative (one case).

Intradermal tests: 0.05 ml (2500µg/ml), positive in one patient.

Specific serum IgE (ELISA): positive in one patient (the specificity of antibodies was confirmed by ELISA inhibition studies).

Skin biopsies.

Dermal oedema, lichenoid dermal infiltrate, increase in mast cell numbers.

■ Mechanisms

Possible IgE-mediated hypersensitivity in one case.

■ Management

Treatment can usually be continued.

References

Vila AT, Puig L, Fernandez-Figueras MT, et al. Adverse cutaneous reactions to anakinra in patients with rheumatoid arthritis: clinicopathological study of five patients. *Br J Dermatol* 2005;153:417-23.

Grammer LC, Roberts M. Cutaneous allergy to recombinant human type I IL-1 receptor (rhu IL-1R). *J Allergy Clin Immunol* 1997;99:714-5.

Antithymocyte globulin

Antithymocyte globulin (polyclonal antibodies generated in rabbits) and related compounds are being studied in liver transplantation for their ability to minimize the use of the nephrotoxic calcineurin inhibitors, to delay the use of calcineurin inhibitors in patients with preexisting renal failure, to reduce overall steroid use, and to eliminate the need for maintenance immunosuppression.

■ Incidence

Serum sickness.

Kidney transplantation: 7.5 to 16.1%.

Liver transplantation: 0 to 6.2%.

■ Risk factors

Previous exposure to thymoglobulin.

Previous exposure or allergy to rabbit or horse antigens.

■ Clinical manifestations

• **General:** anaphylactic shock (rare), serum sickness:

Major criteria :

- > 7 days since initial thymoglobulin administration
- persistent high fever (> 39°C)
- persistent arthritis/arthralgias
- positive heterologous antibodies on ELISA

Minor criteria :

- +/- acute renal failure
- +/- rash
- +/- trismus
- +/- low complement (C3, C4).

• **Cutaneous:** morbilliform eruption, urticaria, combination of these two patterns, acral erythematous eruption preceding rash.

• **Others:** rapidly progressive descending paralysis (during serum sickness).

■ Diagnostic methods

Skin tests

Prick tests: a positive prick test to ATG may be predictive of anaphylaxis.

Serum IgM and IgG anti-rabbit and anti-horse globulins are not predictive of the occurrence of clinical serum sickness.

■ Mechanisms

IgE-mediated hypersensitivity (anaphylactic shock).

Antigen-antibody interaction, complement activation and resultant inflammatory response (serum sickness).

I Management

Corticosteroids and therapeutic plasma exchange are used in the management of serum sickness.

Desensitization is possible but not always successful.

References

- Lundquist AL, Chari RS, Wood JH, et al. Serum sickness following rabbit antithymocyte-globulin induction in a liver transplant recipient: case report and literature review. *Liver Transpl* 2007;13:647-50.
- Pham PT, Pham PM, Miller JM, et al. Polyclonal antibody-induced serum sickness presenting as rapidly progressive descending paralysis. *Transplantation* 2007;83:1657.
- Hall M, Hagemann TM. Successful desensitization to antithymocyte globulin in a child with aplastic anemia. *Am J Health Syst Pharm* 2006;63:1633-6.
- Tanriover B, Chuang P, Fishbach B, et al. Polyclonal antibody-induced serum sickness in renal transplant recipients: treatment with therapeutic plasma exchange. *Transplantation* 2005;80:279-81.
- Ferdman RM, Wakim M, Church JA, et al. Rapid intravenous desensitization to antithymocyte globulin in a patient with aplastic anemia. *Transplantation* 2004;77:321-3.
- Millar MM, Grammer LC. Case reports of evaluation and desensitization for anti-thymocyte globulin hypersensitivity. *Ann Allergy Asthma Immunol* 2000;85:311-6.

Basiliximab

Chimeric monoclonal anti-L2 receptor antibody used in renal transplantation.

I Clinical manifestations

- **General:** anaphylactic shock.
- **Cutaneous:** pruritus, rash, edema (generalized or localized: facial, genital, tongue, peripheral edema), urticaria.
- **Respiratory:** bronchospasm.

I Diagnostic methods

Skin tests

Intradermal tests: positive 1/100 (2 cases) (negative with daclizumab).

Specific serum IgE (ELISA): positive (negative with daclizumab).

CAST: positive (negative with daclizumab).

I Mechanisms

IgE-mediated hypersensitivity.

I Management

Switch to daclizumab (humanized murine antibody).

References

Pichler WJ, Campi P. Adverse side effects to biological agents. In Pichler WJ (ed): *Drug Hypersensitivity*. Basel, Karger. 2007;pp151-65.

Sasaki H, Chikaraishi T, Furuhashi S, et al. Anaphylactic reaction after initial exposure of Basiliximab: case reports. *Transplant Proc* 2007;39:3457-9.

Barros VR, Rocha V, Garcia VD, et al. Anaphylactic shock after retreatment with basiliximab. *Transplant Proc* 2003;35:579.

Baudouin V, Crusiaux A, Haddad E, et al. Anaphylactic shock caused by immunoglobulin E sensitization after retreatment with the chimeric antiinterleukin-2 receptor monoclonal antibody basiliximab. *Transplantation* 2003;76:459-63.

Leonard PA, Woodside KJ, Gugliuzza KK, et al. Safe administration of a humanized murine antibody after anaphylaxis to a chimeric murine antibody. *Transplantation* 2002;74:1697-1700.

Bevacizumab

A monoclonal antibody used in association with 5FU in the management of patients with metastatic colorectal carcinoma. It is a vascular endothelial growth factor antagonist. Bevacizumab may be used in intravitreal injection to treat ocular diseases associated with vascular endothelial growth factor.

■ Incidence

Severe infusion reaction < 1%.
Exfoliative dermatitis 19%.

■ Clinical manifestations

- **General:** arterial hypertension, hypertension associated with neurological signs and symptoms, headache, rigors, diaphoresis, proteinuria, bleeding, gastrointestinal perforation, arterial thrombosis.
- **Cutaneous:** rash (sometimes positive correlation between rash and therapeutic response), exfoliative dermatitis, edema (facial, acral, ocular, lower legs), pruritus, stomatitis.
- **Respiratory:** wheezing, oxygen desaturation.

■ Diagnostic methods

None.

■ Mechanisms

Acute infusion reactions: cytokine release.

■ Management

Treatment interruption and supportive therapy.

References

Shima C, Sakaguchi H, Gomi F, et al. Complications in patients after intravitreal injection of bevacizumab. *Acta Ophthalmol* 2008;86:372-6.

Saif MW, Longo WL, Israel G. Correlation between rash and a positive drug response associated with bevacizumab in a patient with advanced colorectal cancer. *Clin Colorectal Cancer* 2008;7:144-8.

Lenz HJ. Management and preparedness for infusion and hypersensitivity reactions. *The Oncologist* 2007;12:601-9.

Reidy DL, Chung KY, Timoney JP, et al. Bevacizumab 5 mg/kg can be infused safely over 10 minutes. *J Clin Oncol* 2007;25:2691-5.

Cetuximab

A monoclonal chimeric mouse-human IgG 1 antibody against epidermal growth factor receptor approved for use in colorectal cancer and squamous cell carcinoma of the head and the neck.

I Incidence

Severe hypersensitivity reactions: 3%.

Much higher in patients in North Carolina and Tennessee: 22%.

I Risk factors

Presence of cetuximab-specific IgE antibodies (specific for galactose-alpha-1.3-galactose present on the Fab portion of the cetuximab heavy chain).

I Clinical manifestations (90% during the first infusion)

• **General:** hypotension, cardiac arrest.

• **Cutaneous:**

PRIDE syndrome (Papulopustules and/or paronychia, Regulatory abnormalities of hair growth, Itching, Dryness caused by Epidermal growth factor inhibitors).

Papulopustular eruption: the most frequent side effect (60% to 80%), dose-dependant relationship, rapid onset after the initiation of treatment: 7 to 10 days or more; distribution in the seborrheic areas (face, scalp, upper back, shoulders and neck and behind the ears); acneiform eruption with follicular papules and pustules without comedons; pruritus and telangectasias may be associated; resolution after completion of the molecule or spontaneously despite the continued therapy: eruption may be correlated to tumor response.

Eczematiform eruption with pruritus and sometimes with photodistribution.

Telangectasias with rosacea-like appearance of the face, xerosis, nail changes (paronychia with or without pyogenic granulomas), hair abnormalities, trichomegaly.

Others: vasculitis, mucosal lesions.

• **Respiratory:** bronchospasm, stridor, hoarseness.

I Diagnostic methods

Specific serum IgE (ImmunoCAP Phadia).

I Mechanisms

IgE-mediated hypersensitivity for immediate reactions.

Skin toxicity: EGRF inhibition includes impaired growth and migration of keratinocytes and inflammatory chemokine expression by cells. These effects lead to inflammatory cell recruitment and subsequent cutaneous injury.

I Management

Avoidance.

Switch to panitumumab.

References

Chung CH, Mirakhur B, Chan E, et al. Cetuximab-induced anaphylaxis and IgE specific for galactose-alpha-1.3-galactose. *N Engl J Med* 2008;358:1109-17.

Deslandres M, Sibaud V, Chevreau C, et al. Cutaneous side effects associated with epidermal growth factor receptor and tyrosine kinase inhibitors (Article in French). *Ann Dermatol Venereol* 2008;Spec N°1:16-24.

Lenz HJ. Management and preparedness for infusion and hypersensitivity reactions. *Oncologist* 2007;12:601-9.

Guillot B, Bessis D. Clinical appearance and management of cutaneous side effects of EGF receptor inhibitors (Article in French). *Ann Dermatol Venereol* 2006;133:1017-20.

Denileukin-Diftitox

A novel recombinant fusion protein (fragments of diphtheria toxin linked to human interleukin-2) approved for the treatment of relapsed or refractory cutaneous T-cell lymphoma working by targeting the high affinity interleukin-2 receptor expressed on malignant cells.

■ Incidence

Infusion-related hypersensitivity: 70%.

Vascular leak syndrome: 27%.

■ Clinical manifestations

- **General:** infusion-related hypersensitivity, vascular or capillary leak syndrome.

- **Cutaneous:** rash (erythema, edema) may precede a more severe reaction; pruritus, injection site reaction, toxic epidermal necrolysis (one fatal case).

■ Diagnostic methods

None.

■ Mechanisms

Unknown.

■ Management

Use of corticosteroids (dexamethasone or prednisone) prior to each dose of denileukin diftitox decreases the incidence of acute infusion events and vascular leak syndrome.

References

Polder K, Wang C, Duvic M, et al. Toxic epidermal necrolysis associated with denileukin diftitox (DAB389IL-2) administration in a patient with follicular large cell lymphoma. *Leuk Lymphoma* 2005;46:1807-11.

Eklund JW, Kuzel TM. Denileukin diftitox: a concise clinical review. *Expert Rev Anticancer Ther* 2005;5:33-8.

Acosta M, Teitelbaum A. Capillary leak syndrome in a patient treated with interleukin 2 fusion toxin for cutaneous T-cell lymphoma. *J Am Acad Dermatol* 2001;44:312-3.

Foss FM, Bacha P, Osann KE, et al. Biological correlates of acute hypersensitivity events with DAB(389)IL-2 (denileukin diftitox, ONTAK) in cutaneous T-cell lymphoma: decreased frequency and severity with steroid premedication. *Clin Lymphoma* 2001;1:298-302.

Efalizumab

A recombinant humanized T cell-targeting monoclonal antibody approved for use in adults with chronic moderate-to-severe plaque psoriasis.

Incidence

Unknown.

Clinical manifestations

- **General:** fever, flu-like symptoms (chills, headache, nausea, vomiting, myalgia), inflammatory neuropathies.
- **Cutaneous:** outbreak of cutaneous psoriasis during or after discontinuation of treatment. Possibility of erythrodermic or generalized pustular psoriasis. Localized mild breakthrough: inflammatory, papular eruption with punctiform lesions, localized or disseminated (trunk, neck, intertriginous areas); 4 to 8 weeks after the initiation of treatment; transitory evolution. Hypersensitivity reactions (minor), DRESS syndrome, injection-site reaction, lupus-like syndrome, hypertrichosis, multiple eruptive dermatofibromas.
- **Haematological:** hyperlymphocytosis, thrombocytopenia (0.22%), pancytopenia, delayed autoimmune hemolytic anemia.

Diagnostic methods

None.

Mechanisms

Unknown.

Management

Side effects are usually mild.

References

Schmitt J, Zhang Z, Wozel G, et al. Efficacy and tolerability of biologic and nonbiologic systemic treatments for moderate-to-severe psoriasis: meta-analysis of randomized controlled trials. *Br J Dermatol* 2008;159:513-26.

Firmin D, Roguedas AM, Lemasson G, et al. Eczematous dermatosis and thrombocytosis induced by efalizumab: two new side effects. *Dermatology* 2008;217:203-6.

Fargnoli MC, Tabilio A, Coletti G, et al. Efalizumab-induced immune thrombocytopenia during retreatment. *J Am Acad Dermatol* 2008;58:S125-7.

Durox H, Sparsa A, Loustaud-Ratti V, et al. Efalizumab-induced lupus-like syndrome. *Acta Derm Venereol* 2008;88:270-1.

Kwan JM, Reese AM, Trafeli JP. Delayed autoimmune hemolytic anemia in efalizumab-treated psoriasis. *J Am Acad Dermatol* 2008;58:1053-5.

White JM, Smith CH, Robson A, et al. DRESS syndrome caused by efalizumab. *Clin Exp Dermatol* 2007;33:50-2.

Descamps V. Efalizumab (Article in French). *Ann Dermatol Venereol* 2006;133:666-78.

Warkentin TE, Kwon P. Immune thrombocytopenia associated with efalizumab therapy for psoriasis. *Ann Intern Med* 2005;143:761-3.

Erlotinib/Gefitinib

Reversible inhibitors of epidermal growth factor receptor (EGFR) tyrosine kinase (TK) newly approved for the treatment of refractory, locally advanced, or metastatic non-small-cell lung cancer, metastatic breast cancer, pancreatic cancer (erlotinib), and non-small cell lung cancer (gefitinib).

I Incidence

Very high for papulopustular eruption (60 to 80%).

I Clinical manifestations

- **Cutaneous:** frequent reactions: PRIDE syndrome (papulopustules and/or paronychia, regulatory abnormalities of hair growth, itching, dryness caused by epidermal growth factor inhibitors). Papulopustular eruption: the most frequent side effect (60 to 80%), dose-dependant relationship, rapid onset after initiation of treatment (7 to 10 days), distribution in the seborrheic areas (face, scalp, upper back, shoulders and neck and behind the ears); acneiform eruption with follicular papules and pustules without comedons; pruritus and telangectasias may be associated; resolution after completion of the treatment or spontaneously despite continued therapy: eruption may be correlated to tumor response. Eczematiform eruption with pruritus and sometimes with photodistribution, telangectasias with rosacea-like appearance of the face, xerosis, nail changes (paronychia with or without pyogenic granulomas), hair abnormalities, trichomegaly. Others: vasculitis, mucosal lesions, generalized exanthematous pustulosis (gefitinib).

- **Others:** interstitial pneumonitis (2-3% in Japan), myocarditis.

I Diagnostic methods

None.

I Mechanisms

EGFR inhibition leads to impaired growth and migration of keratinocytes and inflammatory chemokine expression by cells. These effects lead to inflammatory cell recruitment and subsequent cutaneous injury, which accounts for the majority of symptoms including tenderness, papulopustules and periungual inflammation.

I Management

Management of rash is a key factor in patient tolerance and compliance. Severe rash and dose reductions can be avoided with proactive/early intervention.

Grade I: topical low to medium potency corticosteroids or calcineurin inhibitors, oral semisynthetic tetracyclines.

Grade II: hydrocortisone 1% or 2.5% cream +/- clindamycin 1% gel as well as a 4-week course of an oral tetracycline antibiotic.

Grade III: addition of oral corticosteroids.

References

Heidary N, Naik H, Burgin S. Chemotherapeutic agents and the skin: an update. *J Am Acad Dermatol* 2008;58:545-70.

Deslandres M, Sibaud V, Chevreau C, et al. Cutaneous side effects associated with epidermal growth factor receptor and tyrosine kinase inhibitors (Article in French). *Ann Dermatol Venereol* 2008;Spec No 1:16-24.

Tan AR, Steinberg SM, Parr AL, et al. Markers in the epidermal growth factor receptor pathway and skin toxicity during erlotinib treatment. *Ann Oncol* 2008;19:185-90.

Schallock PC, Zug KA. Acneiform reaction to erlotinib. *Dermatitis* 2007;18:230-1.

Bragg J, Pomeranz MK. Papulopustular drug eruption due to an epidermal growth factor receptor inhibitors, erlotinib and cetuximab. *Dermatol Online J* 2007;13:1.

Shih HC, Hsiao YP, Wu ME, et al. Gefitinib-induced acute generalized exanthematous pustulosis in two patients with advanced non-small-cell lung cancer. *Br J Dermatol* 2006;155:1101-2.

Guillot B, Bessis D. Clinical appearance and management of cutaneous side effects of EGF receptor inhibitors (Article in French). *Ann Dermatol Venereol* 2006;133:1017-20.

Etanercept

A human tumor necrosis factor p75 Fc fusion protein used for the treatment of active rheumatoid arthritis when there is an inadequate response to disease-modifying antirheumatic drugs (DMARDs).

■ Clinical manifestations

- **Injection-site reactions:** frequent in the first month, transitory (2/3 days), may disappear (2 months); recall reaction; eosinophilic cellulitis-like reaction.
- **Others:** maculopapular rash, lupus erythematosus (discoid, subacute or systemic), psoriasis (aggravation or de novo), palmo-plantar pustulosis, lichen planus, vasculitis, granulomatous tattoo reaction, granuloma annulare, alopecia areata, interstitial granulomatous dermatitis.

■ Diagnostic methods

None.

■ Mechanisms

Unknown.

■ Management

Avoidance.

References

Lebas D, Staumont-Sallé D, Solau-Gervais E, et al . Cutaneous manifestations during treatment with TNF- alpha blockers : 11 cases (Article in French). *Ann Dermatol Venereol* 2007;134:337-42.

de Gannes GC, Ghoreishi M, Pope J, et al. Psoriasis and pustular dermatitis triggered by TNF alpha inhibitors in patients with rheumatologic conditions. *Arch Dermatol* 2007;143:223-31.

Soliotis F, Glover M, Jawad ASM. Severe skin reaction after leflunomide and etanercept in a patient with rheumatoid arthritis. *Ann Rheum Dis* 2002;61:850-1.

Livermore PA, Murray KJ. Anti-tumour necrosis factor therapy associated with cutaneous vasculitis. *Rheumatology* 2002;41:1450-2.

Galaria NA, Werth VP, Schumacher HR. Leucocytoclastic vasculitis due to etanercept. *J Rheumatol* 2000;7:2041-4.

Ibritumomab-Tiuxetan

A CD 20 monoclonal antibody used in the treatment of relapsed or refractory follicular non-Hodgkin lymphoma after treatment with rituximab.

■ Incidence

< 1%.

■ Clinical manifestations

- **General:** anaphylactic shock.
- **Cutaneous:** pruritus, rash, urticaria, angioedema, peripheral edema, purpura (with thrombocytopenia), serum sickness like reaction (in association with rituximab), Stevens-Johnson syndrome (in association with rituximab).

■ Diagnostic methods

Human anti-mouse antibody (HAMA): elevated.

■ Mechanisms

Unknown.

■ Management

Avoidance.

References

Jankowitz R, Joyce J, Jacobs SA. Anaphylaxis after administration of ibritumomab tiuxetan for follicular non-Hodgkin lymphoma. *Clin Nucl Med* 2008;33:94-6.

Demonaco NA, Jacobs SA. Serum sickness in a patient with follicular lymphoma after rituximab and radioimmunotherapy with ibritumomab tiuxetan. *Clin Nucl Med* 2007;32:933-4.

Infliximab

Infliximab is a chimeric monoclonal antibody directed against tumor necrosis factor alpha that has been shown to improve chronic refractory and fistulating Crohn's disease, psoriasis and rheumatoid arthritis.

I Incidence

Allergic reactions: > 1/1000.

Anaphylactic shock: > 1/10,000 < 1/1000.

Serum sickness: > 1/10,000 < 1/1000.

Vasculitis: > 1/10,000 < 1/1000.

I Clinical manifestations (occurring after the first to eleventh dose)

The most commonly reported side effects are upper respiratory tract symptoms, mild rash and itching beginning within 24 hr of infusion and usually resolving in a few days without need for treatment.

- **General:** hypotension, dizziness, tachycardia, red man syndrome, fever.
- **Cutaneous:** injection-site reactions: frequent in the first month, transitory (2/3 days), may disappear (two months); urticaria, angioedema, delayed rash, lupus erythematosus, psoriasis (exacerbation or de novo), palmo-plantar pustulosis, erythema multiforme, vasculitis, lichenoid reaction, granuloma annulare, interstitial granulomatous dermatitis.
- **Respiratory:** chest tightness, dyspnea, laryngeal spasm, hypoxemia.
- **Digestive:** nausea, dysphagia, vomiting.

I Diagnostic methods

Allergy tests usually not done.

Intradermal skin tests when performed are negative.

I Mechanisms

Acute infusion reactions (chills, nausea, dyspnea, headache, fever) are mostly not IgE-mediated. They occur in 3 to 5% of treated patients and the incidence can be reduced by slowing the infusion rate. They may be related to activation of cells (by Fc-IgG receptors) or by activation of the complement system via immune complexes.

I Management

Premedication with antihistamines and corticosteroids is ineffective.
Switch to another biological agent: etanercept, adalimumab.

Desensitization in adults and children is usually successful.

References

- Pichler WJ, Campi P. Adverse side effects to biological agents. In: Pichler WJ, ed. *Drug Hypersensitivity*. Basel:Karger, 2007:151-65.
- Lebas D, Staumont-Sallé D, Solau-Gervais E, et al. Cutaneous manifestations during treatment with TNF- alpha blockers : 11 cases (Article in French). *Ann Dermatol Venereol* 2007;134:337-42.
- Ramos-Casals M, Brito-Zeron P, Munoz S, et al. Autoimmune diseases induced by TNF-targeted therapies: analysis of 232 cases. *Medicine* 2007;86:242-51.
- Deng A, Harvey V, Sina B, et al. Interstitial granulomatous dermatitis associated with the use of tumor factor alpha inhibitors. *Arch Dermatol* 2006;142:198-202.
- Lelong J, Duburque C, Fournier C. Desensitization to infliximab in patients with Crohn's disease (Article in French). *Rev Mal Respir* 2005;22:239-46.
- Stalmach A, Giese T, Schmidt C, et al. Severe anaphylactic reaction to Infliximab: successful treatment with adalimumab-report of a case. *Eur J Gastroenterol Hepatol* 2004;16:627-30.

Interferon

Interferon alpha is used in the management of chronic hepatitis B, leukaemia, multiple myeloma and follicular lymphoma.

Interferon beta is used in the treatment of multiple sclerosis.

Interferon gamma is used in the treatment of chronic septic granulomatosis.

I Incidence

Flu like symptoms and localized inflammatory skin lesions at the site of injection are frequent (IFN alpha).

I Clinical manifestations

- **General:** anaphylactic shock (IFN B), flu like symptoms (myalgia, arthralgia, fever).
- **Cutaneous:** maculopapular rash, pruritus, xerosis, urticaria, angioedema (sometimes severe and generalized), lichen planus (cutaneous and mucosal), lupus erythematosus, psoriasis-induced or aggravation, bullous auto-immune dermatitis (pemphigus), sarcoidosis (cutaneous and systemic), vasculitis (cutaneous and systemic), Raynaud's phenomenon, fixed drug eruption, photosensitivity, vitiligo, injection site reactions (erythema, pruritus, pain, necrosis, induration, vasculitis, eczematous eruption, panniculitis). In cases of necrosis: investigation of risk factors for thrombophilia and factors reducing microcirculation (drug toxic). Sudation, acne, alopecia, stomatitis and xerostomia.
- **Autoimmune disorders:** thrombocytopenia, hemolytic anemia, thyroid diseases, pernicious anemia, IgA nephropathy.

I Diagnostic methods

Skin tests

Intradermal test positive with IFN B1b, negative with IFN B1a, in a patient with anaphylactic shock.

I Mechanisms

High cytokine and cytokine release syndrome (flu like syndrome).

Autoimmune and autoinflammatory mechanism.

IgE-mediated hypersensitivity may be implicated in a few cases.

I Management

Pegylated interferon (IFN)-alpha-2b with ribavirin has recently replaced standard IFN alpha for the treatment of chronic hepatitis C. Severe allergic eczema may occur after switching to daily conventional alpha-interferon. Another possibility is to rechallenge the patient with pegylated IFN alpha 2b + ribavirin combination therapy with pre-administration of oral prednisolone, antihistamine and topical corticosteroids.

References

- Serarslan G, Okuyucu E, Melek I, et al. Widespread maculopapular rash due to intramuscular interferon β -1 a during the treatment of multiple sclerosis. *Mult Scler* 2008;14:259-61.
- Hashimoto Y, Kanto H, Itoh M. Adverse skin reactions due to pegylated interferon alpha 2b plus ribavirin combination therapy in a patient with chronic hepatitis C virus. *J Dermatol* 2007;34:577-82.
- Veldt BJ, Schalm SW, Janssen ML. Severe allergic eczema due to pegylated alpha-interferon may abate after switching to daily conventional alpha-interferon. *J Clin Gastroenterol* 2007;41:432.
- Bagheri H, Fouladi A, Barange K. Follow up of adverse drug reactions from peginterferon alfa-2b-ribavirin therapy. *Pharmacotherapy* 2004;24:1546-53.
- Brown DL, Login IS, Borish L, et al. An urticarial IgE-mediated reaction to interferon B 1b. *Neurology* 2001;56:1416-7.
- Corona T, Leon C, Ostrowsky-Zeichner L. Severe anaphylaxis with recombinant interferon B. *Neurology* 1999;52:425.

Interleukin 2

A cytokine used in the treatment of renal cancer and metastatic melanoma.

I Incidence

Rash is frequent.

I Clinical manifestations

- **Cutaneous:** rash (frequent, mild with burning, pruriginous erythema or severe with necrotic lesions and blisters), exfoliative dermatitis, urticaria (rare occurring at the end of a treatment cycle), angioedema, purpuric eruption, reactivation of eczema, injection site reactions, erythema multiforme, Stevens-Johnson syndrome, toxic epidermal necrolysis, acute generalized exanthematous pustulosis, vitiligo, vasculitis (cutaneous and systemic), pemphigus, linear IgA bullous dermatitis, psoriasis (exacerbation), edema (due to vascular leak syndrome).

- **Others:** sudation, alopecia, stomatitis.

I Diagnostic methods

Skin tests

Negative in 2 patients with urticaria.

I Mechanisms

Unknown.

I Management

Urticaria did not worsen or occur consistently with repeated courses of interleukin 2 and anaphylaxis was not observed in any patient.

References

Logan TF, Strippoli G, Levine MI. Urticaria and angioedema in renal cell cancer patients treated with IL-2. *Cancer Invest* 2007;11:1-5.

Larbre B, Nicolas JF, Sarret Y, et al. Interleukin-2 immunotherapy and cutaneous manifestations (Article in French). *Ann Dermatol Venereol* 1993;120:528-33.

Wolkenstein P, Chosidow O, Weschler J, et al. Cutaneous side effects associated with interleukin 2 administration for metastatic melanoma. *J Am Acad Dermatol* 1993;28:66-70.

Muromonab

Muromonab-CD3 (OKT3) is a murine IgG2 antibody used to reverse acute renal graft rejection.

■ Clinical manifestations

Cytokine release syndrome: flush, arthralgia, capillary leak syndrome, pulmonary edema, encephalopathy, aseptic meningitis, pyrexia.

Anaphylactic shock.

■ Diagnostic methods

IgG and IgE anti-OKT3 antibodies are detected in serum samples after anaphylactic shock.

■ Mechanisms

IgE-mediated hypersensitivity (anaphylactic shock).

■ Management

Desensitization.

References

Pichler WJ, Campi P. Adverse side effects to biological agents. In: Pichler WJ, ed. *Drug Hypersensitivity*. Basel: Karger, 2007:151-65.

Berkowitz RJ, Possidente CJ, Mc Pherson BR, et al. Anaphylactoid reaction to muromonab-CD3 in a pediatric renal transplant recipient. *Pharmacotherapy* 2000;20:100-4.

Georgitis JW, Browning MC, Steiner D, et al. Anaphylaxis and desensitization to the murine monoclonal antibody used for renal graft rejection. *Ann Allergy* 1991;66:343-7.

Omalizumab

A recombinant humanized monoclonal antibody used in the management of severe asthma.

I Incidence

Anaphylaxis reporting rate: 0.09% of patients.

I Clinical manifestations

- **General:** anaphylactic shock, occurring in 61% of cases in the first 2 hours after one of the first 3 doses; 14% of the events occurred within 30 minutes after the fourth or later dose. Serum sickness, laryngeal edema, angioedema.
- **Cutaneous:** injection site reaction, urticaria (sometimes severe), laryngeal edema, facial erythema and edema, angioedema, pruritus, rash, serum sickness.

I Diagnostic methods

Skin tests

Prick tests: negative at 150 mg/ml (2 cases).

Intradermal tests: positive in one patient with anaphylaxis at 0.15 mg/ml.

Intradermal tests to polysorbate: positive in one patient.

Antibodies.

IgE and IgG anti-omalizumab negative in 2 patients.

I Mechanisms

IgE-mediated hypersensitivity in some cases.

Role of excipient (polysorbate).

I Management

Minimal observation period of 2 hours for the first 3 injections and 30 minutes for the subsequent injections.

References

Omalizumab: anaphylactic shock sometimes occurs more than one hour after the injection. Prescrire Int 2008;17:22.

Barry PJ, O'Mahony A, Finnegan C, et al. Delayed allergic reactions to omalizumab : are patients reporting all cases? J Allergy Clin Immunol 2008;121:785-6.

Cox L, Platts-Mills TA, Finegold I, et al. American Academy of Allergy, Asthma & Immunology/American College of Allergy, Asthma and Immunology joint task force report on omalizumab-associated anaphylaxis. J Allergy Clin Immunol 2007;120:1373-7.

Pilette C, Coppens N, Houssiau FA. Severe serum sickness-like syndrome after omalizumab therapy for asthma. J Allergy Clin Immunol 2007;120:972-3.

Price KS, Hamilton RG. Anaphylactoid reactions in two patients after omalizumab administration after successful long-term therapy. Allergy Asthma. Proc 2007;28:313-9.

Lieberman P. The unusual suspects: a surprise regarding reactions to Omalizumab. Allergy Asthma Proc 2007;28:259-61.

Limb SL, Starke PR, Lee CE, et al. Delayed onset and protracted progression of anaphylaxis after omalizumab administration in patients with asthma. J Allergy Clin Immunol 2007;120:1378-81.

Dreyfus DH, Randolph CC. Characterization of an anaphylactoid reaction to Omalizumab. Ann Allergy Asthma Immunol 2006;96:624-7.

Rituximab

A human-murine monoclonal antibody targeted against the CD 20 antigen on the surface of B lymphocytes; used in the treatment of rheumatoid arthritis, acute immune polyneuropathy, autoimmune thrombocytopenia, chronic lymphocytic leukaemia and follicular non-Hodgkin's lymphoma.

■ Incidence

Acute infusion reactions up to 77% (first infusion), 30% (fourth infusion), 14% (eighth infusion).

Severe < 10%.

■ Risk factors

Serum sickness: autoimmune polyneuropathy, autoimmune thrombocytopenia.

Vasculitis, Stevens-Johnson syndrome, leukaemia and non-Hodgkin's lymphoma.

Hypersensitivity to murine proteins.

■ Clinical manifestations

- **General:** infusion-related reactions (fever, nausea, headache), sometimes severe, notably in patients with high number of circulating tumor cells (occurring 30-120 min after starting first infusion). Serum sickness (fever, rash, polyarthritis).

- **Cutaneous:** pruritus, rash, urticaria, angioedema, night sweat (15% of cases), peripheral and facial edema, injection-site reaction, Stevens-Johnson syndrome, toxic epidermal necrolysis, vesiculo-bullous dermatitis, lichenoid dermatitis, alopecia, mucosal ulcerations, vasculitis (sometimes leucocytoclastic).

- **Respiratory:** acute respiratory distress syndrome (hypoxia, pulmonary infiltrates), myocardial infarction, cardiogenic shock, reduction in cardiac function (TGF beta levels elevated after rituximab administration promoting the growth of reticulin fiber in cardiac muscles).

- **Others:** gastrointestinal perforation.

■ Diagnostic methods

Human anti-mouse (HAMA) and human anti-chimeric (HACA) antibodies are seldom found.

■ Mechanisms

Cytokine release from targeted cells.

Complement activation leads to the release of TNF alpha, IL 6 and IL 8.

The underlying disease (autoimmune disease or chronic lymphocytic leukaemia and follicular non-Hodgkin's lymphoma) may also play a role in the development of delayed or cutaneous reactions.

Reduced clearance of immune complexes and/or increased production of autoantibodies can play a role in serum sickness (high titres of antibodies directed against murine Fab fragments were detected in one case).

I Management

Avoidance, but most patients with non-life-threatening reactions are able to complete the full course of therapy.

Desensitization is possible and effective (twelve steps in 351 min).

Corticosteroids in serum sickness.

References

Castells M. *Drug desensitization in oncology: chemotherapy agents and monoclonal antibodies*. In Pichler WJ (ed), *Drug Hypersensitivity*, Basel, Karger, 2007, pp 413-25.

Todd DJ, Helfgott SM. *Serum sickness following treatment with rituximab*. *J Rheumatol* 2007;34:430-3.

Disperati P, Hicks LK, Buckstein R. *Rituximab-induced serum sickness in a patient with follicular lymphoma*. *Leuk Lymphoma* 2007;48:1633-5.

Scheinfeld N. *A review of rituximab in cutaneous medicine*. *Dermatol Online J* 2006;12:3.

Kanamori H, Tsutsumi Y, Mori A, et al. *Delayed reduction in left ventricular function following treatment of non-Hodgkin's lymphoma with chemotherapy and rituximab, unrelated to acute infusion reaction*. *Cardiology* 2006;105:184-7.

Millward PM, Bandarenko N, Chang PP, et al. *Cardiogenic shock complicates successful treatment of refractory thrombotic thrombocytopenia purpura with rituximab*. *Transfusion* 2005;45:1481-6.

Trastuzumab

A humanized monoclonal antibody to HER2 used in breast cancer treatment.

■ Incidence

Acute infusion reactions: 40% (severe < 1%).

■ Clinical manifestations (first dose to after 9 months of treatment)

- **General:** general fatigue, hypotension, headache, back pain.
- **Cutaneous:** rash (frequent), pruritus, angioedema (less frequent than rash), peripheral edema, photosensitivity (in association with paclitaxel), hand-foot syndrome (in association with taxol).
- **Respiratory:** throat tightness, hypoxia, acute hypersensitivity pneumonitis and respiratory failure, BOOP.

■ Diagnostic methods

Skin tests

Intradermal test: two positive cases.

No specific IgE found.

■ Mechanisms

Cytokine release (acute infusion reactions).
Possible IgE-mediated hypersensitivity in some cases.

■ Management

Desensitization is usually successful (12 steps in 350 min).

References

- Castells M. Drug desensitization in oncology: chemotherapy agents and monoclonal antibodies. In: Pichler WJ, ed. *Drug Hypersensitivity*. Basel: Karger, 2007:413-25.
- Cohen AD, Mermershtain W, Geffen DB, et al. Cutaneous photosensitivity induced by paclitaxel and trastuzumab therapy associated with aberrations in the biosynthesis of porphyria. *J Dermatolog Treat* 2005;16:19-21.
- Tada K, Ito Y, Hatake K. Severe infusion reaction induced by trastuzumab: a case report. *Breast Cancer* 2003;10:167-9.
- Melamed J, Stahlman JE. Rapid desensitization and rush immunotherapy to trastuzumab (herceptin). *J Allergy Clin Immunol* 2002;110:813-4.
- Merimsky O, Inbar MJ. Herceptin-taxol related hand and foot syndrome. *Isr Med Assoc J* 2000;2:786.

XIV

DRUGS USED IN NEUROLOGY AND RHEUMATOLOGY

Allopurinol

An analogue of hypoxanthine, inhibiting xanthine oxidase; it is an effective urate-lowering drug (cornerstone in the treatment of hyperuricaemia and gout).

■ Incidence

Skin rash: 2%.

Allopurinol hypersensitivity syndrome: 0.4% (mortality 25%).

■ Risk factors

Impaired renal excretion or concomitant thiazide therapy (hypersensitivity syndrome).

Chinese ethnicity (HLA-B* 5801).

Inappropriately high allopurinol dosage.

■ Clinical manifestations

Allopurinol hypersensitivity syndrome (developing 2 to 6 weeks after initiation of treatment)

Criteria for diagnosis:

- 1• Clear history of exposure to allopurinol.
- 2• Lack of exposure to another drug which may have caused a similar clinical picture.
- 3• Clinical picture including:
 - a) at least 2 of the major criteria
 - worsening renal function (84%)
 - acute hepatocellular injury (88%)
 - rash (93.1%): toxic epidermal necrolysis (25.7%) erythema multiforme (8.9%), diffuse maculopapular rash (53.5%), exfoliative dermatitis (20.8%)

OR

- b) one of the major criteria + at least one of the following minor criteria
 - fever (95%)
 - eosinophilia (60%)
 - leukocytosis (40%)

Lymphadenopathy is generally absent.

• **Cutaneous manifestations:** pruritus, rash, exfoliative dermatitis, purpura, urticaria, angioedema, fixed drug reaction (rare), acute generalized exanthematous pustulosis (rare), generalized eosinophilic pustular folliculitis (rare), erythema multiforme (rare).

Other severe cutaneous reactions: Stevens-Johnson syndrome and toxic epidermal necrolysis (allopurinol is the most common cause of this reaction in Europe and Israël); systemic vasculitis.

■ Diagnostic methods

Liver biopsy: T lymphocyte infiltration, granulomas, focal necrosis of hepatocytes.

Renal biopsy: linear deposits of IgG and complement along the glomerule basement membrane; C3 deposits along tubular basal membrane, mesangium and arterioles.

Lymphocyte stimulation test: positive with oxypurinol but not allopurinol in 3 patients with allopurinol hypersensitivity syndrome.

Interferon gamma release from peripheral blood T lymphocytes.

■ Mechanisms

- Accumulation of oxypurinol (principal metabolite of allopurinol) due to renal impairment or co-administration of thiazide diuretics.
- Genetic factors
- Abnormal T lymphocyte-mediated immune response to oxypurinol and allopurinol.
- Formation of immune complexes.

■ Management

Allopurinol administration should be initiated with clear indications. The dosage must be adapted to the creatinine clearance level.

Oxypurinol at a dosage of 100-600 mg/day has been used to treat allopurinol-sensitive individuals but cross-reactivity with allopurinol has been reported in up to 40% of the patients.

Rasburicase, which converts hypoxanthine and xanthine into allantoin and is a more soluble molecule that is easily cleared by the kidneys, is used in chemotherapy induced-hyperuricemia.

Benzbromarone retains its uricosuric properties in patients who have mild to moderate renal impairment.

Desensitization

Indications

- patients with gout and renal failure and those requiring concomitant cardioprotective low dose aspirin which renders uricosurics ineffective,
- patients with gout, over-production hyperuricemia, hyperuricosuria and nephrolithiasis in whom uricosurics can increase risk of stone formation, renal colic, and renal failure
- patients with gout and “underexcretion” hyperuricemia who are either allergic or intolerant to both probenecid and sulfinpyrazone,
- patients with malignancy-associated hyperuricemia due to cytolytic therapy for myeloproliferative or lymphoproliferative disorders; the resulting massive uricosuria precludes the use of a uricosuric agent.

Desensitization is not recommended in patients with previous Stevens-Johnson syndrome, toxic epidermal necrolysis or other life-threatening reactions to this drug.

1• Fixed drug eruption (50 mg of allopurinol powder dissolved in 500 ml of distilled water with 14/1000 sodium bicarbonate)

Day 1: 10 µg, 20 µg, 30 µg Day 2: 40 µg, 50 µg, 60 µg

Day 3: 70 µg, 80 µg, 90 µg Day 4: 100 µg, 200 µg, 400 µg

Day 5: 600 µg, 800 µg, 1mg Day 6: 2 mg, 4 mg, 8 mg

Day 7: 16 mg, 25 mg, 35 mg Day 8: 50 mg

Day 9: 75 mg Day 10: 100 mg

Day 11: 125 mg Day 12: 150 mg

Day 13: 175 mg Day 14: 200 mg

Day 15: 250 mg Day 16: 300 mg

2• Oral desensitization in cases with minor rash (renal insufficiency, chronic tophaceous gouty arthritis)

Day 1 to 3: 50 µg Day 4 to 6: 100 µg

Day 7 to 9: 200 µg Day 10 to 12: 500 µg

Day 13 to 15: 1 mg Day 16 to 18: 5 mg

Day 19 to 21: 10 mg Day 22 to 24: 25mg

Day 25 to 27: 50 mg Day 28 and nexts: 100 mg

3• Intravenous desensitization (when oral desensitization fails; in less than 12 hours)

- 0.1 µg, 1 µg, 10 µg, 50 µg, 100 µg, 500 µg at 15 minute intervals

- 1 mg, 2 mg, 5 mg, 10 mg, 20 mg, 50 mg, 100 mg at 30 minute intervals

Desensitization can produce life-threatening reactions.

References

Halevy S, Ghislain PD, Mockenhaupt M, et al. Allopurinol is the most common cause of Stevens-Johnson syndrome and toxic epidermal necrolysis in Europe and Israël. *J Am Acad Dermatol* 2008;58:25-32.

Lee HY, Ariyasinghe JT, Thirumoorthy T. Allopurinol hypersensitivity syndrome: a preventable severe cutaneous adverse reaction? *Singapor Med J* 2008;49:384-7.

Gutierrez-Macias A, Lizarralde-Palacios E, Martinez-Odriozola P, et al. Fatal allopurinol hypersensitivity syndrome after treatment of asymptomatic hyperuricaemia. *BMJ* 2005;331:623-4.

Nitti F, Fumagalli M, Incorvaia C. Rush desensitization to allopurinol. *Allergy* 2003;58:690.

Lun K, Harley W. Allopurinol-induced pustular eruption: an unusually mild case. *Australas J Dermatol* 2002;43:140-3.

Fame AG, Dunne SM, Iazzetta J, et al. Efficacy and safety of desensitization to allopurinol following cutaneous reactions. *Arthritis Rheum* 2001;44:231-8.

Bupropion

A selective serotonin re-uptake inhibitor antidepressant used as a smoking cessation aid.

■ Incidence

Serum sickness like reactions 37 reports (→ 2001).
Urticaria and rash: 1 to 4%.

■ Clinical manifestations

- **General:** serum sickness like reaction, developing 10-20 days after starting treatment: urticaria, arthralgia, fever, lymphadenopathy, lasting 4 to 14 days.
- **Cutaneous:** pruritus, urticaria, angioedema rash, generalized pustular and erythrodermic psoriasis, flare of cutaneous lupus erythematosus, erythema multiforme.

■ Diagnostic methods

No evidence of complement pathway activation.

■ Mechanisms

Unknown.

■ Management

Avoidance.

References

- Hack S. Pediatric bupropion-induced serum sickness-like reaction. *J Child Adolesc Psychopharmacol* 2004;14:478-80.
- Fays S, Tréchet P, Schmutz JL, et al. Bupropion and generalized acute urticaria: eight cases. *Br J Dermatol* 2003;148:177-8.
- Cox NH, Gordon PM, Dodd H. Generalized pustular and erythrodermic psoriasis associated with bupropion treatment. *Br J Dermatol* 2002;146:1061-3.
- McCullom RA, Elbe DH, Ritchie AH. Bupropion-induced serum sickness-like reaction. *Ann Pharmacother* 2000;34:471-3.

Carbamazepine

A drug widely used in the treatment of epilepsy, trigeminal neuralgia and affective disorders.

■ Incidence

Cutaneous reactions: 3%.

Toxic epidermal necrolysis: 0.6% in epileptic children.

Stevens-Johnson syndrome/toxic epidermal necrolysis: 14/100,000 users.

Anticonvulsant hypersensitivity syndrome: 1/1,000 to 1/10,000 exposures.

■ Risk factors

Elderly black men.

HLA B*1502 (100% association with Stevens-Johnson syndrome in Hong Kong Chinese).

HSP 70 gene variants (located in the MHC class III region).

Flu-like illness within the previous 6 weeks.

■ Clinical manifestations

Anticonvulsant hypersensitivity syndrome (mortality 20%).

- maculopapular rash developing > 3 weeks after starting the drug (84 to 100% of cases)
 - fever > 38°C (65 to 84% of cases)
 - prolonged clinical syndrome after discontinuation of the drug
 - liver abnormalities (ALT > 100 U/l) (66 to 73% of cases)
 - leukocyte abnormalities: leukocytosis > $11 \times 10^9/l$ (11 to 19%) or
 - atypical lymphocytes (>5%) or eosinophilia > $1.5 \times 10^9/l$ (53 to 92% of cases)
 - lymphadenopathy (22 to 53% of cases)
 - HHV-6 reactivation (increase in HHV-6 IgG titers detected in the 2nd to 3rd weeks after onset of symptoms)
 - cardiac manifestations (8 to 9% of cases)
 - various forms of renal involvement: tubulointestinal nephritis to granulomatous necrotizing angitis.
- **Cutaneous:** rash (frequent), erythroderma, exfoliative dermatitis, pruritus, urticaria (sometimes severe), erythema multiforme, Stevens-Johnson syndrome, toxic epidermal necrolysis, lupus erythematosus, purpura (rare with sometimes Henoch-Schönlein purpura), photosensitivity (rare), acute generalized exanthematous pustulosis (rare), psoriasiform eruption (rare), linear IgA bullous dermatitis (rare), fixed drug eruption (rare), lichenoid eruption (rare), vasculitis (rare), pseudolymphoma, porphyria.
- **Others:** dyserythropoietic anemia, cough, dyspnea, hypersensitivity pneumonitis.

■ Diagnostic methods

Skin tests

Patch tests: 1% in pet (or 5% pet and aq with CBZ and the main metabolite 10-11 CBZ epoxide)

Lymphocyte transformation test.

Auto-antibody (indirect immunofluorescence and immunoblotting) to a 190 kDa antigen in one patient with hypersensitivity syndrome.

I Mechanisms

Conversion of the carbamazepine metabolite, 3-hydroxycarbamazepine (3-OHCBZ) to the catechol, 2,3-dihydroxycarbamazepine (2,3 diOHCBZ) followed by subsequent oxidation to a reactive o-quinone species has been proposed as a possible bioactivation pathway in the pathogenesis of carbamazepine induced hypersensitivity.

Deficiency or abnormality of the epoxide hydrolase enzyme.

Associated reactivation of herpes type viruses, with two main hypothesis: 1) stimulation of T cells by the drug, leading to reactivation of herpes virus harbored in T cells; 2) clinically unapparent reactivation of herpes virus occurs. The virus-stimulated T cells show substantial cross-reactivity with certain drugs; administration of these drugs leads to an expansion of the specific T cells, which continues after cessation of the drug due to the persistence of the viral antigens. Aromatic anticonvulsants are metabolized to hydroxylated aromatic compounds such as arene oxide. If detoxification of this toxic metabolite is insufficient the toxic metabolite may bind to cellular macromolecules causing cellular necrosis or a secondary immunological response. T cells from patients sensitized to anticonvulsants are activated in vivo and in vitro CD4+ and CD8+ infiltrate the affected skin.

Ethnic predisposition.

Arene oxides (toxic intermediaries in the metabolism of anticonvulsant drugs) can accumulate and bind to macromolecules and act as prohapten capable of binding to T cells and initiating an immune response which can lead to systemic reactions.

Drug-specific MHC class I restricted perfarin/granzyme mediated cytotoxicity (toxic epidermal necrolysis).

I Management

Cross-reactivity among aromatic anticonvulsants (phenobarbital, phenytoine, carbamazepine) is high (40 to 80%).

Family members of patients with anticonvulsant hypersensitivity syndrome should be educated that they may be at increased risk for developing AHS if they use aromatic anticonvulsant drugs.

Treatment of hypersensitivity syndrome: steroids 1 to 1.5 mg/kg; intravenous immunoglobulins, plasma exchange.

References

- Pearce RE, Lu W, Wang Y, et al. Pathways of carbamazepine bioactivation in vitro III: the role of human cytochrome P450 enzymes in the formation of 2,3-dihydroxycarbamazepine. *Drug Metab Dispos* 2008;36:1637-49.
- Chessman D, Kostenko L, Lethborg T, et al. Human leukocyte antigen class I-restricted activation of CD8 + T cells provides the immunogenetic basis of a systemic drug hypersensitivity. *Immunity* 2008;28:822-32.
- Shiohara T, Takahashi R, Kano Y. Drug-induced hypersensitivity syndrome and viral reactivation. In: Pichler WJ, ed. *Drug Hypersensitivity*. Basel: Karger, 2007:251-266.
- Bohan KH, Mansuri TF, Wilson NM. Anticonvulsant hypersensitivity syndrome: implications for pharmaceutical care. *Pharmacotherapy* 2007;27:1425-39.
- Tohyama M, Hashimoto K, Yasukawa M, et al. Association of human herpesvirus 6 reactivation with the flaring and severity of drug-induced hypersensitivity syndrome. *Br J Dermatol* 2007;157:934-40.
- Wu Y, Farrell J, Pirmohamed M, et al. Generation and characterization of antigen-specific CD4+, CD8+, and CD4+CD8+T-cell clones from patients with carbamazepine hypersensitivity. *J Allergy Clin Immunol* 2007;119:973-81.
- Alfirevic A, Mills T, Harrington P, et al. Serious carbamazepine-induced hypersensitivity reactions associated with the HSP70 gene cluster. *Pharmacogenet Genomics* 2006;16:287-96.
- Motta E, Kazibutowska Z, Lorek A, et al. Carbamazepine-induced systemic lupus erythematosus-a case report. *Neurol Neurochir Pol* 2006;40:151-5.
- Devi K, George S, Criton S, et al. Carbamazepine-the commonest cause of toxic epidermal necrolysis and Stevens-Johnson syndrome: a study of 7 years. *Indian J Dermatol Venereol Leprol* 2005;71:325-8.
- Allam JP, Paus T, Reichel C, et al. DRESS syndrome associated with carbamazepine and phenytoin. *Eur J Dermatol* 2004;14:339-42.
- Lee AY, Choi J, Chey WY. Patch testing with carbamazepine and its main metabolite carbamazepine epoxide in cutaneous adverse drug reactions to carbamazepine. *Contact Dermatitis* 2003;48:137-9.

Clozapine

“Gold standard” treatment for schizophrenia patients who are resistant to neuroleptics.

■ Incidence

Eosinophilia: 13%.

Myocarditis: 213 cases/50 deaths until 2002.

■ Clinical manifestations

- **Cutaneous:** urticaria, angioedema, maculopapular rash, acute generalized exanthematous pustulosis, photosensitivity, lupus erythematosus (induction or exacerbation), rash, mucosal manifestations.
- **Cardiovascular:** hypersensitivity myocarditis (85% occurring the first two months of therapy), pericarditis, pericardial tamponade, cardiomyopathy.
- **Respiratory:** bronchospasm, extrinsic allergic alveolitis.
- **Haematological:** eosinophilia, agranulocytosis.
- **Other:** acute interstitial nephritis.

■ Diagnostic methods

One case of myocarditis with endomyocardial biopsy: massive myocardial infiltrates mainly represented by degranulated eosinophils associated with fraying of the adjacent myocytes.

■ Mechanisms

Unknown.

■ Management

Avoidance.

Cross-reactivity with chlorpromazine is possible.

Switch to quetiapine.

References

Zipris P, Melamed Y, Weizman A, et al. Clozapine-induced eosinophilia and switch to quetiapine in a patient with chronic schizophrenia with suicidal tendencies. *Isr J Psychiatry Relat Sci* 2007;44:54-6.

Mishra Bn, Sahoo S, Sarkar S, et al. Clozapine-induced angioneurotic edema. *Gen Hosp Psychiatry* 2007;269:78-80.

Rami AF, Barkan D, Mevorach D, et al. Clozapine-induced systemic lupus erythematosus. *Ann Pharmacother* 2006;40:983-5.

Bhatti MA, Zander J, Reeve E. Clozapine-induced pericarditis, pericardial tamponade, polyserositis, and rash. *J Clin Psychiatry* 2005;66:1490-1.

Pieroni M, Cavallaro R, Chimenti C, et al. Clozapine-induced hypersensitivity myocarditis. *Chest* 2004;126:1703-5.

Kuintana J, Shah B, Guze B. Clozapine-chlorpromazine allergic cross-reactivity in a psychotic patient with asymptomatic AIDS. *Biol Psychiatry* 1996;40:1185-6.

Howanitz E, Pardo M, Losonczy M. Photosensitivity to clozapine *J Clin Psychiatry* 1995;56:589.

D-penicillamine

D-penicillamine is the product of acid hydrolysis of penicillin. It is used in the treatment of Wilson's disease, cystinuria and heavy metal poisoning.

I Incidence

High.

50% of patients will have an adverse drug reaction during the first 6 months of therapy (600 mg/day) and about 1/4 to 1/3 will discontinue therapy.

I Clinical manifestations

- **Cutaneous:** maculopapular rash and pruritus : frequent (early reaction), elastosis perforans serpiginosa, cutis laxa, pseudoxanthoma elasticum (classic), pemphigus (classic and frequent) and less frequent bullous pemphigoid, epidermolysis bullosa acquisita-like reaction, cicatricial pemphigoid, lupus erythematosus, dermatomyositis and polymyositis, vasculitis (sometimes ANCA positive), severe and life-threatening erythema multiforme, Stevens-Johnson syndrome, toxic epidermal necrolysis (rare), lichenoid eruption, oral manifestations, contact allergy (eye drops).
- **Respiratory:** obstructive bronchiolitis, pneumonitis, asthma.
- **Renal:** glomerulonephritis with membrane proliferation.
- **Hematological:** neutropenia, thrombocytopenia, aplastic anemia.
- **Autoimmune diseases:** myasthenia, Goodpasture's syndrome.

I Diagnostic methods

No *in vivo* or *in vitro* diagnostic methods are currently available, other than the lymphocyte stimulation test which may be positive in some cases with glomerulonephritis and polymyositis.

I Mechanisms

Unknown.

I Management

Severe vasculitis: corticosteroids, plasmapheresis, hemodialysis or cyclophosphamide.

Use reduced dose of D-penicillamine in children with mild to moderate lead poisoning (15 mg/kg/day instead of 25-30 mg/kg/day).

If severe glomerulonephritis occurs, do not attempt to re-administer the drug unless no other therapeutic option is available.

If use is absolutely necessary, first perform the following desensitization to avoid the risk of a severe delayed reaction:

- 1st week: 1/100th the total dose

- 2nd week: 1/10th the total dose
- 3rd week: 1/3rd the total dose
- 4th week: total dose.

Should kidney dysfunction or other severe manifestations develop, discontinue D-penicillamine and give 40 to 80 mg of prednisone/day.

In Wilson's disease, alternative treatments are trientine and zinc; desensitization can be performed as follows:

- day 1: prednisone 30 mg
- day 3-4-5: D-penicillamine 125 mg
- day 6-7-8: D-penicillamine 250 mg
- day 9-10-11: D-penicillamine 375 mg
- day 12-13-14: D-penicillamine 500 mg
- day 15-16-17: D-penicillamine 750 mg
- day 18 and subsequently: D-penicillamine 1 g.

References

Bienaimé F, Clerbaux G, Plaisier E, et al. D-Penicillamine-induced ANCA-associated crescentic glomerulonephritis in Wilson disease. *Am J Kidney Dis* 2007;50:821-5.

Rath N, Bhardwaj A, Kar HK, et al. Penicillamine induced pseudoxanthoma elasticum with elastosis perforans serpiginosa. *Indian J Dermatol Venereol Leprol* 2005;71:182-5.

ten Holder SM, Joy MS, Falk RJ. Cutaneous and systemic manifestations of drug-induced vasculitis. *Ann Pharmacother* 2002;36:130-47.

Shannon MW, Townsend MK. Adverse effects of reduced-dose d-penicillamine in children with mild-to-moderate lead poisoning. *Ann Pharmacother* 2000;34:15-8.

Lin HC, Hwang KC, Lee HJ, et al. Penicillamine induced lupus-like syndrome: a case report. *J Microbiol Immunol Infect* 2000;33:202-4.

Bialy-Golan S, Brenner S. Penicillamine-induced bullous dermatoses. *J Am Acad Dermatol* 1996;35:732-42.

de Moor A, Van Hecke E, Kestelyn P. Contact allergy to penicillamine in eye drops. *Contact Dermatitis* 1993;29:155-6.

Felbamate

Broad spectrum activity against partial and generalized seizures of various types.

■ Incidence

Rash < 1%.

Aplastic anemia: 27 to 209/106

■ Risk factors

Leucopenia (aplastic anemia).

Immune disease (aplastic anemia).

Female sex (aplastic anemia, hepatic failure).

■ Clinical manifestations

• **General:** anaphylactic shock.

• **Cutaneous:** pruritus, facial edema, rash, Stevens-Johnson syndrome, toxic epidermal necrolysis.

• **Others:** Aplastic anemia (13 fatalities → 1999), hepatic failure.

■ Diagnostic methods

None.

■ Mechanisms

Role of a reactive metabolite: atropaldehyde.

Genetic factors (HLA).

■ Management

Avoidance.

References

Arif H, Buchsbaum R, Weintraub D, et al. Comparison and predictors of rash associated with 15 antiepileptics drugs. *Neurology* 2007;68:1701-9.

Wong IC, Lhatoo SD. Adverse reactions to new anticonvulsant drugs. *Drug Saf* 2000;23:35-56.

Pellock JM. Felbamate. *Epilepsia* 1999;40:S57-62.

Travaglini MT, Morrison RC, Ackerman BH, et al. Toxic epidermal necrolysis after initiation of felbamate therapy. *Pharmacotherapy* 1995;15:260-4.

Gabapentin

Gabapentin has been successfully used as an alternative in patients with hypersensitivity to older antiepileptics and is considered to be a relatively safe drug.

■ Incidence

Rash: 0.3%.

■ Clinical manifestations

Anticonvulsant hypersensitivity syndrome (very rare).

Maculopapular rash (developing > 3 weeks after starting the drug), fever > 38°C, prolonged clinical syndrome after discontinuation of the drug, liver abnormalities (ALT < 100 U/l), leukocyte abnormalities (leukocytosis > 11x10⁹/l or atypical lymphocytosis (> 5%) or eosinophilia (> 1.5x10⁹/l), lymphadenopathy, HHV-6 reactivation (increase in HHV-6 IgG titers detected in the 2nd to 3rd week after onset of symptoms), various forms of renal involvement: tubulointerstitial nephritis to granulomatous necrotizing angitis, cardiac manifestations.

• ***Other cutaneous manifestations:*** rash, pruritus, angioedema, Stevens-Johnson syndrome, peripheral edema, vasculitis (sometimes leucocytoclastic).

■ Diagnostic methods

None.

■ Mechanisms

Unknown

■ Management

Avoidance.

References

Goldman J, Duval-Modeste AB, Musette P, et al. Drug-induced hypersensitivity syndrome due to gabapentin (Article in French). *Ann Dermatol Venereol* 2008;135:230-2.

Sahin S, Comert A, Akin O, et al. Cutaneous drug eruptions by current antiepileptics: case reports and alternative treatment options. *Clin Neuropharmacol* 2008;31:93-6.

Arif H, Buchsbaum R, Weintraub D, et al. Comparison and predictors of rash associated with 15 antiepileptics drugs. *Neurology* 2007;68:1701-9.

Fletcher R, Butcher H, Raw J, et al. Gabapentin and hypersensitivity syndrome. *J Postgrad Med* 2007;53:276-7.

Ragucci MV, Cohen JM. Gabapentin-induced hypersensitivity syndrome. *Clin Neuropharmacol* 2001;24:103-5.

Lamotrigine

Lamotrigine is effective for a variety of seizure types, especially against absence seizures in co-therapy with valproate. It is a triazine which acts by stabilizing the neuronal membrane and preventing the release of excitatory neurotransmitters.

■ Incidence

Higher in children.

Rash: 6%.

Toxic epidermal necrolysis, Stevens-Johnson syndrome: 1/1,000.

■ Risk factors

Elderly black men.

Flu-like illness within the previous 6 weeks.

Female sex.

Concomitant use of sodium valproate (controversial).

■ Clinical manifestations

• *Anticonvulsant hypersensitivity syndrome (mortality 20%):*

Maculopapular rash (developing > 3 weeks after starting the drug), fever > 38°C (100% of cases), prolonged clinical syndrome after discontinuation of the causative drug, liver abnormalities (ALT < 100 U/l) (28 to 65% of cases), leukocyte abnormalities (leukocytosis > $11 \times 10^9/l$) (0 to 14% of cases), or atypical lymphocytosis (> 5%) or eosinophilia (> $1.5 \times 10^9/l$) (0 to 21% of cases), lymphadenopathy (10 to 28% of cases), HHV-6 reactivation (increase in HHV-6 IgG titers detected in the 2nd to 3rd week after onset of symptoms), various forms of renal involvement: tubulointerstitial nephritis to granulomatous necrotizing angitis, cardiac manifestations (14 to 27% of cases).

• *Cutaneous manifestations:* maculopapular rash (frequent), erythema multiforme, Stevens-Johnson syndrome, toxic epidermal necrolysis (increased risk when high starting doses and rapid increase of the doses, in particular when lamotrigine is associated to valproic acid; weaker association in a limited number of patients: HLA B 38 in European population); lupus erythematosus, fixed drug eruption (sometimes severe but rare), porphyria.

• *Others:* agranulocytosis.

■ Diagnostic methods

Skin tests

Patch tests: open application test 50% in pet (in case of fixed drug eruption). No standard for concentration and vehicle.

■ Mechanisms

The parent drug rather than a reactive metabolite causes skin rashes (non-covalent binding with metabolites).

Anticonvulsant hypersensitivity syndrome two main hypothesis:

1) Stimulation of T cells by the drug, leading to reactivation of herpes virus harbored in T cells.

2) Clinically unapparent reactivation of herpes virus occurs. The virus-stimulated T cells show substantial cross-reactivity with certain drugs; administration of the drugs leads to an expansion of these specific T cells which continues after cessation of the drug due to the persistence of the viral antigens.

I Management

Progressive re-introduction with low initial dose and slow titration schedule: 5 mg every day or every second day for 14 days increased by 5 mg every 14th day to 25 mg a day.

After achieving the daily dosage of 25 mg/day the up titration is completed following the current guidelines (success rate: 84%)

References

Mockenhaupt M, Viboud C, Dunant A, et al. Stevens-Johnson syndrome and toxic epidermal necrolysis: assessment of medication risks with emphasis on recently marketed drugs. *J Invest Dermatol* 2008;128:35-44.

Lonjou C, Borot N, Sekula P, et al. A European study of HLA-B in Stevens-Johnson syndrome and toxic epidermal necrolysis related to five high-risk drugs. *Pharmacogenet Genomics* 2008;18:99-107.

Shiohara T, Takahashi R, Kano Y. Drug-induced hypersensitivity syndrome and viral reactivation. In: Pichler WJ, ed. *Drug Hypersensitivity*. Basel: Karger, 2007:251-66.

Lu W, Uetrecht JP. Possible bioactivation pathways of lamotrigine. *Drug Metab Dispos* 2007;35:1050-6.

Hsiao CJ, Lee JYY, Wong TW, et al. Extensive fixed drug eruption due to lamotrigine. *Br J Dermatol* 2001;144:1289-91.

Sarzi-Puttini P, Panni B, Cazzola M, et al. Lamotrigine-induced lupus. *Lupus* 2000;9:555-7.

Leflunomide

A new immunomodulatory drug inhibiting pyrimidine synthetase, used for the treatment of rheumatoid and psoriatic arthritis.

I Incidence

Hypersensitivity pneumonitis: 1.1% (30% deaths).

I Clinical manifestations

- **General:** drug hypersensitivity syndrome (fever and multiple organ involvement), anaphylactoid reactions (mild frequent, severe rare).

- **Cutaneous:** maculopapular rash, purpura, pruritus, eczematoid eruption, urticaria (rare), lupus erythematosus (induction, exacerbation, frequent subacute cutaneous lupus erythematosus, sometimes bullous), erythema multiforme, toxic epidermal necrolysis, Stevens-Johnson syndrome, lichenoid eruption (sometimes with photodistribution), vasculitis, skin ulceration (sometimes severe), xerosis, stomatitis, alopecia.

- **Respiratory:** hypersensitivity pneumonitis.

I Diagnostic methods

Skin tests

Patch tests: 30% in pet (in a case of DRESS, positive after 48 hours). The tests must be performed with caution in this severe drug adverse effect.

I Mechanisms

Anticonvulsant hypersensitivity syndrome 2 main hypotheses:

- 1) Stimulation of T cells by the drug leading to reactivation of herpes virus harbored in T cells.
- 2) Clinically unapparent reactivation of herpes virus occurs. The virus-stimulated T cells show a substantial cross-reactivity with certain drugs; administration of the drug leads to an expansion of these specific T cells which continues after cessation of the drug due to the persistence of the viral antigens.

I Management

Avoidance.

References

Suess A, Sticherling M. Leflunomide in subacute cutaneous lupus erythematosus—two sides of a coin. *Int J Dermatol* 2008;47:83-6.

Martin N, Innes JA, Lambert CM, et al. Hypersensitivity pneumonitis associated with leflunomide therapy. *J Rheumatol* 2007;34:1934-7.

Shastri V, Betkerur J, Kushalappa PA, et al. Severe cutaneous adverse drug reaction to leflunomide: a report of five cases. *Indian J Dermatol Venereol Leprol* 2006;72:286-9.

Teraki Y, Hitomi K, Sato Y, et al. Leflunomide-induced toxic epidermal necrolysis. *Int J Dermatol* 2006;45:1370-1.

Jacob A, Porstmann R, Rompel R. Skin ulceration after leflunomide treatment in two patients with rheumatoid arthritis. *J Dtsch Dermatol Ges* 2006;4:324-7.

Kamata Y, Nara H, Kamimura T, et al. Rheumatoid arthritis complicated with acute interstitial pneumonia induced by leflunomide as an adverse reaction. *Internal Medicine* 2004;43:1201-4.

Mac Donald J, Zhong T, Lazarescu A, et al. Vasculitis associated with the use of leflunomide. *J Rheumatol* 2004;31:2076-8.

Oxcarbazepine

Carbamazepine 10-ketoderivative approved for use as an antiepileptic agent (partial seizures with or without secondarily generalized seizures in adults and children). Risk of hyponatremia higher but risk of cutaneous lower than carbamazepine.

I Incidence

Angioedema: 9.8/10⁶ pediatric patients.

I Risk factors

Female sex, patients with learning disability have a lower risk.

I Clinical manifestations

- **General:** anticonvulsant syndrome (rare): cf carbamazepine for clinical manifestations.
- **Cutaneous:** angioedema: swelling of face, eyes, lips tongue, difficult swallowing of breathing localized penile oedema, rash.
- **Others:** interstitial nephritis.

I Diagnostic methods

None.

I Mechanisms

Possible T-cell mediated hypersensitivity.

I Management

Avoidance.

Desensitization: one case beginning with 0.1 mg daily doubled every two days → day 63 1200 mg/day.

Cross-reactivity with carbamazepine: 25%.

References

Knudsen JF, Flowers CM, Kortepeter C, et al, *Clinical profile of oxcarbazepine-related angioneurotic edema : case report and review*, *Pediatr. Neurol.* 2007;37(2):134-7

Arif H, Buchsbaum R, Weintraub D, et al, *Comparison and predictors of rash associated with 15 antiepileptic drugs*, *Neurology.* 2007;68(20):1701-9

Alvestad S, Lydersen S, Brodtkorb E, *Rash from antiepileptic drugs : influence by gender, age, and learning disability*, *Epilepsia.* 2007;48(7):1360-5

Pastor-Milan E, Rubert-Gomez MA, Vasquez-Gutierrez F, et al, *Oxcarbazepine induced interstitial nephritis in a patient with drug hypersensitivity syndrome, (Article in Spanish)*, *Rev. Neurol.* 2003;37(10):948-50

Beran RG, *Cross-reactive skin eruption with both carbamazepine and oxcarbazepine*, *Epilepsia.* 1993;34(1): 163-5

Watts D, Bird J, *Oxcarbazepine sensitivity treated by desensitisation*, *J. Neurol. Neurosurg. Psychiatry.* 1991;54(4):376

Phenobarbital

A widely used aromatic antiepileptic drug.

■ Incidence

Anticonvulsant syndrome: 1/1,000 to 1/10,000 exposures

■ Risk factors

Elderly black men.

Flu-like illness within the previous 6 weeks.

Rash with another aromatic antiepileptic drug.

■ Clinical manifestations

• **Anticonvulsant hypersensitivity syndrome (mortality 20%):**

Maculopapular rash developing > 3 weeks after starting the drug (80% to 100% of cases)

Fever > 38° C (80% to 100% of cases).

Prolonged clinical syndrome after discontinuation of the drug.

Liver abnormalities ALT > 100 u/l (75 to 80% of cases).

Leukocyte abnormalities:

Leukocytosis > $11 \times 10^9/l$ (0 to 12% of cases) or atypical lymphocytes (>5%) or Eosinophilia > $1.5 \times 10^9/l$ (75 to 100% of cases).

Lymphadenopathy (20 to 25% of cases).

HHV-6 reactivation (increase in HHV-6 IgG titers detected in the 2nd to 3rd week after start of symptoms).

Various forms of renal involvement: tubulointestinal nephritis to granulomatous necrotizing angiitis.

Cardiac manifestations are usually absent.

• **Cutaneous:**

Acute generalized exanthematous pustulosis, erythema multiforme, Stevens-Johnson syndrome, toxic epidermal necrolysis, fixed drug eruption.

■ Diagnostic methods

Skin tests

Patch tests: sometimes positive.

Lymphocyte transformation test: sometimes positive.

■ Mechanisms

Anticonvulsant hypersensitivity syndrome 2 main hypotheses:

- 1) Stimulation of T cells by the drug leading to reactivation of herpes virus harbored in T cells.
- 2) Clinically unapparent reactivation of herpes virus occurs. The virus-stimulated T cells show a substantial cross-reactivity with certain drugs; administration of the drug leads to an expansion of these

specific T cells which continues after cessation of the drug due to the persistence of the viral antigens. Aromatic anticonvulsants are metabolized to hydroxylated aromatic compounds such as arene oxide. If detoxification of this toxic metabolite is insufficient, the toxic metabolite may bind to cellular macromolecules causing cellular necrosis or a secondary immunological response.

T cells from the patients sensitized with anticonvulsant are activated in vivo and in vitro CD4+ and CD8+ infiltrate the affected skin.

I Management

Cross-reactivity among aromatic anticonvulsants (phenobarbital, phenytoin, carbamazepine) is high (40 to 80%).

Use valproic acid or clobazam to control epilepsy.

Treatment of hypersensitivity syndrome: steroids 1 to 1.5 mg/kg; intravenous immunoglobulins, plasma exchange.

Desensitization: one successful case in a patient with exanthematous eruption (1 mg → 200 mg).

References

Shiohara T, Takahashi R, Kano Y. Drug-induced hypersensitivity syndrome and viral reactivation. In: Pichler WJ, ed. *Drug Hypersensitivity*. Basel: Karger, 2007:251-66.

Romano A, Pettinato R, Andriolo M, et al. Hypersensitivity to aromatic anticonvulsants: in vivo and in vitro cross-reactivity studies. *Curr Pharm Des* 2006;12:3373-81.

Hashizume H, Takigawa M, Tokura Y. Characterization of drug-specific T cells in phenobarbital-induced eruption. *The Journal of Immunology* 2002;168: 5359-68.

Knowles SR, Shapiro LE, Shear NH. Anticonvulsant hypersensitivity syndrome: incidence, prevention and management. *Drug Saf* 1999;21:489-501.

Fröscher W, Kleinhaus D. Successful induction of tolerance in an epilepsy patient with phenobarbital allergy. *Nervenarzt* 1998;69:158-61.

Phenytoin

A widely used aromatic antiepileptic drug.

■ Incidence

Rash: 5-9%.

Hypersensitivity syndrome: 1/1,000 to 1/10,000.

Deaths reported.

■ Risk factors

Elderly black men.

Flu-like illness within the 6 previous weeks.

A CYP 2C9*3 could play a role in some patients with phenytoin-induced cutaneous reactions.

Rash with another aromatic antiepileptic drug.

■ Clinical manifestations

• *Anticonvulsant hypersensitivity syndrome (mortality 20%):*

Maculopapular rash (developing > 3 weeks after starting the drug) (97 to 100% of cases), fever > 38°C (43 to 97% of cases), prolonged clinical syndrome after discontinuation of the drug, liver abnormalities (ALT > 100 U/l) (57 to 73% of cases), leukocyte abnormalities (leukocytosis > $11 \times 10^9/l$) (0 to 18% of cases), atypical lymphocytes (> 5%), eosinophilia > $1.5 \times 10^9/l$ (58 to 100% of cases), lymphadenopathy (14 to 21% of cases), HHV-6 reactivation (increase in HHV-6 IgG titers detected in the 2nd and 3rd week after onset of symptoms). Various forms of renal involvement: tubulointerstitial nephritis to granulomatous necrotizing angeliitis. Cardiac manifestation: 0 to 18%

• *Cutaneous:* rash (frequent) as maculopapular exanthem, pruritus, urticaria (rare), exfoliative dermatitis (generalized), fixed drug eruption, erythema multiforme, Stevens-Johnson syndrome, toxic epidermal necrolysis (sometimes with synergistic effect between phenytoin and radiotherapy), lupus erythematosus, vasculitis, purple glove syndrome (with intravenous phenytoin and more rarely with oral administration): pain, edema, discoloration at the injection site of extremities; pseudolymphoma or rarely lymphoma and mycosis fungoides-like lesions, pigmentation (face and neck), porphyria, IgA bullous dermatosis (rare), gingival hypertrophy (frequent), alopecia, hirsutism, facies modification, fetal hydantoin syndrome (prenatal exposure).

■ Diagnostic methods

Skin tests

Patch tests: hydantoin 10% in pet.

ECP blood levels may represent a sufficient parameter to monitor the development of anticonvulsant hypersensitivity syndrome.

Carboxy Fluorescein Succinimiry Ester (CFSE). Greater sensitivity than conventional lymphocyte transformation test.

I Mechanisms

Anticonvulsant hypersensitivity syndrome 2 main hypothesis:

- 1) Stimulation of T cells by the drug leading to reactivation of herpes virus harbored in T cells.
- 2) Clinically unapparent reactivation of herpes virus occur. The virus-stimulated T cells show a substantial cross-reactivity with certain drugs; administration of the drug leads to an expansion of these specific T cells which continues after cessation of the drug due to the persistence of the viral antigens.

Aromatic anticonvulsants are metabolized to hydroxylated aromatic compounds such as arene oxide. If detoxification of this toxic metabolite is insufficient, the toxic metabolite may bind to cellular macromolecules causing cellular necrosis or a secondary immunological response.

T cells from the patients sensitized with anticonvulsant are activated in vivo and in vitro CD4+ and CD8+ infiltrate the affected skin.

I Management

Consider possible cross-reactivity with tricyclic antidepressant agents.

Cross-reactivity among aromatic anticonvulsants (phenobarbital, phenytoin, carbamazepine) is high (40 to 80%).

Gabapentin has been successfully used in patients with hypersensitivity syndrome to phenytoin.

Treatment of hypersensitivity syndrome: steroids 1 to 1.5 mg/kg, intravenous immunoglobulins, plasma exchange.

N-acetyl cysteine (liver injury).

References

- Sanchez-Morillas L, Laguna-Martinez JJ, Reano-Martos M, et al. A case of hypersensitivity syndrome due to phenytoin. *J Investig Allergol Clin Immunol* 2008;18:71-7.
- Shiohara T, Takahashi R, Kano Y. Drug-induced hypersensitivity syndrome and viral reactivation. In: Pichler WJ, ed. *Drug Hypersensitivity*. Basel: Karger, 2007:251-66.
- Petkov T, Pehlivanov G, Grozdev I, et al. Toxic epidermal necrolysis as a dermatological manifestation of drug hypersensitivity syndrome. *Eur J Dermatol* 2007;17:422-7.
- Arif H, Buchsbaum R, Weintraub D, et al. Comparison and predictors of rash associated with 15 antiepileptic drugs. *Neurology* 2007;68:1701-9.
- Tsuge I, Okumura A, Kondo Y, et al. Allergen-specific T-cell response in patients with phenytoin hypersensitivity; simultaneous analysis of proliferation and cytokine production by carboxyfluorescein succinimidyl ester (CFSE) dilution assay. *Allergol Int* 2007;56:149-55.
- Chosky R, Openshaw J, Mehta NN, et al. Purple glove syndrome following intravenous phenytoin administration. *Vasc Med* 2007;12:29-31.
- Seitz CS, Pfeuffer P, Raith P, et al. Anticonvulsant hypersensitivity syndrome: cross-reactivity with tricyclic antidepressant agents. *Ann Allergy Asthma Immunol* 2006;97:698-702.

Lee AY, Kim MJ, Chey WY, et al. Genetic polymorphism of cytochrome P450 2C9 in diphenylhydantoin-induced cutaneous adverse drug reactions. *Eur J Clin Pharmacol* 2004;60:155-9.

Scheinfeld N. Impact of phenytoin therapy on the skin and skin disease. *Expert Opin Drug Saf* 2004;3:655-65.

Galindo PA, Borja J, Gomez E, et al. Anticonvulsant drug hypersensitivity. *J Investig Allergol Clin Immunol* 2002;12:299-304.

Serotonin selective reuptake inhibitors

Widely used antidepressants. Citalopram, Fluoxetine, Fluvoxamine, Paroxetine, Setraline.

■ Incidence

Low.

■ Clinical manifestations

- **Cutaneous:** pruritus, rash (maculopapular), urticaria, angioedema, flushing, Stevens-Johnson syndrome, toxic epidermal necrolysis, urticarial vasculitis, acute generalized erythematous pustulosis (setraline), discoid lupus erythematosus like eruption (setraline), vasculitis, ecchymosis, purpura and cutaneous-mucosal bleeding, photosensitivity, pseudolymphoma, serum-sickness like reaction (fluoxetine), sudation, xerostomia.
- **Respiratory:** one case of fatal asthma (overdose), hypersensitivity pneumonitis.
- **Others:** hepatitis.

■ Diagnostic methods

Skin tests

Patch tests: 1% and 3% in pet (paroxetine, setraline, citalopram, fluoxetine, fluvoxetine).

■ Mechanisms

Delayed hypersensitivity.

Pruritus: serotonin can stimulate cutaneous C fibres that transmit itch.

■ Management

Avoidance.

Cross-reactivity among serotonin selective reuptake inhibitors exists in spite of their different chemical structure.

References

- Ahmed R, Eagleton C. Toxic epidermal necrolysis after paroxetine treatment. *N Z Med J* 2008;121:86-9.
- Jonsson GW, Moosa MY, Jeenah FY. Toxic epidermal necrolysis and fluoxetine: a case report. *J Clin Psychopharmacol* 2008;28:93-5.
- Welsh JP, Cusak CA, Ko C. Urticarial vasculitis secondary to paroxetine. *J Drugs Dermatol* 2006;5:1012-4.
- Mera MT, Perez BV, Fernandez RO, et al. Hypersensitivity to paroxetine. *Allergol Immunopathol* 2006;34:125-6.
- Richard MA, Fiszenson F, Jreissati M, et al. Cutaneous adverse effects during selective serotonin reuptake inhibitors therapy: 2 cases (Article in French). *Ann Dermatol Venereol* 2001;128:759-61.

Tetrazepam

A benzodiazepine widely used as a muscle relaxant.

■ Incidence

2/4,767 recipients of benzodiazepine drugs.

■ Clinical manifestations

- **Cutaneous:** pruritus, urticaria, angioedema, acute generalized exanthematous pustulosis, maculopapular rash, erythematous rash, urticarial eruption, vesicular eruption, purpuric and maculopapular eruption (with a biopsy showing leucocytoclastic vasculitis), DRESS syndrome, erythema multiforme, Stevens-Johnson syndrome, toxic epidermal necrolysis, photodermatitis, contact dermatitis (occupational airborne dermatitis).

- **Respiratory:** tightness of the chest.

■ Diagnostic methods

Skin tests

Patch tests: 30% in pet (commercialized form) and 10% in pet (tetrazepam).

Delayed positive patch test on day 10 in acute generalized exanthematous pustulosis and with dilutions 1% and 5% in pet and aq.

Photopatch tests (in case of photosensitivity).

Oral drug challenge.

Lymphocyte transformation test: positive in some cases of AGEF.

■ Mechanisms

Positive patch tests with tetrazepam and positive lymphocyte transformation tests suggest that tetrazepam-specific memory T cells may be responsible for a T cell-mediated cutaneous reaction.

Local production of IL8 in the skin is a key factor for development of AGEF.

The only structural difference between diazepam and tetrazepam is the presence of a 5-phenyl ring in diazepam and 1-cyclohexen-1-yl in tetrazepam, which could explain sensitization.

■ Management

Cross-reactivity among diazepines is weak.

Patch tests with other benzodiazepines are useful but tolerance must be confirmed by oral challenge.

References

- Thomas E, Bellon T, Barranco P, et al. Acute generalized exanthematous pustulosis due to tetrazepam. *J Investig Allergol Clin Immunol* 2008;18:119-22.
- Bachmeyer C, Assier H, Roujeau JC, et al. Probable drug rash with eosinophilia and systemic symptoms syndrome related to tetrazepam. *J Eur Acad Dermatol Venereol* 2008;22:887-9.
- Cabrerizo Ballesteros S, Mendez Alcalde JD, Sanchez Alonzso A. Erythema multiforme to tetrazepam. *J Investig Allergol Clin Immunol* 2007;17:202-6.
- Ferran M, Gimenez-Arnau A, Luque S, et al. Occupational airborne contact dermatitis from sporadic exposure to tetrazepam during machine maintenance. *Contact Dermatitis* 2005;52:173-4.
- Pirker C, Mistic A, Brinkmeier T, et al. Tetrazepam drug sensitivity-usefulness of the patch test. *Contact Dermatitis* 2002;47:135-8.
- Ortega NR, Barranco P, Lopez-Serrano C, et al. Delayed cell-mediated hypersensitivity to tetrazepam. *Contact Dermatitis* 1996;34:139.

Valproate

A non-aromatic anticonvulsant used worldwide.

■ Incidence

Rash: 0.7%.

■ Clinical manifestations

- **Anticonvulsant hypersensitivity syndrome (very rare, only a few cases reported):**

Maculopapular rash (developing > 3 weeks after starting the drug), fever > 38°C, prolonged clinical syndrome after discontinuation of the drug, liver abnormalities (ALT > 100 U/l), leukocyte abnormalities (leukocytosis > 11x10⁹/l or atypical lymphocytosis (> 5%) or eosinophilia (> 1.5x10⁹/l), lymphadenopathy, HHV-6 reactivation (increase in HHV-6 IgG titers detected in the 2nd to 3rd weeks after start of symptoms), various forms of renal involvement: tubulointerstitial nephritis to granulomatous necrotizing angiitis, cardiac manifestations.

- **Cutaneous:** rash, psoriasiform eruption, erythema multiforme, toxic epidermal necrolysis, Stevens-Johnson syndrome (increased risk when associated to lamotrigine), Rowell syndrome (association with radiotherapy), pseudo lymphoma, porphyria.

- **Others:** eosinophilic pleural effusion (6 cases), hepatitis.

■ Diagnostic methods

Skin tests

Patch tests: pure, 30% in distilled water (not standardized for concentration and vehicle).

■ Mechanisms

Defective detoxification of reactive cytotoxic metabolites (liver toxicity).

■ Management

Avoidance.

Carnitine (cofactor in the mitochondrial betaoxidation of fatty acids) is the recommended treatment in valproate associated liver injury.

Treatment of hypersensitivity syndrome: steroids 1 to 1.5 mg/kg; intravenous immunoglobulins, plasma exchange.

References

Bullington W, Sahn SA, Judson MA. Valproic acid-induced eosinophilic pleural effusion: a case report and review of the literature. *Am J Med Sci* 2007;333:290-2.

Roepke S, Treudeler R, Anghelescu I, et al. Valproic acid and hypersensitivity syndrome. *Am J Psychiatry* 2004;161:579.

Arevalo-Lorido JC, Carretero-Gomez J, Bureo-Dacal JC, et al. Antiepileptic drug hypersensitivity syndrome in a patient treated with valproate. *Br J Clin Pharmacol* 2003;55:415-6.

Huang YL, Hong HS, Wang ZW, et al. Fatal sodium valproate-induced hypersensitivity syndrome with lichenoid dermatitis and fulminant hepatitis. *J Am Acad Dermatol* 2003;49:316-9.

Cogrel O, Beylot-Barry M, Vergier B, et al. Sodium valproate-induced cutaneous pseudolymphoma followed by recurrence with carbamazepine. *Br J Dermatol* 2001;144:1235-8.

Picart N, Périole B, Mazereeuw J, et al. Drug hypersensitivity syndrome to valproic acid (Article in French). *Presse Med* 2000;29:648-50.

XV

MISCELLANEOUS



Acetylcysteine

Intravenous acetylcysteine is the treatment of choice for acetaminophen poisoning and more recently for anticonvulsant-induced hypersensitivity syndrome. N-acetylcysteine is a known precursor of glutathione involved in detoxification from several drugs.

■ Incidence

3.4% to 8.5% of courses of intravenous acetylcysteine (up to 48.4% in one study).
Deaths reported.

■ Risk factors

Plasma paracetamol concentrations below the treatment lines.
Delayed management of paracetamol poisoning.
Asthma.
Intravenous use (no report following oral administration).

■ Clinical manifestations

(occurring 20 minutes after starting of treatment)

- **General:** anaphylactic shock, fever (inhalation therapy).
- **Cutaneous:** rash, pruritus, urticaria, angioedema, contact dermatitis (eye drops).
- **Respiratory:** bronchospasm (sometimes in asthmatic patients by intravenous or inhalation route).

■ Diagnostic methods

None.

■ Mechanisms

Hypotension seems to result from a vasodilator action on resistance vasculature (dose-dependent).

Direct non immunological histamine release.

■ Management

Give the loading dose of N-acetylcysteine over 60 minutes reduce the incidence of adverse reactions.

Non life-threatening anaphylactoid reactions to intravenous N-acetylcysteine are easily treated: flushing requires no treatment; urticaria should be treated with antihistamines; angioedema and respiratory symptoms require antihistamines and symptomatic therapy.

In cases of angioedema and respiratory symptoms, N-acetylcysteine should be stopped but can be started again one hour after administration of antihistamines.

Oral methionine and mercaptamine may be used as alternative antidotes.

References

- Pizon AF, Lovecchio F. Adverse reactions from use of intravenous N-acetylcysteine. *J Emerg Med* 2006;31:434-5.
- Lynch RM, Robertson R. Anaphylactoid reactions to intravenous N-acetylcysteine: a prospective case controlled study. *Accid Emerg Nurs* 2004;12:10-15.
- Appelboam AV, Dargan PI, Knighton J. Fatal anaphylactoid reaction to N-acetylcysteine: caution in patients with asthma. *Emerg Med J* 2002;19:594-5.
- Davison SC, Wakelin SH. Allergic contact dermatitis from N-acetylcysteine eye drops. *Contact Dermatitis* 2002;47:238.
- Schmidt LE, Dalhoff K. Risk factors in the development of adverse reactions to N-acetylcysteine in patients with paracetamol poisoning. *Br J Clin Pharmacol* 2001;51:87-91.
- Bailey B, Mc Guigan MA. Management of anaphylactoid reactions to intravenous N-acetylcysteine. *Ann Emerg Med* 1998;31:710-5.

Antihistamines

The drugs most frequently used in the treatment of allergic diseases. Efficacy, tolerance and safety have been widely established.

ALKYLAMINES (dexchlorpheniramine); ETHANOLAMINES (diphenhydriene); ETHYLENEDIAMINES (mepiramine); PIPERAZINES (hydroxyzine, cetirizine, levocetirizine); PIPERIDINES (AZATADINE: ketotifen, loratadine, desloratadine; TERFENADINE: fexofenadine, ebastine, PIPERIDINE-BENZIDIMAZOLE: mizolastine, PHTALAZINONE: azelastine; ALKYL-PIPERIDINE: rupatadine). OTHERS: levocabastine.

■ Incidence

Very rare.

■ Clinical manifestations

- **General:** anaphylactic shock (mizolastine, diphenhydramine).
- **Cutaneous:** maculopapular rash, morbilliform eruption, urticaria, acute generalized exanthematous pustulosis, fixed drug eruption, systemic contact dermatitis, erythema multiforme.
- **Others:** acute hepatitis, cholestasis, neutropenia.

■ Diagnostic methods

Skin tests

Prick tests: sometimes positive (mizolastine, loratadine).

Intradermal tests: sometimes positive (cetirizine, diphenhydramine).

Patch tests: cetirizine powder 20% in petrolatum and water (on residual lesion in fixed drug reaction); cetirizine: 2.5%, 5%, 10% in petrolatum, as is (in rash), hydroxyzine hydrochloride: 1% in petrolatum, loratadine: 10% in petrolatum, desloratadine: 10% in petrolatum (false positive); 1% in petrolatum (more specific).

No specific serum IgE found.

Oral challenge tests.

■ Mechanisms

IgE-mediated hypersensitivity in some cases.

■ Management

Avoidance.

Cross-reactivity between hydroxyzine, cetirizine, levocetirizine and ethylenediamine has been reported rarely.

In the case of mizolastine allergy, exclude cross-reactivity with other benzimidazole derivatives (antihelmintics, antiemetics, neuroleptics and proton pump inhibitors)

References

- Barbaud A, Bursztejn AC, Schmutz JL, et al. Patch tests with desloratadine at 10% induce false positive results: tests at 1%. *J Eur Acad Dermatol Venereol* 2008;22:1504-5.
- Cravo M, Gonçalves M, Figueiredo A. Fixed drug eruption to cetirizine with positive lesional patch tests to the three piperazine derivatives. *Int J Dermatol* 2007;46:760-2.
- Tsai YS, Tu ME, Wu YH, et al. Hydroxyzine-induced acute generalized exanthematous pustulosis. *Br J Dermatol* 2007;157:1296-7.
- Gonzalez de Olano D, Roan Roan J, de la Hoz Caballer B, et al. Urticaria induced by antihistamines. *J Investig Allergol Clin Immunol* 2006;16:144-6.
- Gonzalo-Garijo MA, Jimenez-Ferrera G, Bobadilla-Gonzalez P, et al. Hypersensitivity reaction to mizolastine: study of cross reactions. *J Investig Allergol Clin Immunol* 2006;16:391-3.
- Weidenger S, Mempel M, Ollert M, et al. Anaphylaxis to mizolastine. *J Allergy Clin Immunol* 2004;114:979-81.
- Lew BL, Haw CR, Lee MH. Cutaneous drug eruption from cetirizine and hydroxyzine. *J Am Acad Dermatol* 2004;50:953-6.
- Assouere MN, Mazereeuw-Hautier J, Bonafe JL. Cutaneous drug eruption with two antihistaminic drugs of a same chemical family: cetirizine and hydroxyzine. *Ann Dermatol Venereol* 2002;129:1295-8.

Deferoxamine

Deferoxamine is produced by a type of actinomycetes. It reacts with trivalent iron ions and forms the hydrosoluble complex ferrioxamine B, a specific iron chelating agent used in the treatment of hemochromatosis and acute iron poisoning.

■ Incidence

High.

■ Clinical manifestations

- **General:** anaphylactic shock.
- **Cutaneous:** frequent local reactions (erythema, itching, pain, inflammation, ulcerations, burn, localized edema), sometimes associated to a systemic reaction, pruritus, urticaria, rash (less frequent), angioedema (exceptional).
- **Respiratory:** bronchospasm, hypersensitivity pneumonitis, laryngospasm.

■ Diagnostic methods

Skin tests: false positives.

No IgE antibodies, except in lung biopsies.

■ Mechanisms

Direct non-immunological activation of dermal mast cells (subcutaneous route).

■ Management

Numerous desensitization protocols for use in adults and children have been published; by the intravenous or subcutaneous route.

For example in adults:

- Starting with a dose of 0.015 mg in 50 ml for 30 minutes, gradually increase (6 hours) to 1 500 mg in 50 ml for 30 minutes.
- Then administer 1.5 g per day by continuous infusion for 4 days.
- Then 1.5 g per 12 hours for 2 weeks.
- Finally, 1.5 g every 2 days.

High dose intravenous deferoxamine delivery is highly effective, but can lead to severe hypersensitivity pneumonitis.

Other iron chelators (oral deferiprone) are under clinical evaluation.

References

Somech R, Seaban-Adel K, Atkinson A, et al. Evaluation and management of pediatric patients with anaphylactoid reactions to deferoxamine mesylate. *Ann Allergy Asthma Immunol* 2007;99:575-6.

Gülen F, Demir E, Tanaç R, et al. Successful desensitization of one case with desferrioxamine hypersensitivity. *Minerva Pediatr* 2006;58:571-4.

La Rosa M, Romeo M.A, Di Gregorio F, et al. Desensitization treatment for anaphylactoid reactions to desferrioxamine in a pediatric patient with thalassemia. *J Allergy Clin Immunol* 1996;97:127-8.

Lombardo T, Ferro G, Frontini V, et al. High dose intravenous desferrioxamine (DFO) delivery in four thalassemic patients allergic to subcutaneous DFO administration. *Am J Hematol* 1996;51:90-2.

Shalit M, Tedeschi A, Miadonna A, et al. Desferal (desferrioxamine)-a novel activator of connective tissue-type mast cells. *J Allergy Clin Immunol* 1991;87:854-60.

Factors VIII/IX

Haemophilia is an X-linked recessive coagulopathy due to a mutation in the factor VIII or IX gene.

■ Incidence

Rashes: 0.1 to 0.75% (factor VIII).

■ Risk factors

Complete deletion of the factor IX gene or major derangements (inhibitory antibodies).

■ Clinical manifestations

(occurring within the first 10-20 treatment courses)

- **General:** anaphylactic shock (in haemophilia B this has been related to the development of an inhibitor).
- **Cutaneous:** pruritus, flushing, erythematous rash, urticaria.
- **Others:** presence of inhibitory antibodies (haemophilia A: 15-30%, haemophilia B: 1.5-3%).

■ Diagnostic methods

Specific serum IgE (Western Blot) to rF VIII in a few cases.

■ Mechanisms

The reasons for anaphylaxis at the time of inhibitor development in haemophilia B are:

1/ Smaller molecular size of factor IX compared with factor VIII (mw 55,000 leads to better diffusion in extravascular spaces).

2/ The normal plasma factor IX concentration is much higher compared with factor VIII (5 µg/ml vs 0.1 µg/ml), so that haemophilia B patients are exposed to higher concentrations of exogenous protein with a standard dose of 40/80 U/kg factor IX. The routine exposure of haemophilia B patients to such large amounts of exogenous protein without any endogenous factor IX antigen may contribute to the development of hypersensitivity.

3/ Absence of tolerance.

■ Management

Use recombinant factor VIIa for bleeding episodes.

Immune tolerance: daily administration of 25-200 U/kg/day successful in 78% of cases; greater in patients with a history of inhibitor titres less than 100 Bu and in patients with titres < 10 Bu at initiation of treatment.

Rituximab 375 mg/m² + desensitization.

References

- Alexander S, Hopewell S, Hunter S, et al. Rituximab and desensitization for a patient with severe factor IX deficiency, inhibitors, and history of anaphylaxis. *J Pediatr Hematol Oncol* 2008;30:93-5.
- Kadar JG, Schuster J, Hunzelmann N. IgE-mediated anaphylactic reaction to purified and recombinant factor VIII in a patient with severe haemophilia A. *Haemophilia* 2007;13:104-5.
- Damiano ML, Hutter JJ Jr. Immune tolerance for haemophilia patients with inhibitors: analysis of the western United States experience. The Tri-Régional Nursing Group. *Haemophilia* 2000;6:526-32.
- Thorland EC, Drost JB, Lusher JM, et al. Anaphylactic response to factor IX replacement therapy in haemophilia B patients: complete gene deletions confer the highest risk. *Haemophilia* 1999;5:101-5.
- Warrier I, Lusher JM. Development of anaphylactic shock in haemophilia B patients with inhibitors. *Blood Coagul Fibrinolysis* 1998;9(suppl1):S125-8.
- Dioun AF, Ewenstein BM, Geha RS, et al. IgE-mediated allergy and desensitization to factor IX in hemophilia B. *J Allergy Clin Immunol* 1998;102:113-7.

INDEX

5- HT3	P. 175
5- fluorouracil	P. 171
Acetaminophen	P. 44
Acetylcysteine	P. 436
Adalimumab	P. 380
Alefacept	P. 381
Alemtuzumab	P. 382
Alfentanil, Fentanyl, Remifentanyl, Sufentanyl	P. 8
Allopurinol	P. 408
Alteplase	P. 215
Aminoglutethimide	P. 140
Amiodarone	P. 216
Anakinra	P. 383
Angiotensin converting enzyme (ACE) inhibitors	P. 212
ANTIBIOTICS AND ANTIPARASITE DRUGS (25 substances)	P. 58
- Aminoglycosides	P. 58
- Bacitracin	P. 61
- Chloramphenicol	P. 63
- Chloroquine and Hydroxychloroquine	P. 65
- Clindamycin	P. 67
- Dapsone	P. 69
- Ethambutol	P. 71
- Isoniazid	P. 73
- Macrolides	P. 75
- Penicillin and other beta-lactams	P. 77
- Pentamidine	P. 83
- Praziquantel	P. 85
- Pyrazinamide	P. 86
- Quinine	P. 88
- Quinolones	P. 90
- Rifampicin	P. 93
- Rifamycin SV	P. 95
- Sodium fusidate	P. 99
- Streptomycin	P. 100
- Sulfamethoxazole-trimethoprim (SMX-TMP)	P. 96
- Sulphadiazine-Sulfadoxine	P. 102
- Synergistin	P. 104
- Telithromycin	P. 106
- Tetracycline group	P. 107
- Thiamphenicol	P. 109
- Vancomycin and Teicoplanin	P. 110
Antihistamines	P. 438
Antitetanus toxoid serum	P. 334
Antithymocyte globulin	P. 384
Antivenoms	P. 335
ANTIVIRAL AND ANTIFUNGAL DRUGS (11 substances)	p. 113
- Amphotericin B	P. 113

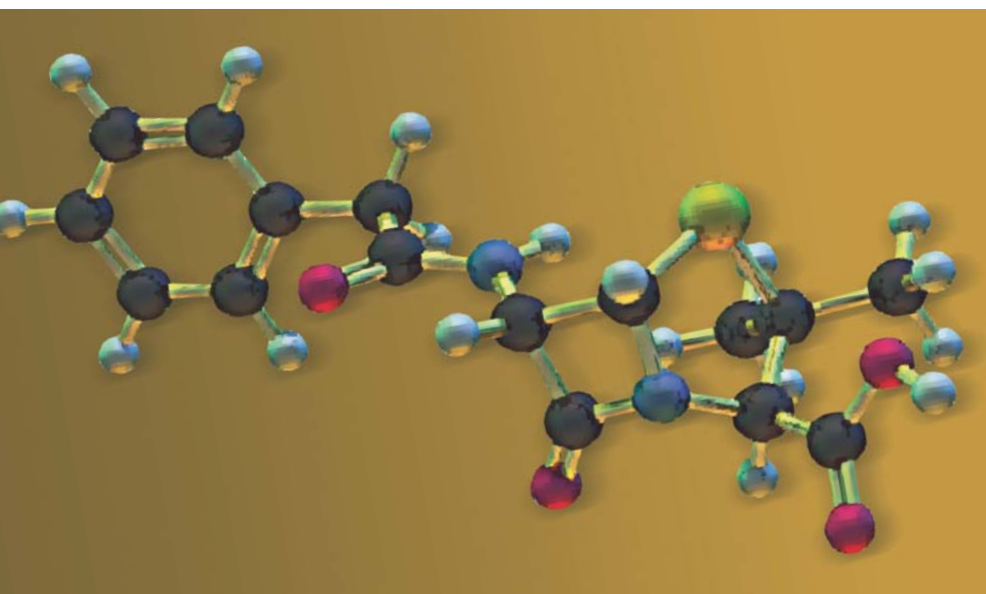
- Fluconazole	P. 118
- Fusion inhibitor (Enfuvirtide)	P. 119
- Integrase Inhibitor (Raltegravir)	P. 120
- Itraconazole	P. 121
- Ketoconazole	P. 122
- Metronidazole	P. 123
- Non - Nucleoside Reverse Transcriptase Inhibitors (NNRTIs)	P. 125
- Nucleoside reverse transcriptase inhibitors	P. 128
- Protease inhibitors	P. 132
- Terbinafine	P. 136
ANTI-HERPES VIRUS GROUP (5 substances)	P. 115
- Acyclovir and Valaciclovir	P. 115
- Cidofovir	P. 116
- Famciclovir	P. 117
- Foscarnet	P. 116
- Ganciclovir	P. 117
- Voriconazole	P. 137
Aprotinin	P. 312
Aspirin and non steroid anti-inflammatory drugs (NSAIDs)	P. 46
Atropine	P. 231
Azathioprine	P. 141
Basiliximab	P. 386
BCG Vaccine	P. 337
Beta-blockers	P. 233
Bevacizumab	P. 387
Bleomycin	P. 143
Bortezomib	P. 144
Bosentan	P. 236
Botulinal antitoxin	P. 339
Bovine serum albumin	P. 340
Bovine Thrombin	P. 237
Bupropion	P. 411
Busulfan	P. 145
Calcipotriol	P. 360
Calcitonin	P. 314
Calcium channel blockers	P. 238
Capecitabine	P. 146
Carbamazepine	P. 412
Carboplatin	P. 147
Carboxymethylcellulose	P. 262
Cetuximab	P. 388
Chlorambucil	P. 149
Chlorhexidine	P. 264
Chlorobutanol	P. 266
Cisplatin	P. 150
Cladribine	P. 152
Clonidine	P. 240
Clopidogrel	P. 218
Clozapine	P. 415
Codeine	P. 13
Corticosteroids	P. 316
Coumarin derivatives: warfarin, phenprocoumon, acenocoumarol	P. 219

Coxibs	P. 51
Cremophor EL	P. 267
Cyanocobalamin/ hydroxocobalamin (Vitamin B12)	P. 361
Cyclophosphamide	P. 153
Cyclosporine	P. 155
Cytarabine	P. 157
Dacarbazine	P. 159
Daunorubicin	P. 160
Deferoxamine	P. 440
Denileukin-Diftitox	P. 390
Dextrans	P. 15
Diazepam	P. 17
Docetaxel	P. 161
Doxorubicin	P. 163
D-penicillamine	P. 416
Droperidol	P. 18
Efalizumab	P. 391
Epirubicin	P. 165
Epoetin	P. 166
Equine rabies immunoglobulins	P. 342
Erlotinib/Gefitinib	P. 392
Etanercept	P. 394
Ethylene oxide	P. 269
Ethylenediamine	P. 271
Etomidate	P. 19
Etoposide	P. 168
Factors VIII/IX	P. 241
Felbamate	P. 418
Fibrates	P. 241
Fludarabine	P. 170
Fluidione	P. 220
Fluorescein	P. 296
Folic acid/ Folinic acid	P. 363
Formaldehyde	P. 273
Furosemide	P. 242
Gabapentin	P. 419
Gelatins	P. 20
Gemcitabine	P. 173
Glucagon	P. 319
Gonadotropin Releasing Hormone (GnRH analogues)	P. 320
Heparin	P. 221
Hepatitis B vaccine	P. 343
Hirudins	P. 227
Histamine H2 receptor antagonists	P. 372
Human serum albumin	P. 345
Hydralazine	P. 244
Hydrochlorothiazide	P. 245
Hydroxyethylstarch (HES)	P. 22
Hydroxyurea	P. 174
Ibritumomab-Tiuxetan	P. 395
Imatinib mesylate	P. 177

Imiquimod	P. 178
Indapamide	P. 247
Indigo carmine dye	P. 298
Indocyanine green	P. 299
Infliximab	P. 396
Influenza vaccine	P. 347
Insulin	P. 322
Interferon	P. 398
Interleukin 2	P. 400
Intravenous immunoglobulins	P. 349
Iodinated contrast media	P. 300
Iron	P. 292
Isosulfan blue	P. 304
Ketamine	P. 24
Lamotrigine	P. 420
L-asparaginase	P. 179
Latex	P. 25
LDL apheresis	P. 247
Leflunomide	P. 422
Lenalidomide	P. 181
Local anesthetics	P. 10
Mannitol	P. 28
Measles-Mumps-Rubella vaccine	P. 351
Mechlorethamine	P. 182
Melphalan	P. 184
Meperidine - pethidine	P. 29
Mercurochrome	P. 275
Mesna	P. 185
Methohexital	P. 30
Methotrexate	P. 186
Methylene blue	P. 305
Mexiletine	P. 248
Midazolam	P. 31
Mitomycin	P. 188
Mitoxantrone	P. 190
Morphine	P. 32
Muromonab	P. 401
Muscle relaxants	P. 34
Mycophenolate mofetil	P. 191
Nafamostat Mesilate	P. 294
Omalizumab	P. 402
Ortho-Phtalaldehyde	P. 276
Oxaliplatin	P. 192
Oxcarbazepine	P. 424
Paclitaxel	P. 194
Parabens	P. 277
Paramagnetic contrast agents	P. 306
Patent blue dye	P. 308
Pemetrexed	P. 196
Pentostatin	P. 197
Pentoxyfylline	P. 250

Phenobarbital	P. 425
Phenytoin	P. 427
Pneumococcal vaccine	P. 353
Poly acrylonitrile AN 69 membrane	P. 290
Polysorbate 80	P. 279
Povidone / Povidone iodine	P. 280
Prazosin	P. 251
Procarbazine	P. 198
Propafenone	P. 252
Propanidid	P. 37
Propofol	P. 38
Protamin	P. 253
Proton pump inhibitors	P. 374
Pseudoephedrine	P. 325
Pyrazoline drugs and pyrazolones	P. 55
Rabies vaccine	P. 354
Raltitrexed	P. 199
rhG- CSF and rhuGM- CSF	P. 200
Riboflavin	P. 364
Rituximab	P. 404
Sartans	P. 255
Serotonin selective reuptake inhibitors	P. 430
Sirolimus	P. 202
Sorafenib and Sunitinib	P. 203
Spirolactone	P. 257
Statins	P. 258
Streptokinase	P. 327
Sulfasalazine	P. 376
Sulfites (E 220 to 227)	P. 282
Tacrolimus	P. 204
Tartrazine (FD-C yellow n°5)	P. 284
Tegafur	P. 205
Temozolomide	P. 206
Teniposide	P. 207
Tetanus/Diphtheria toxoid	P. 356
Tetrazepam	P. 431
Thiamine (Vitamin B1)	P. 365
Thimerosal	P. 286
Thiopental	P. 40
Thiotepa	P. 208
Ticlopidine	P. 228
Topical corticosteroids	P. 329
Topical NSAIDs	P. 53
Topotecan	P. 209
Trastuzumab	P. 406
Valproate	P. 433
Vinblastine - Vincristine - Vindesine - Vinorelbine	P. 210
Vitamin B6	P. 367
Vitamin K	P. 368
Warfarin	P. 230
Yellow fever vaccine	P. 358

This latest edition of Drug Allergy, indisputable reference source for drug allergies, is a response to the constantly growing number of new molecules being added to the therapeutic armamentarium. It includes references to the latest publications available in the medical literature. Conceived and written by a team of French physicians led by Professor Daniel Vervloet, this book is an indispensable tool for both the medical practitioner and the medical laboratory.



ISBN 978-2-9520036-1-2
EAN 9782952003612



Phadia

Phadia AB. P O Box 6460, SE-751 37 Uppsala, Sweden
Tel +46 18 16 50 00. www.phadia.com

Head office Sweden +46 18 16 50 00 Austria +43 1 270 20 20 Belgium +32 2 749 55 15 Brazil +55 11 3345 5050 Denmark +45 7023 3306 Finland +358 9 8520 2560
France +33 1 61 37 34 30 Germany +49 761 47 8050 Great Britain/Ireland +44 1 908 769 110 Italy +39 02 641 634 11 Japan +81 3 5365 8332 Korea +82 2 2027 5400
Netherlands +31 30 602 3700 Norway +47 21 67 32 80 Portugal +351 21 423 5350 South Africa +27 11 793 5337 Spain +34 935 765 800 Sweden +46 18 16 50 00
Switzerland +41 43 343 4050 Taiwan +886 2 2516 0925 United States +1 800 346 4364 Other +46 18 16 56 16